

UNIVERSITÀ DEGLI STUDI DI MESSINA

Faculty of veterinary medicine

PhD Course in Veterinary and Animal Science

Class XXXIV



Comparison between several sexing methods in *Emys orbicularis* and other reptiles for reintroduction programs for conservation

S.S.D.: VET/09

Tutor: Prof. Filippo SPADOLA

PhD candidate: Emanuele LUBIAN Matricola 494398

Handwritten signature of Filippo Spadola in black ink.

Handwritten signature of Emanuele Lubian in black ink.

Co-tutor: Prof. Zdenek KNOTEK

Handwritten signature of Zdenek Knotek in black ink.

Summary

Chapter 1 - Introduction	2
1.1 European pond turtle	2
1.2 Sex identification and determination in European Pond Turtle	3
1.3 Environmental risk and biological competition with <i>Trachemys scripta</i>	5
1.4 Chelonian coelomic anatomy	7
1.5 Endoscopy	15
1.6 Chelonian anaesthesia and analgesia	20
Chapter 2 – Research studies	37
2.1 Cloacoscopic/cistoscopic sex determination	37
2.2 Control of invasive species	62
2.3 Anaesthetic protocols	86
Chapter 3 – Discussion	107
Chapter 4 – Further studies during PhD period	111

Chapter 1 – Introduction

Nowadays most of chelonians in the wild are endangered animals and threatened with extinction, which makes their conservation a worthwhile activity. A successful breeding conservation strategy will not only ensure their survival but also increase their population.

1.1 European pond turtle (*Emys orbicularis*)

The European pond turtle (*Emys orbicularis* -Linnaeus 1758-) and Sicilian pond turtle (*Emys trinacris* -Fritz et. Al 2005-) are the only species of the family Emydidae whose natural habitat is the “old world.” All other species of the family come from the American continent.¹

Numerous subspecies of *E. orbicularis* are currently recognised: *E. o. orbicularis*, *E. o. eiselti*, *E. o. galloitalica*, *E. o. hellenica*, *E. o. ingauna*, *E. o. occidentalis*, *E. o. persica*. Out of all of these, only three are native to Italy (i.e. *E. o. galloitalica*, *E. o. hellenica* and *E. o. ingauna*), and one of them is endemic (*E. o. ingauna*). There are no recognised subspecies in *E. trinacris*. Sardinian subspecies (*E. o. capolongoi* -Fritz, 1995-) is currently considered as *E. o. galloitalica* after the publication of genetic studies.² Genetic research does not seem to confirm the validity of the subspecies *E. o. ingauna*.^{3,4,5,1}

E. orbicularis is found in southern and central Europe, West Asia, and North Africa. In the early post-glacial period, the European pond turtle had a much wider distribution, being found as far north as southern Sweden. The natural distribution of *Emys* sp. includes several countries like: Albania, Algeria, Armenia, Austria, Azerbaijan, Belarus, Belgium (extirpated), Bosnia and Herzegovina, Bulgaria, Croatia, Czech Republic (extirpated and reintroduced), Denmark (extirpated and reintroduced), Estonia (extirpated), France (continental, and in Corsica after a prehistoric introduction), Georgia, Germany, Greece, Hungary, Iran, Italy (continental and Sardinia after a prehistoric introduction), Kazakhstan, Kosovo, Latvia, Lithuania, Luxembourg (extirpated), Macedonia, Moldova, Montenegro, Morocco, Netherlands (extirpated), Poland, Portugal, Romania, Russia, Serbia, Slovakia, Slovenia, Spain (continental), Switzerland (extirpated, reintroduced), Syria, Tunisia, Turkey, Turkmenistan, Ukraine. It has also been introduced in the Balearic Islands (Spain). In France, there are six large remaining populations of *E. orbicularis*, all declining, and it is the most endangered reptile in the country. In Switzerland, the European pond turtle was extinct at the beginning of the twentieth century and reintroduced in 2010.^{5,6}

Morphologic characteristics are different in different subspecies and are influenced by locality. The carapace is flattened and oval; the main colour is brown/green to black, and there are numerous yellow spots whose number and intensity are different for every specimen. In young specimens, there is a central keel which completely disappears with growth. Plastron is yellow, sometimes presenting several black streaks (especially in males). The background colour of the skin is black and there are several yellow spots (sometimes these are so many that they colour the skin with a uniform yellow pattern, especially on the ventral part). Considering the high chromatic difference between each specimen, the difference of the Italian species and subspecies is hard to explain considering the phenotypic differences alone. Compared to other Emydidae, European and Sicilian pond turtles have a longer tail, especially in males, where the tail can be longer than half of the entire body. Shell dimension varies from 8 to 18 cm, depending on locality; the males are smaller than the females. Fingers are connected by a membrane and there are five nails on each forelimb and four on each hindlimb.⁵

Usually, it lives in temporary or permanent swamps, lakes, rivers, canals, especially if there is a lot of aquatic vegetation and abundant reeds. It lives also in humid areas created by humans, such as, for example, drainage canals and disused quarries. Hibernation lasts from October to March, but it depends on latitude and altitude (in southern Italy it can last from December to January); the animal spends this period in the water (under the mud that is on the bottom) or on land (close to the water basin). When it stays under water during winter season (with temperatures lower than 10°C), it can take oxygen from cloacal epithelium; this is possible because the oxygen demand is extremely low as a result of its extremely slowed metabolism. The European pond turtle is sedentary, and only changes water basins during breeding season (the males to search for females, and females to search for an appropriate deposition site); during this period they can travel for several kilometres looking for the appropriate place.^{7, 8, 5}

It is an omnivorous species: its diet is characterized by water plants, fishes, tadpoles, aquatic invertebrates, carrions. Juveniles are more strictly carnivores than adults and feed on insects, leeches, aquatic molluscs, and small fishes.⁵

IUCN Red List consider *E. orbicularis* as Lower Risk/Near Threatened (1996); Italian IUCN consider it as Endangered. The species is included in the Bern Convention in Appendix II.⁹

1.2 Sex identification and determination in European Pond Turtle

Sex identification in all chelonians could be easy, in adult specimens, considering the phenotypic differences. In European pond turtle, gender identification is possible considering several characteristics: it has been reported that females are significantly heavier than males, have longer carapace than males, and carapace width, plastron length, plastron width and scute height are bigger in females than in males.¹⁰ However, in this species, as well as in other chelonian species, the best

way to identify sex in adult and subadult specimens is to compare tail length and cloacal position on the tail: in males, the tail is longer and cloacal vent is further from plastron.¹⁰

Turtles are characterized by high longevity and late maturing and are not sexually dimorphic until approaching sexual maturity (e.g., marine turtle species often take over 15 years to become sexually mature). Early sex identification is a challenge in several reptile species, especially in chelonians.^{11,12,13} Several methods have been reported, but before we examine them, it is important to explain how sex is determined in most chelonian species. Incubation temperature is a critical factor for sex determination; this process is termed temperature-dependent sex determination (TSD).¹¹ Temperature profoundly affects the biology and behaviour of all cold-blooded animals, including chelonians. Temperature influences their sex ratio, length of incubation, emergence from the nest, growth, activity, survival, nesting intervals, hibernation, and distribution. Temperature in embryos is the most important component of environmental sex determination. TSD and sex chromosomes are apparently mutually exclusive sex determining mechanisms. Sex chromosomes are unknown in the animals in which temperature sex determination occurs, but they occur in most animals which do not show any sex determination response to temperature. Many reptiles (e.g. crocodylians, tuataras, some lizard taxa, and most turtles) lack sex chromosomes and instead have TSD. Under TSD, gonads differentiate into ovaries or testes depending on the incubation temperature of the eggs during a critical period of embryonic development.¹⁴ In turtles, the most common pattern of TSD shows cool temperatures producing males and high temperatures yielding females.^{15,16,17,18} Previous literature highlights the potential impacts of climate change (both via warmer averages and increased thermal fluctuations) on species with temperature-dependent sex determination.^{19,20} With regards to most turtles, including all sea turtle species, the most common prediction is increased extinction risk associated with extremely female-biased sex ratios.^{20,21,22,23}

The European pond turtle shows the pattern of TSD typical for many turtles: incubation temperatures lower than 27°C are masculinising, while temperatures higher than 30°C are feminising.²⁴ The range of temperatures (28.51±1.15°C for *E. orbicularis*) producing both sexes is considered the transitional range of temperatures. The temperature producing both sexes in equal proportion is the pivotal temperature.²⁵ Usually, the transitional range of temperature and pivotal temperature are identified for incubations at constant temperatures. In the wild, where the temperature often changes during development, these statistics do not predict the sex ratio correctly.²⁶ Temperature is important for sex determination only during a short period, called the thermosensitive period.²⁵ This period in *E. orbicularis* is normally in the middle third of incubation, when the gonads appear, when embryos have mass from 160–180 mg to 650–750 mg.²⁷ That period is standardisable when incubation temperature is constant; however, this correspondence is not valid when temperature

changes during incubation according to daily fluctuations and seasonal trends. Indeed, these studies have been conducted under artificial condition but, in natural condition, prevision of the gender is a challenge.

As mentioned before, in wild animals (or in animals incubated at environmental temperature), it is impossible to foresee the sex of the hatchling as consequence of inconstant incubation temperature; for this reason, it is important, in conservation programs, to find the best method (intended as in fastest and cheapest) to recognise sex, just before releasing the animals (both autochthonous in wild and allochthonous in controlled areas).

Currently, we can distinguish several methods to early recognise sex in chelonians, which are:

- surgical method (using endoscopy -celioscopy, cystoscopy, and cloacoscopy-)
- hormonal evaluation on hatchlings
- hormonal evaluation of eggs

Surgical methods are the gold standard because these represent the only way to view the gonads directly (or indirectly).

All these methods will be explained in the chapter titled “Endoscopy”, as this is the topic of the dissertation.

Hormonal evaluation from chorioallantoic/amniotic fluid has been performed comparing testosterone and oestradiol concentration; in particular, the E/T ratio is significantly lower in males than in females. This method has been studied in loggerhead turtles, green turtles, and North American pond turtle and common snapping turtlea.^{28,29}

Hormonal evaluation on hatchlings has been done with research of Anti-Mullerian Hormone (AMH) that can be reliably detected in blood samples from neonate male turtles but not females and can be used as a sex-specific marker. In the study performed in 2020, verification of sex via histology or laparoscopy revealed that this method was 100% reliable for identifying sex in both *T. scripta* and *C. caretta* 1–2-day-old hatchlings and 90% reliable for identifying sex in 83–177-day-old (120–160g) loggerhead juveniles.³⁰

1.3 Environmental risk and biological competition with *Trachemys scripta*

American pond sliders, especially the red-eared slider (*T. scripta elegans*), have been the most common pet turtles all over the world since the 1970's. Their abundance on the international market is a consequence of their initial small size (about 3 cm), their ability to survive even in poor husbandry condition, and their low price; for these reasons, USA exports of red-eared slider hatchlings were estimated to be around 52 million between 1989 and 1997.³¹ The majority of owners were rarely prepared to maintain large adults (the animals can grow up to 30 cm carapace length) for a long time in captivity, so

those larger adults were released in ponds in many places and because of this, red-eared sliders now occur in freshwater ecosystems in many countries over all continents except Antarctica.³² In Europe, presence of *T. scripta* populations occurs in 29 countries and successful reproduction has been described in Austria, Spain, France, Italy, Slovenia, and the Balkan peninsula.^{33,34,35,36,37,38,39,40} Establishment of invasive alien species in a different environment can have variable effects on local ecosystems. Normally, the allochthonous species compete with native species for food, nesting sites, mating sites, and best position on basking sites; furthermore, there could be other phenomena, such as predation, hybridation, and disease transmission which result in a reduction of native biodiversity and change in species range and alteration of genetic resources.^{32,40}

In Europe, *T. scripta* competition is explained against native species, which are the European pond turtles (*Emys orbicularis* and *E. trinacris*), Spanish terrapin (*Mauremys leprosa*), and Balkan pond turtle (*M. rivulata*). Compared with native species, *T. scripta* reaches sexual maturity at a lower age and is characterised by higher adult size, fecundity, and aggressiveness. As mentioned before, one of the most important competitions is for basking sites: basking is a vital activity, as it allows thermoregulation and the activation of metabolism and, as consequence, food ingestion rate.⁴¹ It has been demonstrated that *T. scripta* outcompetes both *E. orbicularis* and *M. leprosa* (respectively classified as Nearly Threatened and Vulnerable by the International Union for Conservation of Nature – IUCN) resulting in population dispersal, reduced performance, and higher mortality for the native species.^{41,42,43} Competition for food resources seems less important than basking competition: native Spanish and European pond turtles seem to feed mainly on animal sources, while *T. scripta* are mainly vegetarian, especially the adults.⁴² *T. scripta* is an opportunistic species, which explains omnivorous behaviour in environments characterised by limited resources; in this condition, both juveniles and adults can display aggressive behaviour and reduce food availability for native species.^{42,44,45,46}

Introduced species can also explain their negative effect in the new environment by disease transmission. In Europe, several helminth species naturally infecting American turtle species were found infecting wild *E. orbicularis* or *M. leprosa*, suggesting probable parasite introduction and host-switching.⁴⁷ These include digenean trematodes such as *Spirorchis elegans* and *Telorchis attenuata*, nematodes such as *Spiroxys contortus*, and monogeneans such as *Neopolystoma orbiculare* and *Polystomoides oris* (the last two were also found infecting native species in Asia and displaying low host-specificity).^{44,45,46,47,48,49} As with other infectious diseases, helminths may exhibit greater virulence to the host with which they have no co-evolutionary history than to the natural host; therefore, native turtles could be more susceptible to pathogens of invasive species and exotic turtles could be more sensible to native parasites.^{50,51,52}

For all these reasons, *T. scripta* is enlisted among the 100 most invasive species by the IUCN,⁵³ and nowadays the species is declared illegal, with EU Reg. 1143/2014 (“on the prevention and management of the introduction and spread of invasive alien species”) and EU Reg. 1141/2016 (“Commission Implementing Regulation adopting a list of invasive alien species of Union concern pursuant to Regulation (EU) No 1143/2014”), applied in Italy with D.Lgs. 230/2017; these regulations forbid *T. scripta* detention, dislocation, commerce, breeding, and release inside the European Union.

1.4 Chelonian coelomic anatomy

The principal characteristic of chelonians is the presence of the shell—this is composed by the carapace (dorsal shell) and the plastron (ventral shell); these two parts are connected laterally by the bridge. The carapace consists of bones derived from ribs, vertebrae, and dermal elements of the skin; these are organized in scutes; the plastron has 9 bones evolved from the clavicles, coracoids, interclavicles, and abdominal ribs.^{54,55} Chelonians do not have a separate abdominal and thoracic cavity but have a single pleuroperitoneal cavity called a coelom, or coelomic cavity. In the coelom, the lungs are separated from the remaining viscera by the *septum horizontale*, or pleuroperitoneal membrane, which is not, however, a real muscle like the diaphragm in mammals—it is attached to the liver, stomach, and intestines. The pericardial sac separates the pericardial cavity from the coelomic cavity. Lungs, wide sac-like structures, occupy the dorsal part of the coelom adhering to the inner surface of the carapace, with the anterior part being in retro-coelomic position and the posterior part projecting inside the coelom.⁵⁴ Macroscopically, the lungs are large and spongy and the right and the left are about the same size. The surface of the lungs is mainly pink, alternates with a whitish reticular structure characterised by bundles of smooth muscle and connective tissue. This reticulum has the function of separating the pulmonary saccular structures that are equivalent to the alveoli in mammals. As consequence of the non-expandable shell, breathing occurs by the action of the neck, limbs, and of antagonist muscles, creating different intracoelomic pressure—this allows the lungs expansion during inspiration: the air entrance is guaranteed by muscles that push the forelimbs cranially creating a negative pressure inside the coelom which favours the entry of air, the action of the oblique muscle associated with the relaxation of the transversus and diaphragmaticus muscles cause the lungs expansion. The expulsion of the air is consequence of active contraction of the transversus and diaphragmaticus muscles which adds the pressure of the viscera towards the lungs. Since there is no real diaphragm and a costal arch that guarantee a negative entrance of the air, an eventuality damage of the carapace with exposure of lungs doesn't impact on the functionality of the lungs, as would happen in mammals.^{55,56} In terrestrial turtles, the inspiration is mostly passive while the expiration is active, contrary to the aquatic chelones in which the expiration is passive due to the hydrostatic pressure of the water.⁵⁶ A study carried out on the snapping turtle (*Chelydra serpentina*) has shown that this animal, when submerged, has an active inhalation and a passive exhalation of the air given by the hydrostatic

pressure of the water which acts on the visceral volume; on land, while inspiration is mostly passive, expiration is active as it normally happens in terrestrial chelones. The heart lies in a ventral anterior position just above the plastron and cranially to the liver. It is separated from the rest of the coelomic cavity by the *septum transversum*, which forms the posterior part of the pericardial sac.^{54,55} The liver is centrally located in the coelomic cavity immediately caudal to the heart, ventrally to the lungs. It is a very large organ, divided into lobes: two principal lobes (right lobe, left lobe) and two transverse lobes. The small gallbladder lies on the caudal edge of the right lobe.^{55,57} The caudal surface surrounds the stomach and the duodenum.^{54,55} The stomach is simple and fusiform and lies caudally to the liver, with the fundic region on the left and the pyloric region centrally or slightly shifted to the right. The gastric ligaments are the hepato-gastric ligament, which runs from the small curvature of the stomach to the caudal portion of the liver, continues distally with the hepato-duodenal ligament and is partially fused with the mesocolon of the transverse colon; there is also the mesogastrium, which fixes the stomach to the left lateral wall of the carapace.^{55,57,54} Duodenum, jejunum, and ileum are poorly differentiated. Duodenum lies in the right coelom and is attached to the right liver lobe by the hepatoduodenal ligament; closed to its proximal portion there is the pancreas. The large intestine begins with the caecum, which lies in the right caudal fourth of the coelomic cavity and has no mesenteric attachments; it is not a distinct organ but is an extension of the distal colon and, therefore, it is not very developed.^{55,57} The colon can be divided into ascending, transverse, and descending. In *Testudo hermanni* the ascending and descending portions are dorsally attached to the pleuroperitoneal membrane thanks to a very short ligament; on the contrary, the transverse portion is connected to the stomach through the mesogastrium. Descending colon enters the cloaca (common ending of digestive and urogenital tract) in the coprodeum.⁵⁴

UROGENITAL AND CLOACAL ANATOMY

Chelonians' kidneys are located in the caudal retro-coelomic cavity, just cranial to the pelvic girdle, often closely associated with the carapace. In males, the testicles are attached, in a cranio-medial position, to the kidneys; in females, the oviduct and the ovaries (very large and enveloped by the coelomic membrane) are placed ventro-medial to them. The kidneys of reptiles are characterised by the typical metanephric structure of most vertebrates, but do not have the loop of Henle and the renal pelvis. A renal portal system ensures the inflow of part of the venous blood coming from the more caudal regions of the body.^{55,57} In chelonians, unlike in other reptiles, the ureters terminate inside the bladder neck, which is hard to distinguish from the urodeum. The bladder is single, bilobed and positioned ventrally in the coelomic cavity; when it is full, its length could be half the length of the plastron. The Emydidae have two accessory bladders, positioned in the dorsolateral portion of the urodeum. The urethra, very short, directly connects the bladder to the ventro-medial portion of the urodeum, from which it doesn't have a clear anatomical separation.^{55,57}

The male reproductive system is characterised by testes, epididymides, vas deferens (which connect the testes to the cloaca), and penis. The testicles of chelonians are ovoid and yellowish, placed dorso-medially inside the coelomic cavity cranio-ventrally to the kidneys (which are retrocelomatic); the right is slightly more cranial than the left. Their size varies greatly depending on the season. The epididymis are long and coiled, and lie on the lateral caudal surface of the testicles. They appear dark in colour. The vas deferens lead caudally and head towards the urodeum, opening into the urogenital papilla. The copulatory organ is characterised by a single penis placed in the cranioventral portion of the cloaca and, contrary to mammals, it is not responsible for urination.^{55,57}

The female reproductive system is characterised by ovaries and oviducts. Ovaries are located in the same position of the testicles and are suspended in the coelomic cavity by the mesovarium. The size of these varies according to the season; during inactivity (out of the breeding season or before sexual maturity), the ovaries are small and granular, while during the reproductive season they consist of large lobular sacs with spherical follicles, ochre-yellow in colour. After ovulation, the follicles pass through the oviduct, where fertilization takes place and, subsequently, the albumen, the various covering membranes, and the shell are added.^{55,57} The oviduct of reptiles is characterised by four distinct regions: the anterior infundibulum, the posterior infundibulum (which in some species contains the tubules for sperm storage), the uterus, and the vagina.^{58,59} In chelonians, there is no clear distinction between uterus and infundibulum.^{55,57}

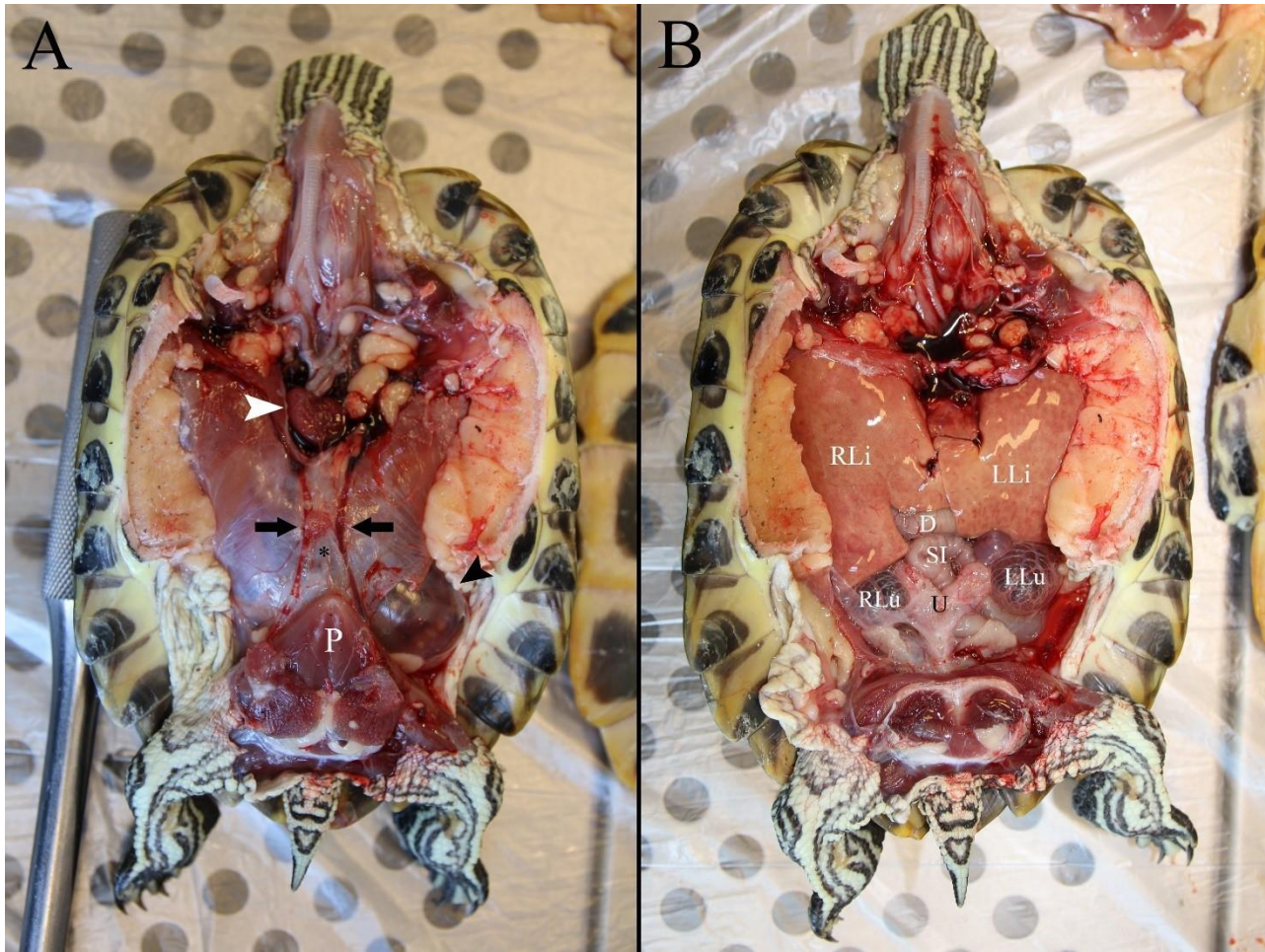
The oviduct then is directed caudally, passing laterally to the rectum, and flows directly into the urodeum through the genital papilla.^{54,55,57} From the observation of this papilla, recent endoscopic approaches make it possible to determine the sex of the animal, even if very small.⁶⁰

Reptiles' cloaca (the most distal part of the digestive and the urogenital systems) is composed of three chambers: coprodeum, urodeum, and proctodeum. This subdivision is less marked, but still present, in chelonians. The most cranial part is the coprodeum within which the colon ends; these two organs are well separated by an evident mucous fold. Here the faeces are eliminated, coming from the gastrointestinal tract, and then pass through the urodeum and proctodeum. The urodeum, on the other hand, is the intermediate portion inside which both the urethra and the ducts of the reproductive system end (the seminiferous tubules in males and the two oviducts in females). The urethra is very short and, having a cranio-ventral course, connects directly to the neck of the bladder.^{55,57} The diameter of the urodeum lumen is much larger than that of the coprodeum; inside, it protrudes a series of mucosal folds with a longitudinal direction that in the last section become more and more irregular, also taking an oblique and transverse direction. These folds are already present, but much less pronounced, in the coprodeum.⁶¹ This cloacal architecture allows the urine (coming from the urodeum) to be mixed in

the proctodeum with the faeces (coming from the coprodeum) before their emission; here it is also possible the onset of antiperistaltic waves that bring the mixed contents back into the colon to be further absorbed (especially liquids), or the passage of water directly from the proctodeum to the bladder.⁵⁷ However, faeces are hardly found in the urodeum, which is used to "store" the products of the urogenital system while the excrement passes through it quickly, or bypass directly it.⁶¹ The proctodeum is the most caudal portion where the products coming from the urodeum and coprodeum arrive—from the bladder, genital organs (eggs and semen), and intestine.⁵⁷ The cloacal orifice is circular and is located ventrally to the tail and caudal to its attachment to the plastron; the skin around it is normally low in flakes. In males, there is a single penis located cranially to the orifice and ventrally on the floor of the cloaca at the base of the tail. For this reason, the cloacal orifice is more caudal in males than in females: in males, it is located distally in the ventral part of the long tail, while in females it is located within the caudal margins of the carapace. The penis has a pointed conical shape, often very pigmented and with a median raphe along which the semen flows during copulation; in *Testudo* sp., during erection, it can be even three or four times longer than normal.^{55,57} The female chelonians have a clitoris of various sizes placed in the cranial-ventral portion at the base of the tail; there is also a cloacal diverticulum that allows sperm storage for several years.^{57,62} In reptiles, both in the cloaca and in the pericloacal regions, there are numerous glands secreting oily fluids, pheromones, hormones, and other chemicals that seem to have different functions, including individual recognition, attraction of the other sex and, especially for females, the lubricating action at the moment of egg laying.^{63,64,65,66,67} This last characteristic has also been demonstrated for female *Testudo hermanni*.^{55,57}

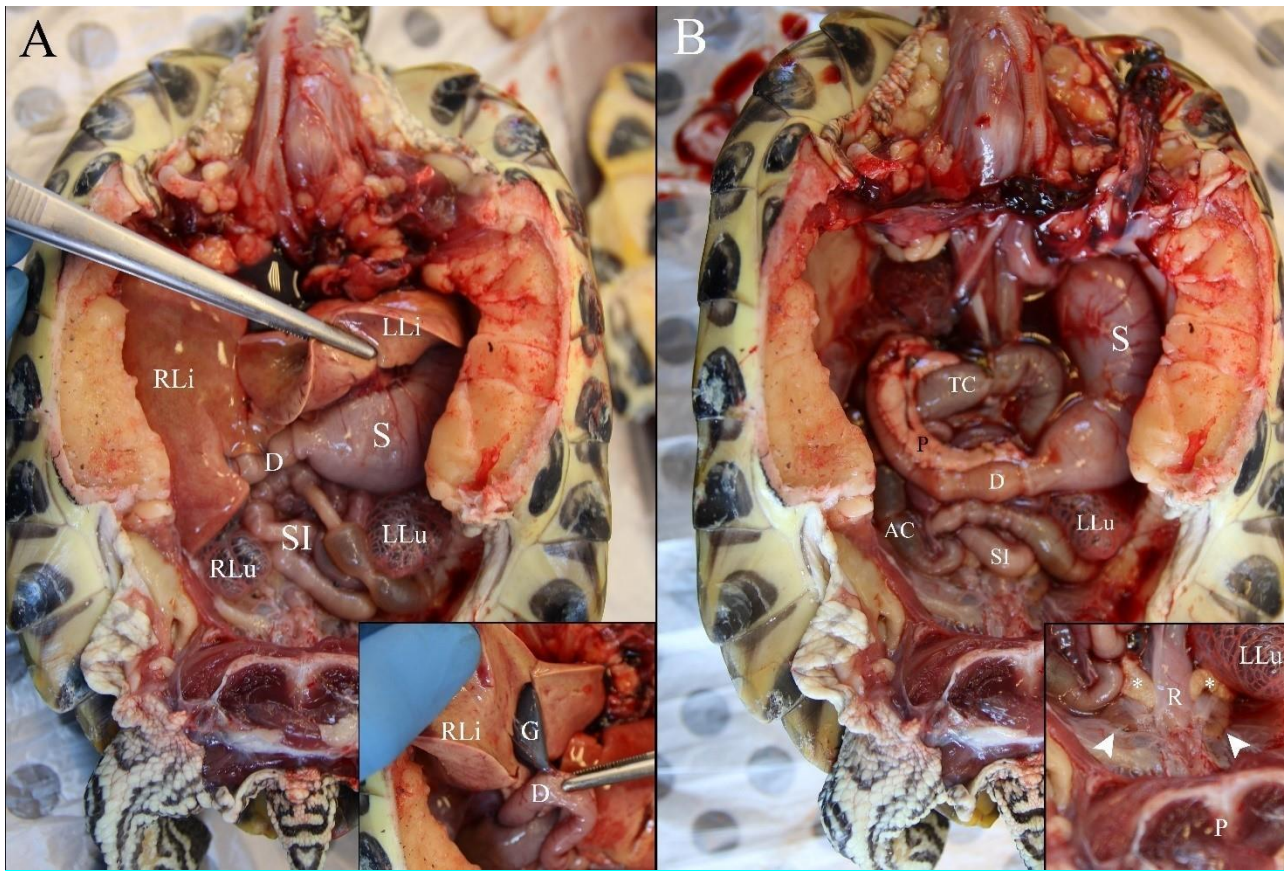
It has been demonstrated that, in aquatic turtles, the cloaca has the ability to carry out gaseous exchanges with the external environment, thus allowing extrapulmonary respiration, which occurs here and more markedly at the trans-cutaneous level (present in some aquatic species like Trionychidae); this ability, however, is not present in the terrestrial tortoise.^{68,69,70}

Figure 1 – Ventral view of a juvenile *T. scripta* in dorsal recumbency. **A**: only plastron removed. **B**: colemic organs after removal of plastron, pelvis, muscular abdominal wall and coelomic membrane.



A: P = pelvis; arrows: abdominal veins; *= muscular abdominal wall; black arrowhead: coelomic membrane (after partial rupture of the muscular wall); white arrowhead: heart (after removal of pericardial sac). **B**: D= duodenum; RLi= right liver lobe; LLi= left liver lobe; RLu: right lung; LLu= left lung; SI= small intestine; U: bilobated urinary bladder. Photo courtesy of the Pathology Section of Department of Veterinary Medicine, University of Milan. Captions made by Dr. Edoardo Bardi.

Figure 2 – Ventral view of a juvenile *T. scripta* in dorsal recumbency. **A:** colemic organs after removal of plastron, pelvis, heart, muscular abdominal wall and coelomic membrane. **B:** after removal of the liver.



D= duodenum; G= gallbladder; RLi= right liver lobe; LLi= left liver lobe; RLu= right lung; LLu= left lung; S= stomach; SI= small intestine; P (black)= pancreas; P (white)= pelvis; AC= ascending colon; TC= transverse colon; R= rectum; *= ovary; arrowhead= kidney. Photo courtesy of the Pathology Section of Department of Veterinary Medicine, University of Milan. Captions made by Dr. Edoardo Bardi.

REPRODUCTION ENDOCRINOLOGY AND BEHAVIOUR

Reptiles have a neuroendocrine regulation system of reproduction very similar to other vertebrates. The sensory systems and specific brain areas act, integrating internal and external stimuli and causing the changes related to the season necessary for the reproductive system.⁶²

Specific areas of the hypothalamus secrete gonadotropin releasing hormone (GnRH), which induces the release of gonadotropins from the anterior pituitary gland (FSH and LH), which influence gonadal development and function, also inducing the secretion of steroid hormones (progesterone, testosterone, and estrogen); these hormones have the ability to

regulate hypothalamic and pituitary hormone secretion through a negative feedback mechanism. Steroid hormones are secreted by the gonads and adrenal glands; it has been shown that, in reptiles, they can have appreciable variations in secretion during the reproductive season.^{62,57}

Like all chelonians, European pond turtle is an oviparous species and reaches sexual maturity depending on the body size. Growth rate is very slow in these species, especially compared with North American pond slider—growth rates depend on food availability and environmental characteristics, with populations from warm and food-rich areas maturing earlier than animals from colder and with less food availability habitats.

Like other species from temperate climates, European pond turtle is a seasonal breeder, depending on environmental variables such as temperature, photoperiod, and food availability;⁷¹ breeding season usually starts right after winter hibernation (February-May in the boreal hemisphere, depending on the geographic localisation). Chelonians that don't hibernate mate throughout the year—conversely, those that brumate or hibernate or aestivate, mate during the remaining seasons. In any case, the principal mating activity and laying period are concentrated above all in the spring season.

Testosterone, secreted by the Leydig cells of the testis, directly regulates spermatogenesis, which peaks in spring with intense sperm production. At the peak, the size of the testicle and the mobilisation of fatty acids increase; these last are used for lipid secretion by the various segments that characterise the male genital system. This secretion is added to the seminal fluid and contributes to the formation of the "vaginal plug" after mating. LH and FSH appear to have the same functions as they do in phylogenetically superior vertebrates, and they both influence behaviour during the breeding season.^{62,71}

The females have a seasonal cycle, with depositions concentrated in the spring-summer period; however, this cyclical activity can vary in tropical species where the rhythm is controlled by dry and rainy seasons. During the follicular phase, as in mammals, oestradiol increases significantly; moreover, in reptiles, unlike mammals, there is also a notable increase of testosterone. Testosterone level does not seem to be related to oestradiol level but affects the number of preovulatory follicles and influences the female mating behaviour.⁵⁵ Furthermore, high plasmatic testosterone concentration is observed in spring, before ovulation of the first clutch of follicles in *Sternotherus odoratus* and *Terrapene carolina*;^{72,73} in *Graptemys flavimaculata*, testosterone increases in summer as well, corresponding to second clutches ovulations.⁷⁴ The cycle, very similar to what happens in other vertebrates, is influenced by the gonadotropins released after stimulation by the GnRH. Oestradiol is mainly secreted by the granulosa cells and is responsible for follicular development, vitellogenesis (yolk deposition, stimulating hepatic production of vitellogenic proteins), and ovulation. Oestradiol increases in the preovulatory

phase and in late summer and autumn as well, enhancing follicular growth for the following season.^{72,75} Progesterone, like in mammals, is secreted by the corpora lutea during the post-ovulatory phase (and, partly, by the adrenal glands), contributing to maintaining pregnancy and egg formation.^{76,77,78} Furthermore, progesterone may play a role in the positive feedback regulation of the LH peak in turtles, before ovulation.^{72,79,80} Progesterone increases in periovulatory periods, and presents a small plateau phase after ovulation. E₂ highly increases in late summer and autumn as well, enhancing follicular growth for the following season.^{72,75} Vitellogenesis is characterised by the maturation of follicles that secrete oestradiol, which stimulates the production, in the liver, of yolk protein precursors such as vitellogenin. In turtles, normally, vitellogenesis has a very long duration (up to three months), and in this period there is a slow follicular growth and a low but constant production of vitellogenin.⁶² As already mentioned above, there are significant dimensional variations of the genital structures (ovaries and oviducts) related to the season of the year and, therefore, to the different concentrations of hormones.^{58,59} The reproductive cycle *Trachemys venusta* has been described in a survey in 1971—four phases and four classes of follicles were described: phase of follicular enlargement (vitellogenesis), phase of ovulation and intrauterine development, phase of ovodeposition, and phase of quiescence.⁸¹ Regarding follicle classification, they are defined according to their diameter in Class I (≤ 6 mm), Class II (7-13 mm), Class III (14-20 mm), and Class IV (≥ 21 mm). Vitellogenesis usually starts from late August and reaches full follicular maturation in autumn just before hibernation: this pattern is called postnuptial reproductive cycle and is displayed by most temperate climate turtles; this allows the animals to be immediately ready to mate after hibernation.⁷⁵

Ovodeposition usually takes place in spring and summer (from April to August); sometimes, if environmental factors allow, there could be another deposition season from August to October. But normally, when a single clutch is laid, ovarian follicles decrease in size during deposition period, and, as previously stated, vitellogenesis starts again in late summer to autumn.^{81,75,82} Nesting behaviour in this species has been widely described. Distance from the main pond to the nesting areas which was probably covered by all females in Kuculishkes ranged from 150-1000 m. In general, mature females of *Emys orbicularis* must take terrestrial excursions during the nesting season in Italy about 150-600 m,⁷ in East Germany about 150-800 m,⁸³ in Poland up to 2 km^{84,85}, and in East-Poland up to 5 km.⁸⁶ Results of this study approximately support these findings. Some Lithuanian females started exploratory travelling before nesting—for example visited two nesting areas during the same season, that is they did not walk directly to a nesting area. Probably, they checked out different suitable nesting sites.⁸ Interannual fidelity of females to the nesting area was also reported for *Emydoidea blandingi* in Michigan,⁸⁷ *Chelvdra serpentina* in North America⁸⁸, and *Emys orbicularis* in Poland,⁸⁴ East-Germany⁸³, and Italy.⁷ It has

also been reported that several females of *Chrysemys picta marginata* in Canada deposited eggs within 10 m of their previous nest.⁸

It has been supposed that in chelonians, clutch size is not correlated to the age of the female, but it is directly correlated to her dimensions (both plastron length and body weight), with the clutch weighting approximately 5.1% of the female's body weight.^{81,89,90} Clutch size in different part of Europe can vary from 1 to 22 eggs. Incubation period (IP) usually ranges from 60 to 80 days, but wide variations are reported depending mostly on incubation temperature (e.g. 112 days below 25°C).⁸¹ Hatching takes place in late summer and early autumn but, sometimes, in case of late depositions, or in the northern part of the distribution area, hatchlings can overwinter inside the nest and leave it the following spring.⁹¹ As previously stated, environmental conditions in the nest play a crucial role in sex determination of the hatchlings: as many part chelonian species, European pond turtle shows a temperature-influenced sex determination.⁹²

1.5 Endoscopy

ENDOSCOPY IN EXOTIC PETS

Endoscopy (from Greek, ἔνδον ἔνδον, "inside, internal", and σκοπή skopê, "observation") is an instrument that is increasingly used in daily clinical practice, not only for surgical procedures but also for medical and diagnostic procedures. In pet animals clinical practice, endoscopic procedures are increasingly being used for various reasons: patients are often small in size, making them ideal candidates for minimally invasive procedures; the collateral investigations available, both clinical pathology and diagnostic imaging, are not always able to provide sufficient information for a precise ante-mortem diagnosis; endoscopy can associate the visualisation of a lesion with the possibility of taking a biopsy or material for microbiological tests in the same site; finally, endoscopy can help to overcome the physiological limits set by individual species, such as the reduced opening capacity of the rabbit's oral cavity or the limits posed by the peculiar anatomy of chelonians.^{93,94,95,96,97,98,99}

The basic equipment generally used for endoscopic investigations in exotic animals consists of: a rigid endoscope, generally with a 30° angle, 2.7mm telescope with a 3.5mm protective jacket or 4.8mm operating jacket, connected to a source of Xenon light and to an endovideo camera and monitor,^{93,99} sterile saline solution with sterile dripper for infusions of sterile solution. The 2.7mm rigid endoscope seems to be the most versatile and therefore the most used in clinical practice.^{93,99}

Both diagnostic and surgical endoscopy in the reptilian patient is a rapidly expanding field, as it offers particular advantages:

- the visceral anatomy and the physical conformation of some animals (saurians, loricates) make it relatively easy to access all organs and have a good ability to visualise and perform biopsies throughout the coelomic cavity^{98,100}
- endoscopy makes it possible to overcome some anatomical barriers and make some diagnostic and surgical procedures less invasive than normal in those animals in which anatomy places a major limit (i.e. chelonians)^{97,98,100}
- the possibility of visual evaluation of the organs, and to carry out biopsy samples in the same location, places great improvement in the diagnostic capacity in a class of animals where pathognomonic clinical signs are often lacking and the clinical pathology is often difficult to interpret due to intraspecific seasonal and gender variations.

There are several approaches to apply diagnostic endoscopy; these vary considering the order (Testudines, Squamata, Crocodylia) and the organs that need to be checked. Diagnostic endoscopy offers a valid help and is not to be considered a last resort, but it is an important investigation and confirmation tool. Obviously, like other diagnostic techniques, its application cannot ignore or replace an accurate clinical examination and preliminary diagnostic imaging investigations and clinical pathology; because the information obtained with these investigations may indicate the endoscopic approach and / or technique depending on the target organ of the investigation.^{98,100,101}

In order to be subjected to diagnostic endoscopy, and even more so for a celioscopic intervention, the patient must be carefully evaluated, and the procedure must only be performed after clinical stabilisation; alternatively, the procedure can be performed even in patients at medium or high risk, but this practice is acceptable only if stabilisation is not possible. Furthermore, to ensure the safety of the patient, the medical staff, and the equipment, it is necessary to perform an optimal anaesthetic control of the patient during both diagnostic and operative endoscopy. Analgesia must be especially suitable for celioscopic interventions, because the insufflation of CO₂ inside the coelomic cavity causes dislocation of the viscera and can cause intraoperative and postoperative pain: for this reason, local anaesthesia at the entry site is not enough, and it is necessary to ensure that all the gas that has been blown inside during the procedures is completely removed before closing the surgical breach. The compression of the lungs is possible during the insufflation of the gas inside the coelom, as the possibility of a decrease in the depth of the anaesthetic plan in patients maintained with gas anaesthesia is reported, due to the reduction in lung volume mediated by the increase in extrapulmonary pressure caused by the blown gas.¹⁰²

Saurians are the patients in which the endoscopic procedures are more documented, mainly due to the greater ease of execution of the various procedures compared to other members of the reptile class.^{98,100,103} The diagnostic procedures reported in saurians are the following: tracheoscopy and pulmonoscopy, stomatoscopy and gastroscopy, cloacoscopy, coelioscopy. Tracheoscopy and pulmonoscopy are performed with the mouth opened by a suitable mouth opener; the

endoscope (generally rigid for small and medium-sized patients, although a flexible endoscope can be used for larger patients) is inserted into the trachea, making it possible to visualize the tracheal rings, the tracheal mucosa, and the presence of alterations. With a gentle manipulation of the patient's body and neck, it is possible, in patients of suitable size, to visualise the lungs. Normally, a short period of complete tracheal occlusion is well tolerated, although it may be helpful to guarantee a deep breath in before inserting the endoscope.⁹⁸ Stomatoscopy and gastroscopy are two of the first endoscopic techniques described in reptile patients, used for the search and removal of gastrointestinal foreign bodies. In lizards, the patient is generally positioned in dorsal decubitus, with the head and neck extended. The endoscope is inserted to explore the buccal cavity, oral mucosa, oesophagus, and stomach. It is necessary to insufflate the stomach to have a good visualization of the mucosa and its contents and washing with sterile physiological solution can help to better visualise the affected structures and to take biopsies of any lesions in the oesophageal or gastric mucosa: however, care must be taken not to perforate the gastric or the much mucosa or the more fragile oesophageal mucosa. During cloacoscopy, irrigation is performed with sterile saline solution, and coprodeum, proctodeum, urodeum, distal colon, urogenital papillae, oviduct opening (when present), urethra and bladder (when present) are visualised through the entrance to the cloaca.^{60,102}

The coelioscopy allows an excellent visualisation of all the viscera contained in the coelomic cavity: the positioning depends mainly on the shape of the patient's body, as it is preferable to have a dorsal decubitus in patients with a compressed body in the dorsal ventral direction, and a lateral decubitus (e.g. bearded dragons) in patients with body compressed laterally (e.g. chameleons). Both positions can be performed for patients with a round body (e.g. Iguana sp.), although lateral decubitus generally allows an easy entry and excellent visualisation of the coelomic cavity. To perform it a single-port, endoscopy is done via a single paramedian or paralumbar incision.^{98,100,104} The green iguana can be considered a good model for coelioscopy in lizards:^{100,103,104} positioning in both left and right lateral decubitus allows visualisation of the lungs, liver, pancreas, intestinal packet, bladder gonads, adipose bodies, and kidneys; from the left lateral approach, the heart, stomach, and spleen are better evaluated, while from the right lateral approach, the gallbladder is better visualised. The tail should be secured by a bandage, and the breach is made in the area delimited caudally from the ribs, ventrally from the vertebrae, cranially from the pelvic limb.^{98,100,105} Once entered, the surgeon proceeds to insufflate CO₂ to create a pneumoceloma: the first organ that can be seen (in paralumbar approach) is the liver, brown in colour, located in the medial ventral part. By moving the endoscope cranially, it will be possible to visualise the heart. In iguanas, there are no diaphragmatic, post-pulmonary, or longitudinal membranes, which are instead present in other saurians, such as Tegu or varanids: minor perforations of these membranes generally do not pose a problem.^{98,100,103,105} Dorsal to the heart you can

appreciate the lungs, which reach up to half the overall length of the coelom. Caudally to these, it is possible to observe the stomach and the spleen. Behind the spleen, placed dorsally, the gonads are visible.^{98,100,103,105}

In the ophidians, the procedures that can be carried out are similar to those described for the saurians, with some substantial differences: the coelom appears to have a lower ability to stretch out, limiting the ability to insufflation and consequently to visualise the organs inside; there is a greater quantity of coelomic fat, which reduces the ability to visualise the organs; the anatomy of the ophidium patient does not allow the visualisation of all anatomical structures through a single entrance door.^{98,105} A transcutaneous approach to the air sac of the lung in the boides has been described; it can be performed at the dorsal level between 30% and 45% of the total length of the subject. This method can allow to also visualise primary and secondary bronchi and distal trachea.^{98,105,106}

The peculiar anatomy of chelonians sets objective limits while performing clinical examination and, furthermore, for the diagnostic imaging. Endoscopy, therefore, represents an excellent diagnostic support, because the less invasiveness and the possibility to provide direct visualisation of the organs and, at the same time, the possibility to take biopsy samples prove to be a great help to overcome the barriers imposed by the anatomical structures of the carapace, bridge, and plastron.^{97,98,105}

The endoscopic techniques described in the literature and used in chelones are stomatoscopy, gastroscopy, tracheoscopy and pulmonoscopy, cloacoscopy and coelioscopy.

Stomatoscopy and gastroscopy are performed in chelonians with modalities and purposes similar to those previously described in the animals belonging to the Reptilia class. Differences between chelonians and other reptile orders could be seen in tracheoscopy and pulmonoscopy. Trachea is really short in chelonians and separates immediately in two principal bronchi. Lungs are under the carapace and connected to this; for this reason, two different alternative approaches have been described: one carapacial and one prefemoral. In the first case, an osteotomy of about 4 or 5 mm in diameter is performed in the carapace, in correspondence with the injured lung areas (identified by appropriate diagnostic imaging), from which the pleuropulmonary membrane is identified and perforated using a trocar or suitable surgical instruments with blunt perforation. Then, the endoscope is inserted in the created small hole, in order to perform pulmonoscopy (taking into account that the orifice created inside the rigid structure of the carapace will allow less capacity for movement); this method allows the operator to view and take samples from lesions and perform biopsies and pulmonary washes. At the end of the procedure, it is possible to place a catheter in the hole made, in order to allow any intrapulmonary therapies, or to directly close the operative opening by applying sutures on the pleuropulmonary membrane and epoxy resin on the carapace.^{98,105}

Pulmonoscopy with prefemoral access can be performed with an incision directed craniocaudally in the skin of the dorsal part of the prefemoral fossa. A blunt dissection of the underlying tissues is then performed to create an access to the coelom, through which it will be possible to appreciate the transverse septum and the caudo-lateral surface of the lung. The caudal part of the lungs should be anchored to allow the possibility to incise it; the incision should be done in an avascular area of the caudal portion of the lung. This access guarantees a greater ability to manoeuvre the endoscope inside the lung, because the breach is made completely inside the soft tissues, and, furthermore, it allows to evaluate the entire lung proceeding in the caudo-cranial direction. In larger animals, it allows the visualisation of the primary bronchi. At the end of the procedure, it will be necessary to apply a suture on the lung wall in order to avoid a pneumoceloma, and to close the breach made through the remaining soft tissues.^{98,105}

Diagnostic celioscopy in chelonians was first described in 1984 by Brannian, who performed an exploratory celiotomy from the prefemoral fossa. The best access is represented by the left prefemoral fossa, with the patient kept in the right lateral decubitus. After the incision of the skin is performed, a blunt dissection of the underlying tissues (aponeurosis of the transverse abdominal and oblique muscles of the abdomen, and of the coelomic membrane) is necessary. Before carrying out the procedure, it is recommended to stimulate the patient at the cloacal level, to guarantee the emptying of the bladder. Once accessed, the coelom can be insufflated with CO₂ or sterile saline solution. The liver shows colours dark to brown and is located in the cranial portion of the coelom; the bladder (if full) is located in the caudoventral portion and the ovary, and follicles and the testes are located in front of the incision point. The heart is located in the cranioventral position to the liver, inside the pericardial sac. The gallbladder can be easily visualised in the caudal margin of the right hepatic lobe (close to the duodenum). The spleen is more difficult to locate, as it is located ventrally to the same hepatic lobe. The stomach lies caudal to the left hepatic lobe; the pancreas can be identified in the mesenteric ligament between the stomach and duodenum. Pancreas, spleen, and duodenum are most easily visualised with an entrance from the right prefemoral fossa, while the colon can be easily visualised from both accesses. In the dorsocaudal portion of the coelom, it is possible to visualise the caudal part of the lung; associated with its caudal margin, the gonads can be visualised. In the retrocelomatic position, kidneys and adrenal glands can be identified.^{98,100,105}

Although visceral topography in chelonians is similar, there is some interspecific variability regarding the visualisation of the various organs during the endoscopic procedure, but adequate comparative studies to describe these differences in a statistical sense lack.

The cloacoscopic procedure in chelonians has been described several times in the literature and with multiple purposes: the investigation of the structures of the cloaca, in order to evaluate any anomalies or pathologies affecting the coprodeum, urodeum, and proctodeum; the investigation and possibility to take samples or remotion of masses identified by diagnostic imaging and suspected to be localised in the cloaca; in the species in which they are present, the investigation of accessory bladders and using them also to transparently view the organs inside the coelom; the evaluation of the distal colon; the possibility to enter in the urinary bladder and carrying out diagnostic cystoscopy, both to evaluate its own structures (damage to the mucosa, masses, possible presence of stones or ectopic eggs) or to view structures of the coelomic cavity in transparency, to evaluate their morphology and colour, and as a method of sexing in immature animals.^{60,107,108,109,110,111,112,113}

The efficacy and safety of cloacoscopy is a consequence of a perfect knowledge by the operator of the anatomy of the inspected structures, because damage to the mucous membranes or perforation of the walls of the inspected organs can put the life of the subject at serious risk.^{98,107,109,110,111,112}

1.6 Chelonian anaesthesia and analgesia

Management of anaesthesia and analgesia is one of the most challenging aspects of reptile and chelonian practice. The high variability between the species and the lack of systematic reviews in these animals are the main difficulties. For these reasons, clinicians often take information from literature regarding other animal classes (especially small mammals); other times, they rely on information taken by colleagues' experiences.^{114,115} The metabolism of reptiles depends on environmental temperature; they are ectothermic animals, and this characteristic also affects drug absorption, distribution and excretion, or, in general, drugs' effects. One survey in pond sliders compared induction, duration, and recovery times after alfaxalone administration (10 and 20 mg/kg IM); these are significantly shorter at 35°C compared with 20°C.^{116,117} For this reason, it is generally recommended to keep the animals in their preferred optimum thermal zone (POTZ, 20-25°C for temperate aquatic turtles), even when performing anaesthesia and surgery.¹¹⁵

Furthermore, similar to other reptiles, chelonians have a renal portal system. Blood flows from the caudal area through coccygeal and iliac veins, and it breaks into the afferent renal portal vein, which transfers blood to the kidneys.^{118,119} Blood tubular perfusion leaves the kidney via the efferent portal vein, which joins the post-cava vein. The renal portal system is necessary to perfuse the kidney during dehydration, ensuring an adequate blood supply into renal tubules when the glomerular flow is reduced, and consequently it avoids ischemic damage.^{120,121} Depending on the hydration status, blood from the caudal portion can directly flow to the kidneys or may bypass it and flow straight into the systemic circulation.

This apparatus is ruled by a system of valves located between the abdominal vein and the femoral vein. The renal portal system makes drug administration challenging in numerous reptile species. The common advice is to administer drugs into the cranial quarter of the body to avoid an accelerated excretion by renal portal system, increase clearance, lower plasma levels of the drug, and efficacy. Several studies have shown that clinical relevance of this concern is minimal and that probably renal portal system may have a greater influence in dehydrated animals only.^{121,122} However, a study into the SC or IM administration in forelimbs or hind limbs of the same dosage of dexmedetomidine and ketamine mixture showed a strong difference in the sedative effect.¹²³ Because clinical evidence is missing, drug administration is recommended into the cranial quarter.¹¹⁴ As previously mentioned, the importance of the renal portal system regarding anaesthetic agents is still controversial, while hepatic first-pass effects seem to play a greater role in pharmacokinetic and pharmacodynamic of drugs injected in the caudal half of the body.^{114,115} The venous blood flow from the hind limbs in chelonians also drains into the ventral abdominal veins, which either pass directly to the liver or indirectly via the hepatic portal vein. Therefore, any liver-metabolised or excreted drug administered in the hind limb first enters the liver before reaching the systemic circulation, resulting in a hepatic first-pass effect and a possible lower bioavailability of drugs, resulting in reduced/altered clinical efficacy.^{121,122,124}

Other reptile characteristics include the cardiac anatomy and physiology. The heart has two separated atria and one ventricle divided in two chambers by an incomplete intraventricular septum. This feature allows mixing of oxygenated and deoxygenated blood and shunting of blood from both left-to-right (L-R) and right-to-left (R-L). R-L shunt is a physiological response to the increased pulmonary vascular resistance determined by the increase of parasympathetic tone; in aquatic animals like pond sliders, R-L shunts can be triggered by diving, hibernation, or even general anaesthesia; this can play a role in inhaled anaesthetic uptake and elimination, potentially causing delayed induction and delayed or unexpectedly rapid recovery.^{114,125,126}

ANAESTHESIA: different anaesthetic protocols are reported for endoscopic procedures in chelonians, but the literature gives more information about the practical aspects of the procedures rather than anaesthesiologic details. Endoscopy could be performed under local anaesthesia legally permitted under a scientific research license, but today we have the possibility to avoid to compromise the animal's welfare and reduce visceral discomfort thanks to recent developments in reversible injectable anaesthetics.^{127,128,129,130} Some investigators have reported using only local anaesthesia for chelonian coelioscopy, but this provides inadequate restraint and analgesia.¹³¹ In a recent comparison of local versus general anaesthesia for chelonian coelioscopy, objective anaesthetic scores were significantly better for procedures conducted with general (injectable) anaesthesia compared with local lidocaine alone.¹³² Certainly in clinical practice, general anaesthesia (or deep

sedation combined with local anaesthesia) is required for any coelioscopic sex identification.^{132,133} The difficulty to gain intravenous access in very small animals (the most common that clinician need to identify sex) and the impracticality of endotracheal intubation dictates the choice of injectable anaesthesia. For practical purposes, it may be necessary to dilute drugs using sterile water to achieve a measurable volume. Ketamine-dexmedetomidine-hydromorphone (or morphine) combinations have been consistently successful. Aquatic and semiaquatic species seem more sensitive, and dose rates of 10 to 20 mg/kg ketamine and 0.05 mg/kg dexmedetomidine are effective, whereas for terrestrial tortoises, higher doses are often needed in the range of 20 to 40 mg/kg ketamine and 0.1 mg/kg dexmedetomidine. This dissociative- α_2 combination is augmented with an opiate analgesic, and hydromorphone (0.5 mg/kg) is preferred over morphine (1.5 mg/kg), as the latter frequently results in respiratory depression.¹²⁷ All anaesthetics are combined into a single syringe and can be injected intramuscularly into the forelimbs or in pectoral muscles. Animals are then placed in a warm, quiet incubator (26.7°–29.4°C) for 30 to 40 minutes. Once adequately induced, the pelvic limbs are taped caudad to expose the prefemoral fossae. Local lidocaine (42 mg/kg) is injected into the left prefemoral fossa (or the right prefemoral fossa if the surgeon is left-handed and prefers to enter through the right side). Right lateral positioning is easily accomplished by placing the animal between 2 rolled and taped towels. Small patient size and short procedural time tend to prevent instrumentation for anaesthetic monitoring purposes. However, withdrawal reflexes should be lost but corneal reflexes retained. Before or after the procedure, meloxicam 0.2 mg/kg could be injected intramuscularly or subcutaneously into the forelimbs. Atipamezole at 10 times the dexmedetomidine milligram dose (same volume) could be injected intramuscularly and results in rapid recovery within 20 minutes. If opiate-induced respiratory depression persists despite reversal, naloxone 0.2 mg/kg intramuscularly is effective. When analysing anaesthesia-focused literature, other multimodal protocols involving α_2 -agonist and/or ketamine can be found. In Horsfield's tortoises (*Testudo horsfieldii*), alfaxalone and medetomidine provided moderate to deep sedation/anaesthesia with minimal or variable analgesia, but this drug combination could not allow intubation in all subjects and showed significantly higher recovery time (atipamezole was not used in this study); furthermore, marked cardiovascular depression was noted.¹³⁰ Intramuscular ketamine 10 mg/kg and medetomidine 0.2 mg/kg provided anaesthesia and analgesia adequate to place endotracheal tube and to perform skin incision and suture in pond sliders, with no cardiovascular side effects, with long onset (mean 45 minutes) and recovery time after reversal (30 to 60 minutes), but, according to the authors, this protocol did not seem to provide anaesthetic levels deep enough for surgical procedures.¹³⁴

For induction, single-drug protocols include IV propofol administration (5 mg/kg), and IV (10 mg/kg) or IM (20 mg/kg) alfaxalone administration. Intravenous administration of propofol/alfaxalone guarantees an almost-instant induction but

requires inhalant maintenance for medium-length surgical procedures. Moreover, GABA-agonists do not have analgesic properties, requiring opioids and/or NSADs for pain management.^{135,136,137,138}

Cloacal endoscopy is commonly performed without any anaesthesia or analgesia, despite intrathecal analgesia having been described in this order of animals.^{108,110,139}

ANALGESIA: Reptile pain and analgesia is only beginning to be understood in veterinary research and clinical medicine.¹²⁰ The diversity of the class Reptilia also makes it difficult to extrapolate analgesic efficacy across species. Many veterinary clinicians argue that the administration of analgesic medication is risky to the patient and may mask behavioural signs of pain, which are considered evolutionarily adaptive for survival. However, veterinarians have an ethical obligation to treat painful conditions in all animals, including reptiles, because, in general, effective pain management reduces stress-induced disruption to homeostatic mechanisms and decreases morbidity and mortality associated with trauma or surgery. Nevertheless, there are a lot of limits to a successful use of analgesic drugs, including subjectivity of pain assessment, inadequate knowledge regarding analgesic efficacy across species, pharmacokinetics, and the unknown relationship between risks and benefits for this class of drugs. Measuring pain in reptiles is really hard, and there are a lot of different methods that try to estimate it and to recognise the analgesic effects of different drugs. The ideal condition consists of evaluation of a combination of appropriate behavioural and physiologic parameters to measure pain and analgesia in reptiles. For these reasons, it is important to know exactly the normal ethogram of the studied species to recognise precisely the normal and the abnormal (consequence to pain) behaviour. A study has already been published concerning comparison between turtles with analgesic administration and without analgesic administration in the postoperative period; the authors used morphine, butorphanol, and saline solution, and developed a behavioural ethogram to evaluate preoperative and postoperative behavioural responses to food intake, willingness to swim, and breathing after unilateral orchidectomy.¹⁴⁰

Other studies have been published testing analgesic effects of drugs using thermal stimulation of the limbs. Authors were able to identify a slowing of reflexes in animals after analgesic drug administration.¹⁴¹ Other noxious stimulus could be administered using formalin; it has been injected in the limb to evaluate efficacy of morphine and pethidine in chelonians.¹⁴²

Opioid and opioid-like drugs: The gene family for opioid receptors (μ , κ , and δ) is highly conserved across multiple vertebrate orders; chelonians seems to have both proencephalon-derived peptides and functional μ - and δ -opioid receptors in the brain.¹⁴³ Initially, butorphanol tartrate was one of the most commonly administered opioid in reptiles, but nowadays, there is no clinical data that report that is an effective analgesic drug in reptiles, so its use has decreased greatly.^{140,127} Morphine is one of the most employed analgesic drugs in chelonians.^{144,145,146,114} It has been proved as an effective analgesic

agent in bearded dragons (1 and 5 mg/kg) and pond sliders (1.5 and 6.5 mg/kg) using the thermal noxious stimulus method;¹⁴¹ similarly, morphine (5, 7.5, 10, and 20 mg/kg) and pethidine (10, 20, and 50 mg/kg) provided analgesia in Speke's hinged tortoises (*Kinixys spekii*) exposed to a noxious formalin stimulus administered into a limb, which was reversible with naloxone treatment.¹⁴² The analgesic effect of fentanyl has just started to be investigated; the drug could be administered IV or transcutaneously using impregnated patch.^{115,147} Tramadol has proved good analgesic effects when administered both orally and intramuscular (better in the hind limbs, with the hepatic first-pass giving higher plasma concentration of its active metabolite O-desmethyl-tramadol), with less deleterious side effects than morphine (e.g. respiratory depression) and elevated plasma concentration up to 48 hours.^{122,148} In loggerhead turtles (*C. caretta*), plasma concentrations of tramadol and M1 remained above the target concentration of ≥ 100 ng/mL for approximately 48 hours at a dose of 5 mg/kg PO and for 72 hours when tramadol was administered at 10 mg/kg PO. Subjectively, appetite, swimming, and general activity levels did not change after drug administration.¹⁴⁹ Buprenorphine seems to not have any effective analgesic effect. In a 2012 study, Mans et al. reported no analgesic effect in red-eared slider turtles exposed to a noxious thermal stimulus. In the same publication, hydromorphone has proved adequate analgesic effect.¹⁵⁰

Local anaesthetic drugs: the use of local anaesthesia has been poorly described in chelonians. Subcutaneous administration of lidocaine in the prefemoral fossa can provide a more complete pain management, but it is not enough to perform prefemoral coeliotomy (and as consequence, celioscopy) without general anaesthesia.^{146,144,151} Intrathecal administration of local anaesthetic drugs at coccygeal level provides regional anaesthesia of the tail, cloaca, urinary bladder, genitalia and hindlimbs, allowing minor surgeries in the caudal body, such as phallectomy.^{139,152} Intrathecal morphine causes antinociception to thermal noxious stimulation of the hind limbs for >24 hours after administration in male red-eared slider turtles.¹³⁹ Intrathecal clonidine causes a significant decrease in the mean time spent in pain-related behaviour in marsh terrapins (*Pelomedusa subrufa*) which were underwent the formalin injection test.¹⁵³ Currently, local anaesthetics are poorly described, but they can probably play a key role in pain management in chelonians and reptiles in general.

Non-steroidal anti-inflammatory drugs: many NSAIDs appear to be relatively safe when used in reptiles, but there are really few reports about their efficacy in this class of animals. A study was published in 2021, regarding pharmacokinetic of meloxicam in three species of sea turtles: loggerheads (*Caretta caretta*), Kemp's ridley (*Lepidochelys kempii*), and greens (*Chelonia mydas*); the dosages were of 1 mg/kg (Kemp's and green) and 2 mg/kg (loggerheads). The authors compared the plasma levels of meloxicam with the therapeutic levels in humans (greater than 0.5 μ g/ml), and they observed that administration of meloxicam SQ at 1 mg/kg in Kemp's ridleys and greens result in plasma concentrations greater than 0.5 μ g/ml for 12 and 120 hr, respectively, and meloxicam SQ at 2 mg/g to loggerhead turtles resulted in plasma concentrations

greater than 0.5 µg/ml for only 4 hr.²¹⁸ Another pharmacokinetic study in *Trachemys scripta* IM, IC and oral administration of meloxicam at 0,2mg/kg were compared; results evidenced a scarce absorption after oral administration compared with the other ways. Furthermore, there is only one published study regarding analgesic efficacy in reptiles; in this study, meloxicam (0.3 mg/kg, IM) was injected in ball pythons (*Python regius*) before a surgical placement of an arterial catheter. They showed no physiologic changes (e.g., heart rate, blood pressure, plasma epinephrine, and cortisol) indicative of analgesia.¹⁵⁴ Currently, considering the few reports available for clinicians, the use of NSAIDs is still mostly anecdotal in reptile species; dosage and efficacy are extrapolated from other species.

Ketamine and α_2 -agonists: analgesic efficacy of ketamine and α_2 -agonist in reptiles is still controversial. Ketamine has an antagonistic effect on N-methyl-D-aspartate (NMDA) receptors and causes the decrease of the windup effect and central sensitisation; low dosages have been proved to provide analgesia in mammals. No report regarding ketamine analgesia in reptiles have been published, and this characteristic is just hypothesised.^{155,156,147} Alpha2-agonist such as medetomidine and dexmedetomidine stimulate central and peripheral α_2 -adrenergic receptors decreasing excitability. Their analgesic efficacy in reptiles is not completely known, but recent works suggest that they can be used for management of painful procedures such as oophorectomy.^{114,147,156,157,158,159,160} The medetomidine-ketamine combination has been researched in chelonians to yield the protocol of medetomidine (0.1 mg/kg) + ketamine (5 mg/kg) IV. The dose was considered as of benefit for minor procedures or for induction to transition over to inhalants. Hypoxia, hypercapnia, hypertension, and bradycardia were documented in chelonians.¹¹⁴

References

1. Di Nicola M.R., Cavignoli L., Luiselli L., Andreone F. (2019). Testuggine palustre siciliana (*Emys trinacris*). In: Di Nicola M.R., Cavignoli L., Luiselli L., Andreone F. (2019). Anfibi e Rettili d'Italia. Edizioni Belvedere. Latina. pg 502-505
2. Pendall I., Schafer H., Fritz U., Wink M. (2008). Isolation of microsatellite markers in the *Emys orbicularis* complex and development of multiplex PCR amplification. Conservation Genetics. DOI: 10.1007/s10592-008-9631-0.
3. Zuffi M.A.L. Di Cerbo A.R., Fritz U. (2011). *Emys orbicularis*. In Corti C., Capula M., Luiselli L., Sindaco R., Razzetti E. (2011). Fauna d'Italia, Vol. XLV, Reptilia. Calderini, Bologna, XII+ pg 869
4. Manferdi T., Bellavista M., Ottonello D., Zuffi M.A.L., Carlino P., Chelazzi G., D'angelo S., Di Tizio L., Fritz U., Lo Valvo M., Marini G., Orrù F., Scali S., Sperone E., Ciofi C. (2013). Analisi preliminari sulla divergenza genetica e filogenetica delle popolazioni italiane della testuggine palustre europea *Emys orbicularis*, Atti II congresso SHI Abruzzo e Molise.

5. Di Nicola M.R., Cavignoli L., Luiselli L., Andreone F. (2019). Testuggine palustre europea (*Emys orbicularis*). In: Di Nicola M.R., Cavignoli L., Luiselli L., Andreone F. (2019). Anfibi e Rettili d'Italia. Edizioni Belvedere. Latina. pg 496-501
6. Rhodin A.G.J., Iverson J.B., Bour R., Fritz U., Georges A., Shaffer H.B., Van Dijk P.P. (2017). *Emys orbicularis* (Linnaeus 1758) European Pond Turtle. In: Rhodin A.G.J., Iverson J.B., Bour R., Fritz U., Georges A., Shaffer H.B., Van Dijk P.P. (2017). Turtles Of The World, Annotated Checklist and Atlas of Taxonomy, Synonymy, Distribution, and Conservation Status (8th Ed.). Chelonian Research Foundation and Turtle Conservancy. pg 72-75
7. Rovcro F., Chelazzi G. (1996). Nesting migrations in a population of the European pond turtle *Emys orbicularis* (L.) (Chelonia: Emydidae) from central Italy. *Ethology, Ecology, Evolution*. Vol. 8. pg 297-304
8. Meeske M. (1997). Nesting behaviour of european pond turtle (*Emys orbicularis*) in south Lithuania. *Acta Zoologica Lituanica*, Vol 7(1). pg 143-150. DOI: 10.1080/13921657.1997.10541430
9. Andreone F., Corti C., Ficetola F., Razzetti E., Romano A., Sindaco R. (2013). *Emys orbicularis* in: <http://www.iucn.it>
10. Kaviani M., Rahimibashar M.R. (2015). Sexual dimorphism of the European Pond Turtle, *Emys orbicularis* (Linnaeus, 1758), in Anzali Lagoon, Iran (Reptilia: Emydidae). *Zoology in Middle East*. Vol 61 (3). pg 231-235. <https://doi.org/10.1080/09397140.2015.1070524>
11. Bull J. J. (1987). Temperature-dependent sex determination in reptiles: validity of sex diagnosis in hatchling lizards. *Canadian Journal of Zoology*. Vol 65. pg 1421–1424
12. Bjorndal K.A., Parsons J., Mustin W., Bolten A.B. (2013). Treshold to maturity in a long-lived reptile: interactions of age, size, and growth. *Marine Biology*. Vol 160, pg 607–616
13. Wibbels T., Owens D.W., Limpus C.J. (2000). Sexing juvenile sea turtles: is there an accurate and practical method? *Chelonian Conservation and Biology*. Vol 3, pg 756–761
14. Pieau C., Dorizzi M., Richard-Mercier N. (2001). Temperature-dependent sex determination and gonadal differentiation in reptiles. In *Genes and Mechanisms in Vertebrate Sex Determination* (eds. Scherer, G. & Schmid, M.). Vol. 91. pg 117–141
15. Miller J. D. (1997). Reproduction in sea turtles. *Biology if Sea Turtle*. Vol 1. pg 51–82
16. Yntema C. L., Mrosovsky N. (1980). Sexual diferentiation in hatchling loggerheads (*Caretta caretta*) incubated at diferent controlled temperatures. *Herpetologica*. pg 33–36
17. Ewert M. A., Etchberger C. R. Nelson C. E. (2004). Turtle sex-determining modes and TSD patterns, and some TSD pattern correlates. *Temp.-Depend. Sex Determ. Vertebr. Smithson. Books Wash. DC* 21–32
18. Ewert M. A., Jackson D. R., Nelson C. E. (1994). Patterns of temperature-dependent sex determination in turtles. *Journal of Experimental Zoology*. Vol 270, pg 3–15
19. Janzen F. J. (1994). Climate change and temperature-dependent sex determination in reptiles. *Proceedings of the National Academy of Sciences*. Vol. 91. pg 7487–7490
20. Valenzuela N., Lieterman R., Neuwald J.L., Mizoguchi B., Iverson J.B., Riley J.L., Lizgus J.D. (2019). Extreme thermal fuctuations from climate change unexpectedly accelerate demographic collapse of vertebrates with temperature-dependent sex determination. *Scientific Reports*. Vol 9. pg 4254

21. Fuentes M., Limpus C., Hamann M., Dawson, J. (2010). Potential impacts of projected sea-level rise on sea turtle rookeries. *Aquatic Conservation of Marine and Freshwater Ecosystems*. Vol 20. pg 132–139
22. Hawkes L., Broderick A., Godfrey M., Godley B. (2020). Climate change and marine turtles. *Endangered Species Research*. Vol 7. pg 137–154
23. Jensen M. P., Allen C.D., Eguchi T., Bell I.P., La Casella E.L., Hilton W.A., Hof C.A.M., Dutton P.H. (2018). Environmental Warming and Feminization of One of the Largest Sea Turtle Populations in the World. *Current Biology*. Vol 28. pg 154–159
24. Girondot M. 1999. Statistical description of temperature-dependent sex determination using maximum likelihood. *Evolutionary Ecology Research*. Vol 1 (3): 479–48
25. Mrosovsky N., Pieau C. (1991). Transitional range of temperature, pivotal temperatures and thermosensitive stages for sex determination in reptiles. *Amphibia-Reptilia*. Vol 12 (2). pg 169–179
26. Hulin V., Girondot M., Godfrey M.H., Guillon J.M. (2008). Mixed and uniform brood sex ratio strategy in turtles: the facts, the theory and their consequences. In: Wyneken J., Bels V. & Godfrey M. H. (Eds). *Biology of turtles*. Chigaco, IL: University Press of Chicago. pg 279–300
27. Pieau C., Dorizzi M. (1981). Determination of temperature sensitive stages for sexual differentiation of the gonads in embryos of the turtle, *Emys orbicularis*. *Journal of Morphology*. Vol 170 (3). pg 373–382
28. Gross T.S., Crain D.A., Bjordal K.A., Bolten A.B., Carthy R.R. (1995). Identification of Sex in Hatchling Loggerhead Turtles (*Caretta caretta*) by Analysis of Steroid Concentrations in Chorioallantoic/Amniotic Fluid. *General and Comparative Endocrinology*, Vol 99, pg 204-210
29. Xia Z.R., Li P.P., Gu H.X., Fong J.J., Zhao E.M. (2011). Evaluating Noninvasive Methods of Sex Identification in Green Sea Turtle (*Chelonia mydas*) Hatchlings. *Chelonian Conservation Biology*, Vol 10, pg 117–123
30. Tezak B., Sifuentes-Romero I., Milton S., Wyneken J. (2021). Identifying Sex of Neonate Turtles with Temperature-dependent Sex Determination via Small Blood Samples. *Scientific Report* Vol 10, pg 5012. <https://doi.org/10.1038/s41598-020-61984-2>
31. Telecky T.M. (2001). United States import and export of live turtles and tortoises. *Turtle and Tortoise Newsletter*, Vol 4, pg 8–13
32. Global Invasive Species Database (2020). Species profile: *Trachemys scripta elegans*, in: <http://www.iucngisd.org/gisd/species.php?sc=71> on 06-11-2020
33. Perez-Santigosa N., Diaz-Paniagua C., Hidalgo-Vila G. (2008). The reproductive ecology of exotic *Trachemys scripta elegans* in an invaded area of southern Europe. *Aquatic Conserv: Mar Freshw Ecosyst* Vol 18, pg 1302–1310
34. Ferri V., Soccini C. (2003). Riproduzione di *Trachemys scripta elegans* in condizioni seminaturali in Lombardia (Italia Settentrionale). *Natura Bresciana* Vol 33, pg 89-92
35. Cadi A., Delmas V., Prevot-Julliard A.C., Joly P., Pieau C., Girondot M. (2004). Successful reproduction of the introduced slider turtle (*Trachemys scripta elegans*) in the South of France. *Aquatic Conservation: Marine and Freshwater Ecosystem* Vol 14. pg 237-246
36. Ficetola G.F., Rödder D., Padoa-Schioppa E. (2012). *Trachemys scripta* (Slider terrapin). In: Francis R.A., *Handbook of global freshwater invasive species*. Earthscan, Abingdon, UK.

37. Vamberger M., Lipovek G., Gregori M. (2012). First reproduction record of *Trachemys scripta* (Schoepff, 1792), in Slovenia. *Herpetozoa* Vol 25(1/2), pg 76-79
38. Kleewein A. (2014). Natural reproduction of *Trachemys scripta troostii* (Holbrook, 1836) x *Trachemys scripta scripta* (Schoepff, 1792) in Austria. *Herpetozoa* Vol 26 (3/4), pg183-185
39. Djordjević S., Andjelković M. (2015). Possible reproduction of the red-eared slider, *Trachemys scripta elegans* (Reptilia: Testudines: Emydidae), in Serbia, under natural conditions. *Hyla* 2015, Vol 1, pg 44-49
40. Di Nicola M.R., Cavignoli L., Luiselli L., Andreone F. (2019). Testuggine palustre americana (*Trachemys scripta*). In: Di Nicola M.R., Cavignoli L., Luiselli L., Andreone F. (2019). *Anfibi e Rettili d'Italia*. Edizioni Belvedere. Latina. pg 506-509
41. Cadi A., Joly P. (2003). Competition for basking places between the endangered Europea pond turtle (*Emys orbicularis galloitalica*) and the introduced red-eared slider (*Trachemys scripta elegans*). *Canadian Journal of Zoology*. Vol 81, pg 1392-1398
42. Cadi A., Joly P. (2004). Impact of the introduction of the red-eared slider (*Trachemys scripta elegans*) on survival rates of the European pond turtle (*Emys orbicularis*). *Biodiversity and Conservation* Vol 13, pg 2511-2518
43. Polo-Cavia N., Lopez P., Martin M. (2010). Competitive interactions during basking between native and invasive freshwater turtle species. *Biological Invasions* Vol 12, pg 2141-2152
44. Polo-Cavia N., Gonzalo A., Lopez P., Martin J. (2010). Predator recognition of native but not invasive turtle predators by naïve anuran tadpoles. *Animal Behavior* Vol 80(3), pg 461-466
45. Polo-Cavia N., Lopez P., Martin M. (2011). Aggressive interactions during feeding between native and invasive freshwater turtle species. *Biological Invasions* Vol 13, pg 1387-1396
46. Pearson S.H., Avery H.W., Spotila J.R. (2015). Juvenile invasive red-eared slider turtles negatively impact the growth of native turtles: Implications for global freshwater turtle populations. *Biology and Conservation* Vol 86, pg 115-121
47. Demkowska-Kutrzepa M, Studzinska M, Roczen-Karczmarz M, Tomczuk K, Abbas Z, Rozanski P. 2018. A review of the helminths co-introduced with *Trachemys scripta elegans* – a threat to European native turtle health. *Amphibia-Reptilia* 39: 177-189.
48. Verneau O, Palacios C, Platt T, Alday M, Billard E, Allienne JF, Basso C, Du Preez LH. 2011. Invasive species threat: parasite phylogenetics reveals patterns and processes of hostswitching between non-native and native captive freshwater turtles. *Parasitol* 138: 1778- 1792.
49. Cardells J, Garijo MM, Marín C, Vega S. 2014. Helminths from the red-eared slider *Trachemys scripta elegans* (Chelonia: Emydidae) in marshes from the eastern Iberian Peninsula: first report of *Telorchis attenuate* (Digenea: Telorchhiidae). *Basic Appl Herpetol* 28: 153-159.
50. Iglesias R, Garcia-Estevez JM, Ayres C, Acuna A, Cordero-Rivera A. 2015. First reported outbreak of severe spirorchhiidiasis in *Emys orbicularis*, probably resulting from a parasite spillover event. *Dis Aquat Organ* 113: 75-80.
51. Lymbery AJ, Morine M, Kanani HG, Beatty SJ, Morgan DL. 2014. Co-invaders: the effects of alien parasites on native hosts. *Int J Parasitol Parasites Wildl* 3: 171-177.

52. Martinez-Silvestre A, Guinea D, Ferrer D, Pantchev N. 2015. Parasitic enteritis associated with the Camallanid Nematode *Serpinema microcephalus* in wild invasive turtles (*Trachemys*, *Pseudemys*, *Graptemys*, and *Ocadia*) in Spain. *J Herpet Med Surg* 25: 48-52
53. Lowe S., Browne M., Boudjelas S., De Poorter M. (2000). 100 of the World's Worst Invasive Alien Species. IUCN/SSC Invasive Species Specialist Group (ISSG), Auckland, New Zealand. http://www.issg.org/pdf/publications/worst_100/english_100_worst.pdf
54. Stuart Thompson J. (2006). *Anatomy of the tortoise* (Bibliomania), United States of America
55. Boyer T.H., Boyer D.M. (2019). *Tortoises, Freshwater Turtles, and Terrapins*. In: Divers S.J., Stahl S.J., Mader's Reptile and Amphibian Medicine and Surgery (third edition). Elsevier Inc., St. Louis, pg 168-179
56. Hnidzo J., Pantchev N. (2011). *Medical Care of Turtles & Tortoises* (Ed. Chimaira), Frankfurt am Main
57. Mc Arthur S., Wilkinson R., Meyer J. (2004). *Anatomy and physiology*, in "Medicine and surgery of tortoises and turtles" (Blackwell Publishing Ltd), Oxford, pg 35-72
58. Sever D.M., Ryan T.J., Morris T., Patton D., Swafford S. (2000). Ultrastructure of the reproductive system of the black swamp snake (*Seminatrix pygaea*); II. Annual oviducal cycle; *Journal of Morphology*, Vol 245, pg 46
59. Bagwill A., Sever D.M., Elsey R.M. (2009). Seasonal variation of the oviduct of the American alligator (*Alligator mississippiensis*), *Journal of Morphology*, Vol 270, pg 702
60. Spadola F., Insacco G. (2009). Endoscopy of cloaca in 51 *Emys trinacris* (Fritz et al., 2005): morphological and diagnostic study. *Acta Herpetologica*, Vol 4(1), pg 73-81
61. Kuchel L.J., Franklin C.E. (2000). Morphology of the cloaca in the estuarine crocodile, *Crocodylus porosus*, and its plastic response to salinity, *Journal of Morphology*, Vol 245, pg 68
62. Crews D (1998). Reptilian reproduction, overview. In: Knobil E., Neil J. D. (1998): *Encyclopedia of reproduction*, Vol. 4, Elsevier, San Diego, pg 254- 265
63. Flachsbartha B., Fritzschea M., Weldon P.J., Schulz S. (2009): Composition of the cloacal gland secretion of tuatara, *Sphenodon punctatus*, *Chemistry and Biodiversity*, Vol 6, pg 1
64. William E., Cooper J.R. (1995). Effect of estrogen and male head coloration of chemosensory investigation of female cloacal pheromones by male broad-headed skinks (*Eumeces laticeps*), *Physiology and Behavior*, Vol 58 (6), pg 1221
65. Mattern D.L., Scott W.D., McDaniel C.A., Weldon P.J., Graves D.E. (1997). Cembrene A and a congeneric ketone isolated from the paracloacal glands of the chinese alligator (*Alligator sinensis*), *Journal of Natural Products*, Vol 60 (8), pg 828
66. Garcia-Rubio S., Attygalle A.B., Weldon P.J., Meinwald J. (2002). Reptilian Chemistry: volatile compounds from paracloacal glands of the American crocodile (*Crocodylus acutus*), *Journal of Chemical Ecology*, Vol 28 (4), pg 769
67. Sever D.M., Ryan T.J., Morris T., Patton D., Swafford S. (2000). Ultrastructure of the reproductive system of the black swamp snake (*Seminatrix pygaea*) II. Annual oviducal cycle; *Journal of Morphology*, Vol 245, pg 46
68. Mathie N.J., Franklin C.E. (2006). The influence of body size on the diving behaviour and physiology of the bimodally respiring turtle (*Elseya albagula*), *Journal of Comparative Physiology*, Vol 176, pg 739.
69. Jackson D.C., Rauer E.M., Feldman R.A., Reese S.A. (2004). *Comparative Biochemistry and Physiology*, Vol 139, pg 221

70. Gordos M.A., Limpus C.J., Franklin C.E. (2006). Response of heart rate and cloacal ventilation in the bimodally respiring freshwater turtle (*Rheodytes leukops*) to experimental changes in aquatic pO₂, *Journal of Comparative Physiology*, Vol 176, pg 65
71. Michele A.J., Wade J. (2011). Neuroendocrinology of reptilian reproductive behaviour, in: *Hormones and Reproduction of Vertebrates, Reptiles*, Vol 3, pg 39-62
72. McPherson R.J., Boots L.R., MacGregor R., Marion K.R. (1982). Plasma steroids associated with seasonal reproductive changes in a multiclutched freshwater turtle, *Sternotherus odoratus*. *General and Comparative Endocrinology*. Vol 48(4). pg 440-451
73. Currylow A.F., Tift M.S., Meyer J.L., Crocker D.E., Williams R.N. (2013). Seasonal variations in plasma vitellogenin and sex steroids in male and female Eastern Box Turtles, *Terrapene carolina carolina*. *General and Comparative Endocrinology*. Vol 180. pg 48-55
74. Shelby J.A., Mendonica M.T., Horne B.D., Seigel R.A. (2000). Seasonal variation in reproductive steroids of male and female yellow-blotched map turtles, *Graptemys flavimaculata*. *General and Comparative Endocrinology*. Vol 119. pg 43-51
75. Blanvillain G., Owens D.W., Kuchling G. (2011). Hormones and Reproductive Cycles in Turtles. In: Norris D.O., Lopez K.H. (Eds.), *Hormones and Reproduction of Vertebrates. Volume 3: Reptiles*. Academic Press, London, UK, pg 277-303
76. Stahl S.J., DeNardo D.F. (2019). Theriogenology. In: Divers SJ, Stahl SJ (Eds.), *Mader's Reptile and Amphibian Medicine and Surgery* (ed 3). Elsevier Inc., St. Louis, pg 849-893
77. Licht P. (1982). Endocrine patterns in the reproductive cycles of turtles. *Herpetologica*. Vol 38. pg 51-61
78. Jones S. (2011). Hormonal Regulation of Ovarian Function in Reptiles. In: Norris D.O., Lopez K.H. (Eds.), *Hormones*
79. Etches R.J., Petitte J.N. (1990). Reptilian and avian follicular hierarchies: models for the study of ovarian development. *Journal of Experimental Zoology*. Vol 4. pg 112-122.
80. Callard I.P., Fileti L., Perez L., Sorbera L., Giannoukos G., Klosterman L., Tsang P., McCracken P. (1992). Role of the corpus luteum and progesterone in the evolution of vertebrate viviparity. *American Zoology*. Vol 32. pg 264-275
81. Ernst C.H., Lovich J.E. (2009). *Turtles of the United States and Canada*, 2nd edition. The John Hopkins University Press, Baltimore, MD, USA
82. Perez-Santigosa N., Diaz-Paniagua C., Hidalgo-Vila G. (2008). The reproductive ecology of exotic *Trachemys scripta elegans* in an invaded area of southern Europe. *Aquatic Conservation: Marine and Freshwater Ecosystem*. Vol 18. pg 1302–1310
83. Schneeweiss N., Steinhauer C. (1996). Habitat use and migrations of a residual population of European pond turtle (*Emys orbicularis orbicularis*) in dependence on landscape structures: International Symposium on Biology, Conservation, Ecology and Systematics of *Emys orbicularis*, 3-6 October 1996. Programme, Abstracts. pg 23-24
84. Jablonski A., Jablonska S. (1996). Egg-laying of the European pond turtle, *Emys orbicularis* (L.), in LeczynskoWłodawskie Lake District (Eastern Poland). International Symposium on Biology, Conservation, Ecology and Systematics of *Emys orbicularis*, 3-6 October 1996, Programme & Abstracts. pg 19

85. Zemanek M. (1990). Endangerment of European Pond Tortoise in Poland and causes of its decline. The protection of the plant and animal species. International Scientific Seminary, CMENIUCN. pg 337-347
86. Fritz U., Gunther R. (1996). Europäische Sumpfschildkröte - *Emys orbicularis* (Linnaeus, 1758). In: Gunther R. (publisher): Die Amphibien und Reptilien Deutschlands. Published by Gustav Fischer, Jena. pg 518-534
87. Congdon J.D., Tinkle D.W., Breitenbach G.L., R.C. van Loben Sels (1983). Nesting Ecology and Hatching Success in the Turtle *Emydoidea blandingii*. Herpetologica. Vol 39(4). pg 417-429
88. Loncke D.J., Obhard M.E. (1977). Tag Success, Dimensions, Clutch Size and Nesting Fidelity for the Snapping-Turtle *Chelydra serpentina* (Reptilia, Testudines, Chelydridae) in Algonquin Park, Canada. Journal of Herpetology. Vol 11(2). pg 243-244
89. Gibbons J.W., Greene J.L., Patterson K.K. (1982). Variation in reproductive characteristics of aquatic turtles. Copeia. Vol 1982. pg 776-784
90. Congdon J.D., Gibbons J.W. (1985). Egg components and reproductive characteristics of turtles: relationships to body size. Herpetologica. Vol 41. pg 194-205.
91. Gibbons J.W., Nelson D.H. (1978). The evolutionary significance of delayed emergence from the nest of hatchling turtles. Evolution. Vol 32. pg 297-303.
92. Fleming A., Crews D. (2001). Oestradiol and incubation temperature modulate regulation of Steroidogenic Factor 1 in the developing gonad of the red-eared slider. Endocrinology. Vol 142. pg 1403- 1411
93. Hernandez-Divers S.J. (2010). Endoscopy Equipment and Instrumentation for Use in Exotic Animal Medicine, Journal of Veterinary Clinics Exotic Animal Practice, vol 13, pg 171–185
94. Hernandez-Divers S.J. (2011). Rigid Endoscopy in Exotic Companion Animals: a New Era in Minimally Invasive Diagnostics and Surgery. North America Veterinary Clinics Conference, pg 1695-1699
95. Capello V., Lennox A.M. (2011). Diagnostic Imaging of the Respiratory System in Exotic Companion Mammals. Journal of Veterinary Clinics Exotic Animal Practice. Vol 14. pg 369–389
96. Hernandez-Divers S.J. (2008). Clinical Technique: Dental Endoscopy of Rabbits and Rodents. Journal of Exotic Pet Medicine. Vol 17(2). pg 87–92 5)
97. Hernandez-Divers S.J., Stahl S.J., Camus A. (2010). Evaluation of diagnostic coelioscopy including liver and kidney biopsy in freshwater turtles (*Trachemys scripta*). Journal of Zoo and Wildlife Medicine. Vol 41. pg 677–687.
98. Hernandez-Divers S.J. (2019). Diagnostic Endoscopy. In: Hernandez-Divers S.J., Stahl S.J. (Eds.), Mader's Reptile and Amphibian Medicine and Surgery (Third edition). Elsevier Inc.. St. Louis. pg 604-614
99. Hernandez-Divers S.J. (2015). Making the difference in Exotic Animal Practice: the Value of Endoscopy. Journal of Veterinary Clinics Exotic Animal Practice
100. Hernandez-Divers S.J., Hernandez-Divers S.M., Wilson H.G., Stahl S.J. (2005). A review of Reptile Diagnostic Coelioscopy. Journal of Herpetological Medicine and Surgery. Vol 15(3). pg 16–31
101. Hernandez-Divers S.J., Stahl S.J., Stedman N.L., Hanley C.S., Wilson H.G., Vidyashankar A.N., Zhao Y., Rumbelha W.K.. (2005) Renal Evaluation in the Healthy Green Iguana (*Iguana iguana*): Assessment of Plasma Biochemistry, Glomerular Filtration Rate, and Endoscopic Biopsy. Journal of Zoo and Wildlife Medicine. Vol 36(2). pg 155–168

102. Hernandez-Divers S.J. (2015). Endoscopic Sex Identification in Chelonians and Birds (Psittacines, Passerines, and Raptors). *Veterinary Clinics Exotic Animal Practice*. Vol 18. pg 541–554
103. Hernandez-Divers S.J., Stahl S.J., Hernandez-Divers S.M., Read M.R., Hanley C.S., Martinez F., Cooper T.L. (2004). Coelomic Endoscopy of the Green Iguana, *Iguana iguana*. *Journal of Herpetological Medicine and Surgery*. Vol 14(1). pg 10–18
104. Hernandez-Divers S.J. (2006). Reptile Diagnostic Coelioscopy: a Means to a Definitive Diagnosis, 35 North America Veterinary Clinics Conference, pg 1619–1623
105. Hernandez-Divers S.J. (2019). Diagnostic and Surgical Endoscopy. In S. J. Girling, P. Raiti (Ed.), *BSAVA Manual of Reptiles* (3rd Ed). BSAVA. pg 160–175
106. Jekl V., Knotek Z. (2006). Endoscopic Examination of Snakes by Access through an Air Sac. *The Veterinary Record*. Vol 158. pg 407–410
107. Knotek Z., Jekll V., Moricci M., Spadola F. (2015) Cloacoscopy as a feasible Method of Health Management for Chelonians. *Worlds Small Animals Veterinary Association World Congress Proceedings*
108. Spadola F., Morici M., Oliveri M., Knotek Z. (2016). Description of cloacoscopy in the loggerhead sea turtle (*Caretta caretta*). *Acta Veterinaria BRNO*. Vol 85. pg 367-370
109. Knotek Z., Jekll V., Knotkova Z., Grabensteiner E. (2009). Eggs in Chelonian Urinary Bladder: in Coeliotomy Necessary?. *Proceedings Association of Reptilian and Amphibian Veterinarians*. pg 118–121
110. Selleri P., Di Girolamo N., Melidone R. (2013). Cystoscopic sex identification of posthatchling chelonians. *Journal of American Veterinary Medical Association*. Vol 242(12). pg 1744–1750
111. Di Girolamo N., Selleri P. (2015). Clinical Applications of Cystoscopy in Chelonians. *Journal of Veterinary Clinics Exotic Animal Practice*. Vol 18. pg 507–526
112. Martinez-Silvestre A., Bargallò F., Grifols J. (2015). Gender Identification by Cloacoscopy and Cystoscopy in Juvenile Chelonians. *Journal of Veterinary Clinics Exotic Animal Practice*. Vol 18(3), pp 1-13
113. Mans C., Sladky K. K. (2012). Endoscopically guided removal of cloacal calculi in three African spurred tortoises (*Geochelone sulcata*). *Journal of American Veterinary Medical Association*. Vol 240(7). pg 869–875
114. Jablonski A., Jablonska S. (1996). Egg-laying of the European pond turtle, *Emys orbicularis* (L.), in LeczynskoWlodawskie Lake District (Eastern Poland). *International Symposium on Biology, Conservation, Ecology and Systematics of Emys orbicularis*, 3-6 October 1996, Programme & Abstracts. pg 19
115. Zemanek M. (1990). Endangerment of European Pond Tortoise in Poland and causes of its decline. The protection of the plant and animal species. *International Scientific Seminary, CMENIUCN*. pg 337-347
116. Fritz U., Gunther R. (1996). Europäische Sumpfschildkröte - *Emys orbicularis* (Linnaeus, 1758). In: Gunther R. (publisher): *Die Amphibien und Reptilien Deutschlands*. Published by Gustav Fischer, Jena. pg 518-534
117. Meeske M. (1997). Nesting behaviour of european pond turtle (*Emys orbicularis*) in south Lithuania. *Acta Zoologica Lituanica*, Vol 7(1). pg 143-150. DOI: 10.1080/13921657.1997.10541430
118. Murray M. M. (2006). Cardiopulmonary anatomy and physiology. In D. Mader (Ed.), *Reptile Medicine and Surgery*. St. Louis, MO, Saunders/Elsevier. pg 124-128
119. O'Malley, B. (2005). Tortoises and turtles. In B. O'Malley (Ed.), *Clinical Anatomy and Physiology of Exotic Species*. Philadelphia, PA, Elsevier/Saunders. pg 41-56

120. Holz P., Barker I. K., Burger J. P., Crawshaw G. J., Conlon P. D. (1997). The effect of the renal portal system on pharmacokinetic parameters in the red-eared slider (*Trachemys scripta elegans*). *Journal of Zoo and Wildlife Medicine*. Vol 28(4). pg 386-393
121. Holz P., Raidal, S. (2006). Comparative Renal Anatomy of Exotic Species. *Veterinary Clinics of North America: Exotic Animal Practice*, Vol 9(1)
122. Giorgi M., Salvadori M., De Vito V., Owen H., Demontis M. P., Varoni M. V. (2015). Pharmacokinetic/pharmacodynamic assessments of 10 mg/kg tramadol intramuscular injection in yellow-bellied slider turtles (*Trachemys scripta scripta*). *Journal of Veterinary Pharmacology and Therapeutics*. Vol 38(5). pg 488-496
123. Lahner L., Mans C., Sladky K. K. (2011). Comparison of anesthetic induction and recovery times after intramuscular, subcutaneous or intranasal dexmedetomidine-ketamine administration in redeared slider turtles (*Trachemys scripta elegans*). *Proceedings of AAZV Conference*, pg 136-137
124. Kummrow M.S., Tseng F., Hesse L., Court M. (2008). Pharmacokinetics of buprenorphine after single-dose subcutaneous administration in red-eared sliders (*Trachemys scripta elegans*). *Journal of Zoo Wildlife Medicine*. Vol 39. pg 590-595
125. Hicks J.W. (2003). The physiological and evolutionary significance of cardiovascular shunting patterns in reptiles. *News in Physiological Science*. Vol 17. pg 241-245.
126. Greunz E.M., Williams C., Ringgaard S., Hansen K., Wang T., Bertelsen M.F. (2018). Elimination of Intracardiac Shunting Provides Stable Gas Anesthesia in Tortoises. *Scientific Report*. Vol 8(17124) DOI:10.1038/s41598-018-35588-w
127. Sladky K.K., Miletic V., Paul-Murphy J., Kinney M.E., Dallwig R.K., Johnson S.M. (2007). Analgesic efficacy and respiratory effects of butorphanol and morphine in turtles. *Journal of American Veterinary Medicine Association*. Vol 230. pg 1356–62.
128. Harms C.A., Eckert S.A., Kubis S.A., Campbel M., Levenson D.H., Crognale M.A. (2007). Field anaesthesia of leatherback sea turtles (*Dermochelys coriacea*). *Veterinary Records*. Vol 161(1). pg 15–21
129. Dennis P.M., Heard D.J. (2002). Cardiopulmonary effects of a medetomidine-ketamine combination administered intravenously in gopher tortoises. *Journal of American Veterinary Medicine Association*. Vol 220(10). pg 1516–1519
130. Greer L.L., Jenne K.J., Diggs H.E (2001). Medetomidine-ketamine anesthesia in red-eared slider turtles (*Trachemys scripta elegans*). *Contemporary Topics in Laboratory Animal Science*. Vol 40(3). pg 9–11
131. Rostal D., Grumbles J., Lance V., Spotila J.R. (1994). Non-lethal sexing techniques for hatchling and immature desert tortoises (*Gopherus agassizii*). *Herpetological Monograph*. Vol 8. pg 103–16
132. Hernandez-Divers S.J., Stahl S.J., Farrell R. (2009). Endoscopic gender identification of hatchling Chinese box turtles (*Cuora flavomarginata*) under local and general anesthesia. *Journal of American Veterinary Medicine Association*. Vol 234(6). pg 800–804
133. Schumacher J., Yellen T. (2006). Anesthesia and analgesia. In: Mader DR, editor. *Reptile medicine and surgery*. 2nd edition. St Louis (MO). Saunders-Elsevier. 2006. pg 442–452

134. Hansen L.L, Bertelsen M.F. (2013). Assessment of the effects of intramuscular administration of alfaxalone with and without medetomidine in Horsfield's tortoises (*Agrionemys horsfieldii*). *Veterinary Anaesthesia and Analgesia*. Vol 40. pg 68-75
135. Minter L.J., Landry M.M., Lewbart G.A. (2008). Prophylactic ovariosalpingectomy using a prefemoral approach in eastern box turtles (*Terrapene carolina carolina*). *Veterinary Records*. Vol 163(16). pg 487-488
136. Mans C., Sladky K.K. (2012). Diagnosis and management of oviductal disease in three red-eared slider turtles (*Trachemys scripta elegans*). *Journal of Small Animal Practice*. Vol 53. pg 234–239
137. Takami Y. (2017). Single-incision, prefemoral oophorosalingectomy without coelioscopy in an Indian star tortoise (*Geochelone elegans*) with follicular stasis. *Journal of Veterinary Medical Science* Vol 79(19). pg 1675-1677
138. Paries S., Funke S., Ziegler L., Lierz M., Wüst E. (2014). Endoscopic assisted orchietomy in Herman's tortoises (*Testudo hermanni* sp.). *Tierärztl Prax*. Vol 42(K). pg 383–389
139. Mans C. (2014). Intrathecal drug administration in turtles and tortoises. *Journal of Exotic Pet Medicine*. Vol 23(1). pg 67-70
140. Kinney M.E., Johnson S.M., Sladky K.K. (2011). Behavioral evaluation of red-eared slider turtles (*Trachemys scripta elegans*) administered either morphine or butorphanol following unilateral gonadectomy. *Journal of Herpetological Medicine and Surgery*. Vol 21 pg 54-62
141. Sladky K.K., Kinney M.E., Johnson S.M. (2009). Effects of opioid receptor activation on thermal antinociception in red-eared slider turtles (*Trachemys scripta*). *American Journal of Veterinary Research*. Vol 70(9). pg 1072-1078
142. Wambugu S.M., Towett P.K., Kiama S.G., Abelson K.S.P., Kanui T.I. (2010). Effects of opioids in the formalin test in the Speke's hinged tortoise (*Kinixys spekii*). *Journal of Veterinary Pharmacology and Therapeutics*. Vol 33. pg 347-351
143. Reiner A., Brauth S.E., Kitt C.A., Quirion R. (1989). Distribution of mu, delta, and kappa opiate receptor types in the forebrain and midbrain of pigeons. *Journal of Comparative Neurology*. Vol 280 pg 359–382
144. Hatt J.M., Kummrow M., Wenger S., Clauss M. (2019). Orchietomy in *Testudo* species: technical aspects and effects on courtship behavior. *Veterinary Records*. Vol 184(18). pg 555
145. Innis C.J., Feinsod R., Hanlon J., Stahl S.J., Oguni J., Boone S., Schnellbacher R., Cavin J., Divers S.J. (2013). Coelioscopic orchietomy can be effectively and safely accomplished in chelonians. *Veterinary Records*. Vol 172(20). pg 526-531
146. Proença L.M., Fowler S., Kleine S., Quandt J., Mullen C.O., Divers S.J. (2014). Single surgeon coelioscopic orchietomy of desert tortoises (*Gopherus agassizii*) for population management. *Veterinary Records*. Vol 175(16). pg 404-409
147. Kahrbusch R.J., Gutwillig A., Hartzler K.E., Kimyon R.S., Gardner A.N., Abbott A.D., Cox S.K., Watters J.J., Sladky K.K., Johnson S.M. (2017). Antinociceptive and respiratory effects following application of transdermal fentanyl patches and assessment of brain μ -opioid receptor mRNA expression in ball pythons. *American Journal of Veterinary Research*. Vol 78. pg 785-795
148. Baker B.B., Sladky K.K., Johnson S.M. (2011). Evaluation of the analgesic effects of oral and subcutaneous tramadol administration in red-eared slider turtles. *Journal of American Veterinary Medicine Association*. Vol 238(2). pg 220-227

149. Norton T.M., Cox S., Nelson S.E. Jr, Kaylor M., Thomas R., Hupp A., Sladky K.K. (2015). Pharmacokinetics of tramadol and o-desmethyltramadol in loggerhead sea turtles (*Caretta caretta*). *Journal of Zoo and Wildlife Medicine*. Vol 46. pg 262-265
150. Mans C., Lahner L.L., Baker B.B., Johnson S.M., Sladky K.K. (2012). Antinociceptive efficacy of buprenorphine and hydromorphone in red-eared slider turtles (*Trachemys scripta elegans*). *Journal of Zoo and Wildlife Medicine*. Vol 43(3). pg 662-665
151. Knafo S.E., Divers S.J., Rivera S., Cayot L.J., Tapia-Aguilera W., Flanagan J. (2011). Sterilization of hybrid Galapagos tortoises (*Geochelone nigra*) for island restoration. Part 1: endoscopic oophorectomy of females under ketamine-medetomidine anaesthesia. *Veterinary Records*. Vol 168. pg 47-51
152. Rivera S., Divers S.J., Knafo S.E., Martinez P., Kayot L.J., Tapia-Aguilera W., Flanagan J. (2011). Sterilization of hybrid Galapagos tortoises (*Geochelone nigra*) for island restoration. Part 2: phallectomy of males under intrathecal anaesthesia with lidocaine. *Veterinary Records*. Vol 168. pg 78
153. Makau C.M., Towett P.K., Abelson K.S.P., Kanui T.I. (2014). Intrathecal administration of clonidine or yohimbine decreases the nociceptive behavior caused by formalin injection in the marsh terrapin (*Pelomedusa subrufa*). *Brain Behaviour*. Vol 4(6). pg 850-857
154. Olesen M.G., Bertelsen M.F., Perry S.F., Wang T. Effects of preoperative administration of butorphanol or meloxicam on physiologic responses to surgery in ball pythons. *Journal of American Veterinary Medicine Association*. Vol 233(12). pg 1883-1888
155. Schmid R.L., Sandler A.N., Katz J. (1999). Use and efficacy of low-dose ketamine in the management of acute postoperative pain: a review of current techniques and outcomes. *Pain*. Vol 82, pg 111–125
156. Allweiler S.I. (2016). How to improve anesthesia and analgesia in small mammals. *Veterinary Clinic of Exotic Animals*. Vol 19. pg 361-377
157. Bochmann M., Wenger S., Hatt J.M. (2018). Preliminary Clinical Comparison of Anesthesia with Ketamine/Medetomidine and S-Ketamine/Medetomidine in *Testudo* spp. *Journal of Herpetological Medicine and Surgery*. Vol 28(1-2). pg 40-46.
158. Bunke L.G., Sladky K.K., Johnson S.M. (2018). Antinociceptive efficacy and respiratory effects of dexmedetomidine in ball pythons (*Python regius*). *American Journal of Veterinary Research*. Vol 79. pg 718–726
159. Perry S.M., Nevarez J.G. (2018). Pain and Its Control in Reptiles. *Veterinary Clinic of Exotic Animal*. Vol 21. pg 1-16.
160. Cavaretta M.A. (2019). Dexmedetomidine. *Journal of Exotic Pet Medicine*. Vol 29. pg 27-31

Aim of the study

The aim of the present PhD project was to identify the best endoscopic solution to evaluate sex in European pond turtle (*E. orbicularis*) and, furthermore, in other reptile species.

The first aim was to compare different endoscopic sexing approaches, which are: direct visualisation by coelioscopy, transvesical by cystoscopy, direct and indirect by cloacoscopy. These approaches were studied mainly in chelonians, in particular in those species which are threatened, but also in other reptiles species.

The second aim was to study the various endoscopic sexing approaches, trying to identify the best landmarks for each one to obtain sex determination in the shortest possible time with less invasiveness for the animal.

The third aim of the study was to standardise the cloaco-cystoscopic anatomy of the chelonian species, with particular attention to Italian species (*T. hermanni* and *Emys orbicularis*). To better understand the potentiality and limits of this method, especially in cloacal and genital areas; to compare it to other standard diagnostic methods, which are already studied and standardised, and to coelioscopy, which is more studied and, currently, represents the gold standard endoscopic technique for internal organs.

The last aim was to compare different anaesthetic protocols and to study efficacy of new drugs and new anaesthetic techniques on chelonians and threatened reptiles. The anaesthetic protocol should provide quick induction and recovery time in order to better explain the endoscopic procedure; in particular, different methods of general anaesthesia will be evaluated, in order to perform coelioscopy, and different methods of locoregional anesthesia, in order to obtain a correct analgesia and muscle relaxation to perform cloaco-cystoscopy.

In association with these studies, the candidate aimed to collaborate with conservation programs in order to preserve autochthonous species (e.g. *E. orbicularis* and *T. hermanni*) and to control invasive species (e.g. *Trachemys scripta*).

Chapter 2 – Research studies

Chapter 2.1 Cloacoscopic/cistosopic sex determination

Herpetological bulletin, 2021, Vol 156, pp. 11-13

Cloacal anatomical description and sex determination in *Tiliqua* sp.

SPADOLA F.¹; SGROI P.²; LUBIAN E.^{1,4} & MORICI M.³

¹ Veterinary Teaching Hospital, Department of Veterinary Science, University of Messina, Polo Didattico
Annunziata 98168 Messina, Italy,

² Istituto veterinario di Novara, 28060 Granozzo con Monticello, Italy

³ Pombia Safari Park, Via Larino 3, 28050 Pombia, Italy,

⁴ Ospedale Veterinario Universitario Piccoli Animali, Università degli Studi di Milano, 26900, Lodi, Italy

Corresponding Author:

Emanuele Lubian

Email: emanuele.lubian@hotmail.com

ABSTRACT - Cloacoscopy represents a useful endoscopic technique for direct evaluation of the anatomical structures of the cloaca. The study was performed on an adult reproductive couple of *Tiliqua gigas gigas*, and on a specimen of *Tiliqua gigas evanescens* and *Tiliqua* sp. (Irian Jaya form). The endoscopic investigation of the cloaca was made using a rigid endoscope. During cloacoscopic investigation of the reproductive pair of *T. gigas gigas*, it was possible to highlight the anatomical differences of the two sexes. Similar differences between males and females have been identified in the two specimens, not already sexed, of *T. gigas evanescens* and *T. sp.* Irian Jaya. Throughout the procedure the animals did not show any a sign of stress from being handled. Female specimens show double pair of urodeal papillae (ureteral and vaginal papillae), whereas male specimens show just a single pair (ureteral). In the genus *Tiliqua*, considering the lack of an evident sexual dimorphism, the sexing technique based on the morphological characteristics of the two sexes is quite complex. The morphological differences that characterize the two sexes can be evaluated with extreme accuracy via cloacoscopy.

INTRODUCTION

Cloacoscopy represents a useful endoscopic technique for direct evaluation of the anatomical structures of the cloaca. Although the first description of endoscopy applied to reptile species was published in 1983 (Wood et al., 1983), it is just in the last few years that endoscopy has become common in routine clinical practice. Endoscopy allows direct evaluation of different apparatus: normal procedures adopted are laparoscopy and coeloscopy (Schildger et al., 1999; Murray, 2000; Taylor, 2006), but other minimally invasive procedures such as gastroscopy, the assessment of the upper respiratory system, and cloacoscopy are now also routinely performed (Schumacher, 2011; Knotek & Jekl, 2015, Spadola et al., 2009). Endoscopy is one of the safest methods to describe cloacal structures (Divers, 2014, 2015; Martínez-Silvestre et al., 2015; Oliveri et al, 2016; Spadola et al., 2009); the use of a rigid endoscope, supported by warm saline irrigation, promotes direct visualization of proctodeum, urodeum, and coprodeum. Still, the evaluation of all cloacal structures is not always easy, due to the lack of detailed information on most of the more than 11,000 species of reptiles (Stahl, 2006; Spadola et al., 2009; Reptile database, 2020). For this reason, the purpose of this study is to describe the anatomical structures of the cloaca in genus *Tiliqua* (Figure 3) in specimens of both sexes, lending particular attention to urodeum and reproductive structures, in order to obtain a detailed description of the cloaca of males and females. The obtained information can be used for subsequent clinical comparisons or for the determination of sex.

MATERIALS AND METHODS

The first part of the study was performed on an adult reproductive couple of *Tiliqua gigas gigas* (3 years old), while the second was performed on a specimen of *Tiliqua gigas evanescens* and *Tiliqua* sp. (Irian Jaya form) - 5 years old and without demonstrable age but in Italy for 3 years, respectively. The animals were checked at Messina University Veterinary Teaching Hospital and Pombia Safari Park in order to perform routine examination on the reproductive system for breeding purposes. After a careful clinical examination, good health condition of the animals was confirmed and the inspection of the cloacal region was performed. The animals were therefore positioned in a dorsal recumbency on an operator table (equipped with a heating mat) and contained manually (Fig. 1). The endoscopic investigation of the cloaca was made using a rigid endoscope of

4mm diameter and 0° optic inclination, connected to a Telecam DX camera II—all of which was in turn connected to an all-in-one Karl Storz "TELE PACKTM" system, thus ensuring a light source and video control. During the procedure, a continuous cloacal washing was provided, obtained with a 60ml syringe filled with warm saline solution (NaCl 0,9%) connected to the endoscope, in order to expand the cloacal chambers and display all the structures. After the diagnostic examination, all the animals were hospitalized and monitored for 24h. Both the cloacoscopic technique and the data acquisition have been carried out as routine clinical practice to investigate reptile health status, with the owners' permissions, and with all ethically approved clinical procedures.

RESULTS

During cloacoscopic investigation of the reproductive pair of *T. gigas gigas*, it was possible to highlight the anatomical differences of the two sexes. Similar differences between males and females have been identified in the two specimens, not yet sexed, of *T. gigas evanescens* and *T. sp.* Irian Jaya. Throughout the procedure the animals did not show any a sign of stress from handling; the entire procedure takes about five minutes for every specimen and it is reported as a non-risky procedure for reptiles. For that reason and considering the risk of anaesthesia in reptiles compared to mammals, we didn't perform any sedation, as already reported for cloacoscopy in other reptile species (Perpiñán, 2018; Morici et al., 2017; Divers, 2014).

Females

One of the *T. gigas gigas* and the *T. gigas evanescens* were identified as females. The insertion of the endoscope through the cloacal opening allowed to take a first look at the anatomical region of the proctodeum. Proceeding in cranially and dilating the walls by irrigation with saline solution, it was possible to have a general display of the anatomical structures of urodeum and coprodeum and their relationships. Overcoming the envelope between coprodeum and urodeum, it was possible to visualize the urodeum; this looked like a blind-bottom cavity whose wall presented four papillary structures, arranged in parallel and divided by a median crest. These structures correspond to the ureteral papillae (more caudally) and the vaginal papillae (bit cranially to the ureteral papillae), respectively (Fig. 2). It wasn't possible to see any structure attributable to the urethral ostium. Considering that presence of urinary bladder is reported in these species (Beuchat CA, 1986), this could suggest the presence of a rudimentary bladder with vestigial urethra, or differences between species of the genus *Tiliqua* not yet

anatomically described. A visual analysis of the coprodeum was carried on by slightly downgrading the endoscope; the coprodeum was reached after having deflected the probe in a cranial direction, and after having overcome the anal sphincter via washing with saline solution. It was possible to observe the rectal ampulla and, cranially, the rectal colic valve; this allowed to carry out a visual investigation of the caudal portion of the rectal canal. Furthermore, in this area, the presence of uric acid as a white pulp mass was identified in both investigated animals. The passage of the aforementioned pulp was also documented from the ureteral ostium to the rectum, after cloacal contraction: this mechanism is typical of ophidians and saurians without bladder.

Males

One of the *T. gigas gigas* and the *T. sp.* Irian Jaya were identified as males. The subjects were checked and assessed as in good health condition, then the endoscopic investigation was performed. The animals were readied and contained in the same way as in the previous case, and with the same endoscopic parameters. During the introduction of the endoscopic probe, it was possible to view the proctodeum; urodeum and coprodeum appeared in the same arrangement of females and, as in females, it was possible to dilate the urodeum by proceeding dorsally. This area presented a single pair of papillae divided by a median crest, which can confirm the gender as male (Fig. 3). During the visualization of the structures in the urodeum it was possible to observe, as mentioned in females, the sequence of events that affect uric acid excretion and its conveyance through the anal sphincter in coprodeum, preceded by cloacal contractions (Fig. 4).

Neither couple had ever bred before (also due to them being bred separately in both cases) and sex differences was confirmed because both couples started breeding successfully during the next year. Breeding behavior confirmed the sex. Moreover, the endoscopic visualization of the papillae can highlight the different anatomy of both genders, already described in several anatomical reports (Fox, 1977; Trauth et al., 1987; Vitt & Caldwell, 2009)

DISCUSSION

In the genus *Tiliqua*, considering the lack of an evident sexual dimorphism, the sexing technique based on the morphological characteristics of the two sexes is quite complex. The morphological differences that characterize

the two sexes can be evaluated with extreme accuracy via cloacoscopy. In the cloacoscopic survey of species *T. gigas gigas*, *T. gigas evanescens* and *T.sp "Irian Jaya"* have been identified as unequivocally female subjects, highlighting the presence of an evident median crest and vaginal papillae at urodeum level: these are appreciable as papillariform structures placed on the dorsal wall of the urodeum, cranially to the ureteral papillae. Sex determination by cloacoscopy therefore guarantees high percentage of success, thanks to the direct highlighting of the anatomical structures that are unequivocally attributed to the two sexes.

The presence in this survey of just four animals, belonging to three different subspecies, is a limit that should be overcome with other surveys on the same topic. The comparison with the experience obtained from the cloacoscopic study in the species *Salvator merianae* (Morici et al., 2017) made it possible to understand the data of this diagnostic technique. This survey represents the only one world example of cloacoscopy performed on specimens of the genus *Tiliqua*, probably ascribable to the Scincidae family. The cloacal anatomy and the cloacal differences between two sexes have already been described (Fox, 1977; Trauth et al., 1987; Vitt & Caldwell, 2009); with this survey we demonstrate the possibility to also appreciate the difference in live animals, rather than just from a post-mortem examination. As a consequence of the small animal number, we cannot exclude intra- and extra-specific anatomical variability, although single or double pairs of papillae should be present.

Cloacoscopy is a minimally invasive technique, so no sedation is required, and it allows to evaluate with good accuracy the cloaca as well as numerous pathologies in these animals (Rivera, 2008; Spadola & Insacco, 2009; Divers, 2014). Indeed, the use of exploratory cloacoscopy in reptiles allows to diagnose numerous and common pathologies, such as cryptosporidiosis or oviductites (Mans, 2013, Scullion & Scullion, 2009; Sykes, 2010). Furthermore, the use of cloacoscopy can be adopted for minimally invasive surgical procedures (Mehler, 2011) of the gastrointestinal and urinary systems, such as removing cloacal calculus (Mans & Sladky, 2012a) or intestinal fecalomas (Mans & Sladky, 2012b), obviating long post-operative periods and copious blood loss (Frye, 1972). Moreover, thanks to cloacoscopy, the vaginal canals of the *Tiliqua* species could be explored in order to perform assisted insemination to increase chances of fertilization, as reported in ophidians (Knotec et al., 2017; Oliveri et al., 2018). This procedure can open different horizons in the field of conservation medicine,

which wants to make use of assisted fertilization to easily obtain new individuals to reintroduce in nature. As mentioned, several assisted reproduction techniques have already been studied in snakes (Quinn et al., 1989; Fahrig et al., 2007; Mattson et al., 2007; Zacariotti et al., 2007), representing a starting point for developing an artificial cloacoscopic insemination technique in many other species.

To conclude, we can state that cloacoscopy can be considered an accurate, safe and minimally invasive method, extremely effective for direct exploration of the cloaca of the reptiles in the study, useful during the clinical examination and an essential sexing method. It can be also a valid support for those species characterized by breeding and conservation programs, giving excellent prospects for artificial insemination in Lepidosauria.

REFERENCES

- Beuchat, C.A. (1986). Phylogenetic distribution of the urinary bladder in lizards. *American Society of Ichthyologists and Herpetologists (ASIH) 2*: 512-517.
- Divers, S.J. (2019). Diagnostic Endoscopy. In: *Reptiles and Amphibians Medicine and Surgery*, 605-614, Douglas R. Mader III Edition, Elsevier
- Fahrig, B.M., Mitchell, M.A. & Eilts, B.E. (2007). Characterization and cooled storage of semen from corn snakes (*Elaphe guttata*). *Journal of Zoo and Wildlife Medicine 38*: 7–12.
- Fox A. (1977). The urogenital system of reptiles. In: *Biology of the reptilia*, 6:1-157, Gans C., Parson T.S., Academic Press.
- Frye, F.L. (1972). Surgical removal of a cystic calculus from a desert tortoise. *Journal of American Veterinary Medicine Association Sep 15*, 161(6): 600-602.
- Gartrell, B.D., Girling, J.E., Edwards, A. & Jones, S.M. (2002). Comparison of noninvasive methods for the evaluation of female reproductive condition in a large viviparous lizard. *Tiliqua nigrolutea. Zoo Biology 21*(3): 253-268.
- Knotek, Z., Jekl, V. (2015). Pulmonoscopy of Snakes. *Veterinary Clinics: Exotic Animal Practice 18*(3): 493-506.
- Knotek, Z., Cermakova, E. & Oliveri, M. (2017). Reproductive medicine in lizards. *Veterinary Clinics: Exotic Animal Practice 20*(2): 411-438.

- Mans, C. & Sladky, K.K. (2012). Diagnosis and management of oviductal disease in three red-eared slider turtles (*Trachemys scripta elegans*). *Journal of Small Animal Practice* 53: 234–239.
- Martínez-Silvestre, A., Bargalló, F. & Grífols, J. (2015). Gender identification by cloacoscopy and cystoscopy in juvenile chelonians. *Veterinary Clinics: Exotic Animal Practice* 18(3): 527-539.
- Mattson K.J., De Vries A. & McGuire S.M. (2007). Successful artificial insemination in the corn snake, *Elaphe guttata*, using fresh and cooled semen. *Zoo Biology* 26: 363–369.
- Mehler S.J. (2011). Minimally Invasive Surgery Techniques. *Exotic Animals Journal of Exotic Pet Medicine* 20 (3): 188 –205.
- Morici M., Di Giuseppe M., Oliveri M., Knotek Z. & Spadola F. (2017). Cloacoscopic sex determination in Tegulizards. *Proceedings of Venice Icare* 2017: 544-545.
- Murray, M.J. (2000). Endoscopy. *Seminars in Avian and Exotic Pet Medicine* 9 (4): 225-233.
- Oliveri, M., Morici, M., Novotný, R., Bartošková, A. & Knotek, Z. (2016). Cloacoscopy in the Horned Viper (*Vipera ammodytes*). *Acta Veterinaria Brno* 85(3): 251-253.
- Oliveri, M., Bartoskova, A., Spadola, F., Morici, M., Di Giuseppe, M. & Knotek, Z. (2018). Method of Semen Collection and Artificial Insemination in Snakes. *Journal of Exotic Pet Medicine* 27: 75-80
- Perpiñán, D. (2018). Reptile anaesthesia and analgesia. *Companion animal* 23(4): 2-9
- Phillips, C.A., Roffey, J.B., Hall, E. & Johnson, R.S.P. (2016). Sex identification in the eastern blue-tongued lizard (*Tiliqua scincoides* White, ex Shaw, 1790) using morphometrics. *Australian veterinary journal* 94(7): 256-259.
- Quinn, H., Blasedel, T. & Platz, C.C. (1989). Successful artificial insemination in the checkered garter snake. *International Zoo Yearbook* 28: 177–83.
- Reptile database (2020). <https://reptile-database.reptarium.cz>.
- Rivera, S. (2008). Assessment of the Reptilian Reproductive Tract. *Journal of Exotic Pet Medicine* 17 (4): 259-266.
- Schildger, B., Haefeli, W., Kuchling, G., Taylor, M., Tenhu, H. & Wicker, R. (1999). Endoscopic examination of the pleuro-peritoneal cavity in reptiles. *Proceedings of Seminars in Avian and Exotic Pet Medicine* 8 (3): 130-138

- Schumacher, J. (2011). Respiratory Medicine of Reptiles. *Veterinary Clinics of North America: Exotic Animal Practice* 14 (2): 207-224.
- Scullion, F. & Scullion, G. (2009). Gastrointestinal Protozoal Diseases in Reptiles. *Journal of Exotic Pet Medicine* 18 (4): 266-278.
- Spadola, F. & Insacco, G. (2009). Endoscopy of cloaca in 51 *Emys trinacris* (Fritz et al., 2005): morphological and diagnostic study. *Acta Herpetologica* 4 (1): 73-81.
- Stahl, J. S. (2006). Introduction to cloacoscopy in snakes. *Proceeding of The North American Veterinary Conference*: 7-11.
- Sykes, J.M. (2010). Updates and Practical Approaches to Reproductive Disorders in Reptiles. *Veterinary Clinics of North America: Exotic Animal Practice* 13 (3): 349-373.
- Taylor, W. (2006). Endoscopy. In *Reptile Medicine and Surgery (Second Edition)*, 549-563. Douglas R. Mader, W.B. Saunders, ELSEVIER
- Trauth S.E., Cooper W.E., Vitt L.J., Perrill S.A. (1987). Cloacal anatomy of the broad-headed skink, *eumeces laticeps*, with a description of a female pheromonal gland. *Herpetologica* 43(4): 458-466.
- Vitt, L.J.; Caldwell, J.P. (2009). Anatomy of Amphibians and Reptiles. In *Herpetology*, 35-81, III Edition, Elsevier
- Wood, C.R., Wood, F.E. & Chrichtley, K.H. (1983). Laparoscopy of the green turtle, *Chelonia mydas*. *British Journal of Herpetology* 6: 323-327.
- Zacariotti, R.L., Grego, K.F. & Fernandes, W. (2007). Semen collection and evaluation in free-ranging Brazilian rattlesnakes (*Crotalus durissus terrificus*). *Zoo Biology* 26: 155–60.

FIGURES

Figure 1. Containment in dorsal recumbency of *Tiliqua* sp. Irian Jaya form

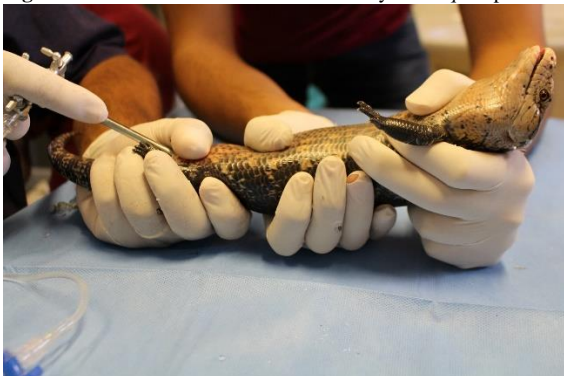

Figure 2. Ureteral papillae and vaginal papillae

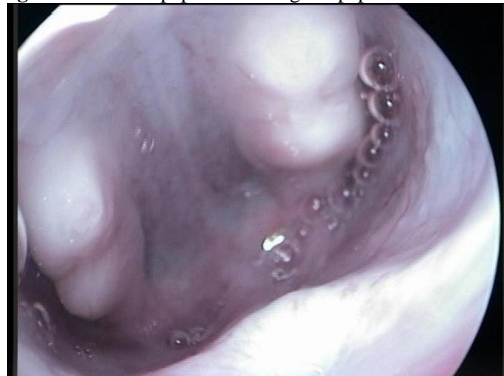

Figure 3. Single pair of papillae that highlights the gender as male

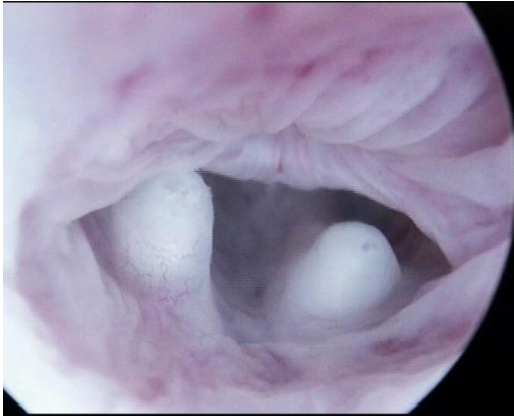
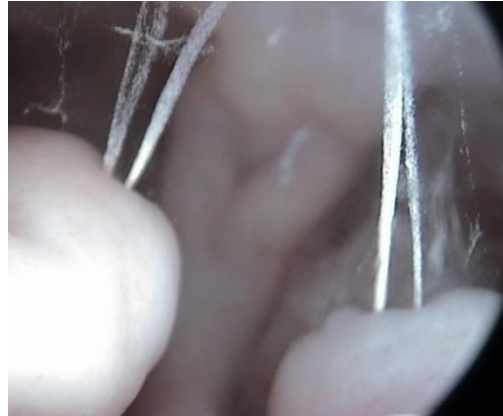


Figure 4. Uric acid excretion from ureteral papillae in the male specimen



Evaluation of cloacoscopy assisted sex determination in Argentine black and white tegu (*Salvator merianae*)

Morici M¹, Spadola F², Lubian E², Di Giuseppe M³, Oliveri M⁴, Bartoskova A⁴, Knotek Z⁴.

¹ Veterinary Department, Pombia Safari Park, Pombia, Italy.

² Department of Veterinary Medicine, University of Messina, Messina, Italy.

³ Centro Veterinario per Animali Esotici, Palermo, Italy

⁴ Avian and Exotic Animal Clinic, Faculty of Veterinary Medicine, University of Veterinary and Pharmaceutical Sciences Brno, Brno, Czech Republic

ABSTRACT

A total of 25 Argentine black and white tegus (*Salvator merianae*) were included in the study. Lizards were divided in two groups according to the age: 6 adults, and 19 two weeks old hatchlings. Sex of the adults was first determined by postcloacal spurs sex determination (PS). The diagnosis has been then confirmed by ultrasound visualization of the ovaries (in females). Once the sex was unequivocally known, the adults were used to describe the morphology of the cloaca, and to standardise the cloacoscopic technique. Sex of the hatchlings was first assessed using PS by a single operator, and then compared with the cloacoscopic sex determination (CSD). Acquired images were presented to two independent observers unaware of the results obtained from PS and cloacoscopy. While hatchlings were diagnosed as 7 females and 12 males with the use of PSS, 9 females and 10 males were determined by CSD. Hence merely 68.43% accuracy and statistical agreement of PSS method proved to be poor ($\kappa = 0.479$). CSD revealed a perfect agreement ($\kappa = 1$). Cloacoscopy proved accurate method for sex determination in adults and hatchlings of Argentine black and white tegus. We encourage the use of CSD in other squamate species.

Keywords: Cloaca; Endoscopy; Reptiles; Sex determination; *Salvator merianae*; Lizards .

Highlights:

- Cloacoscopic sex determination in *Salvator merianae* is proposed;
- Substantial differences in cloaca between sexes are described;
- Technique is fully explained and easily to perform in this lizard species;

Introduction

Approximately one fifth of reptilian species is listed as critically endangered, and another one in five species is classed as data deficient [1,2]. Their low dispersal ability, together with their great morphological and physiological specialization, makes reptiles highly sensitive to human caused habitat degradation and climate change [3,4]. Ex situ conservation and captive breeding programmes are hence become fundamental instruments in reptiles conservation [5]. Moreover, artificial insemination techniques seem to be close to standardization [6,7,8]. The basic knowledge of reptile reproductive morphology and anatomy is then necessary in order to standardize methods for artificial insemination, and early sex recognition [9,10]. Advanced endoscopic technique proven to be the ideal method for this purpose, being safe and non-invasive.

The sex recognition in lizard of the family *Teiidae* is challenging. Jaw-muscle dimension [11] and scale-vent distance have been described, but these methods entail a high risk of misdiagnosis [12]. The hemipenal pouches probing [13,14] may be used only in adult tegu lizards, thus sex determination in hatchlings is not possible using this technique. Subsequent infection and necrosis of everted hemipenes after injection of saline solution have been reported [15]. The technique of hemipenal eversion with manual massage is challenging in large lizard species with highly muscular tail, and it is dangerous in lizard taxa that perform caudal autotomy. Moreover this technique can cause serious injury if is not performed gently [16]. Evaluation of the presence of post-cloacal spurs (three slightly protruding scales) is the suggested sex determination technique in lizard of the family *Teiidae*, [17]. A post-cloacal spur is present on both side of the tail base in male Argentine black and white tegu. In females post-cloacal spurs can be also present, but of small dimension compared with male specimens.

Useful tools for sex determination in lizards proved to be methods of diagnostic imaging, especially ultrasound and diagnostic endoscopy. Ultrasound was used for control the follicular development on ovaries and for sex determination in monomorphic species of lizards [18,19,20,21]. However, gonadal ultrasound could be applied only in adult, sexually mature, lizards [15,22]. Cloacoscopy proved a feasible method of sex determination in many reptile species [23,24,25,26,27,28,29,30,31,32,33,34]. Informations dealing with cloacoscopy in tegus has not been published yet in popular literature, veterinary journals, conference proceedings, and exotic animal textbooks.

The aims of the study were a) the description of the cloaca in adult male and female Argentine black and white tegu with the use of cloacoscopy technique; b) to validate this technique for sex determination in hatchlings.

Material And Methods

Animals

A total of 25 Argentine black and white tegus (*Salvator merianae*) were included in the study. Lizards were referred to the Veterinary Teaching Hospital (University of Messina) from private breeders. All owners signed an informed consent for the study. The study was performed in compliance with directive 2010/63/EU of the European parliament and of the Council of the European Union. Lizards were divided in two groups according to the age: the first group included 6 adult tegus (1.8-2.2 kg), while the second group included nineteen 15 day-old hatchlings. Sex of the adult was firstly determined by the presence of post-cloacal spurs (PS). The sex determination has been then controlled with ultrasonography (visualization of the presence of ovaries in female tegus) with the use of a Mylab 40Vet (Esaote, Italy) with a linear transducer (7.5–12 MHz). Once the sex was unequivocally determined in all 6 adult tegus, the cloacoscopy was performed.

Cloacoscopy

Animals were restricted manually and positioned in dorsal recumbence on the electric heating pad (30 °C Bosch PFP 1031; Bosch, Germany). A rigid arthroscope (4 mm diameter, 0°, 8.5 cm length, Olympus medical, Japan) with a working sheath connected via one port with syringe (60 mL, Pic solutions/Artsana, Italy) and camera (Telecam DX-II, Karl Storz, Germany) with documentation system (TELE PACK, Karl Storz, Germany) was used for cloacoscopy. Cloacoscopy was performed by gently introducing the endoscope into the vent of the lizard, and visualizing the proctodeum, urodeum and coprodeum. Continuous flush with sterile saline solution (0.9 % NaCl, S.A.L.F., Italy) combined with 3 ml/L lidocaine chlorohydrate (2% Lidocaine, Esteve, Italy) was used for cloacal dilatation and a better visualization of anatomical structures. All lizards were kept on the clinic for 24 hours after the cloacoscopy and their health condition was monitored.

Sex determination in 19 hatchling tegus was firstly assessed by control of PS by one veterinarian (MdG). Cloacoscopy sex determination (CSD) was performed with two veterinarians (FS, MM), not informed about the previous sex determination with PS. All figures were then presented to two veterinarians not involved in CSD or control of PS. Since collected data have qualitative property numerical statistic test were not used. Instead, the Fleiss' kappa (κ) nominal scale measure [35] was used in order to assess the reliability of agreement between the results obtained from control of PS, cloacoscopy and final observers. The κ values range used to measure nominal scale agreement was from 0 to 1.

Results

Sex determination with the method of control the presence of PS

Sex determination in adult tegus using the ultrasonography was 3 males and 3 females. Accuracy of sex determination in 6 adult tegus with the method of control the presence of PS was 5/6 (83.3 %).

Sex determination with the method of control the presence of PS was accurate in 13/19 (68.4 %) hatchling tegus. Lizards were determined with this method as 7 females and 12 males, but sex determination with

cloacoscopy revealed that hatchlings were 9 females and 10 males instead. In 3 hatchling males and 4 hatchlings females the control of PS failed.

Sex determination with cloacoscopy

With the use of cloacoscopy the proctodeum of adult tegus was immediately visualized as the endoscope was inserted through the vent. Advancing cranially the optic, the urodeum (Fig. 1) was seen ventrally. It was present as a small central mucosal fold upon which the urinary papillae could be recognised. In adult female tegu, a mucosal recess was present just beyond the central mucosal fold; this recess was divided in two vaginal pouches by a vertical mucosal slit (Fig. 1a). In adult male tegu the central mucosal fold was not seen (Fig. 1b). The similar differences between males and females were found also with cloacoscopy in 15day-old hatchling tegus (Fig. 2). In the coprodeum the anal sphincter was easily overcome; afterward the rectal chamber was endoscopically explored (Fig. 3). During the whole procedure animals did not express any signs of discomfort.

Observers confirmed the results obtained from CSD during the blinded trial. Hence merely 68.4 % of diagnosis obtained from control of PS were accurate, and the statistical agreement of this technique proved to be poor ($K = 0.479$) when compared with CSD operators and blind observers results. Cloacoscopic sex determination showed instead perfect statistical agreement between cloacoscopy operators and subsequent blind observers ($K = 1$).

Discussion

In our experiment PS determination in young tegus proven accurate only in the 68.4 % of cases, hence it cannot be considered a good and reliable methods of early sex determination in *Salvator merianae* hatchlings. Cloacoscopy showed instead a great accuracy in sex determination, due to the indisputable anatomical differences between sexes. Moreover, cloacoscopic sex determination showed as an alternative an impeccable statistical agreement between cloacoscopy operators and subsequent blind observers.

The cloacal anatomy of lizards has already been described in detail [36,37]. As it is in other reptile species, the cloaca of Squamata is divided into three basic chambers, these are the coprodeum, urodeum, and proctodeum. The most outstanding characteristic of the Squamata feminine urodeum is the presence of the vaginal pouches; these are two recesses (present in the female urodeum since the hatch or the birth) that opens in the dorsal part of the urodeum and end in the vaginas [38,39]. The function of the vaginal pouch, as suggested by Ludwig and Rahn [40], is to aid copulation. In *Salvator merianae* a mucosal recess forms a vaginal pouch, hence proving the presence of it even in Teiidae. Similar morphological features have been described through cloacoscopy recently in *Vipera ammodytes* [10].

Cloacoscopy is an important tool in the study of cloaca anatomy. Cloacoscopy and cystoscopy have also been proposed as useful methods of sex determination in young chelonians by indirect visualization of gonads through the urinary bladder wall [29,33]; recently cloacoscopy has been purpose as a valid support in sex determination

in lizards [9], and as an aid tool for artificial insemination in snakes [8,10]. The cloacal morphology in reptiles shows great variability among species [9,10,26,41,42], and the physician should achieve a detailed knowledge of these differences prior to attempt the sex determination through cloacoscopy. Cloacoscopy has proven to be a safe and minimally invasive technique, comparable as invasiveness to a simple cloacal flushing. Our results demonstrate that CSD represent a highly accurate method for sex determination in *Salvator merianae*. This method can be considered a useful tool in *ex-situ* conservation programmes of endangered Teiidae. Moreover it can be easily used as sex determination method by reptile specialists. We strongly encourage the use of CSD in other squamate species in order to establish accurate references.

Conflict of interests

I declare that there is no conflict of interest that could be perceived as prejudicing the impartiality of the research reported.

References

- [1] Böhm, M., Collen, B., Baillie, J.E.M., Bowles, P., Chanson, J., Cox, N., Hammerson, G., Hoffmann, M., Livingstone, S.R., Ram, M., Rhodin, A.G.J., Stuart, S.N., van Dijk, P.P., Young, B.E., Afuang, L.E., Aghasyan, A., García, A., Aguilar, C., Ajtic, R., Akarsu, F., et al., 2013. The conservation status of the world's reptiles, *Biological Conservation* 157, 372-385.
- [2] Alroy, J. 2015. Current extinction rates of reptiles and amphibians. *PNAS* 112(42), 13003-13008.
- [3] Kearney, M., Shine, R., Porter, W.P., 2009. The potential for behavioural thermoregulation to buffer "cold-blooded" animals against climate warming. *Proceedings of the National Academy of Sciences USA* 106, 3835–3840.
- [4] Jenkins, R., Tognelli, M. F., Bowles, P., et al., 2014. Extinction Risks and the Conservation of Madagascar's Reptiles. *PLoS ONE*. 9(8):e100173.
- [5] Witzemberger, K.A., Hochkirch, A., 2011. *Biodivers Conserv* 20, 1843.
- [6] Mattson, K. J., De Vries, A., McGuire, S. M., Krebs, J., Louis, E. E., Loskutoff, N. M., 2007. Successful artificial insemination in the corn snake, *Elaphe gutatta*, using fresh and cooled semen. *Zoo Biol.* 26(5), 363-9.
- [7] Molinia, F. C., Bell, T., Norbury, G., Cree, A., Gleeson, D. M., 2010. Assisted breeding of skinks or how to teach a lizard old tricks! *Herpetological Conservation and Biology* 5(2), 311-319. [8] Oliveri, M., Spadola, F., Morici, M., Bartoskova, A., Di Giuseppe, M., Knotek, Z., 2017. Artificial insemination in snakes: techniques, challenges and success. *Proceedings 3rd ICARE, March 25th-29th 2017, Venice, Italy*, p. 543.
- [9] Morici, M., Di Giuseppe, M., Oliveri, M., Knotek, Z., Spadola, F., 2017. Cloacoscopic Sex Determination In Tegu Lizards. *Proceedings 3rd Icare, March 25th-29th 2017, Venice, Italy*, P. 544.

- [10] Oliveri, M., Morici, M., Novotný, R., Bartošková, A., Knotek, Z., 2016. Cloacoscopy in the horned viper (*Vipera ammodytes*). *Acta Veterinaria Brno* 85(3), 251-253.
- [11] Naretto, S., Cardozo, G., Blengini, C., Chiaraviglio, M., (2014). Sexual Selection and Dynamics of Jaw Muscle in Tupinambis Lizards. *Evol Biol* 41, 192–200.
- [12] Kratochvíl, L., Fokt, M., Reháček, I., Frynta, D., 2003. Misinterpretation of character scaling: a tale of sexual dimorphism in body shape of common lizards. *Canadian Journal of Zoology* 81(6), 1112-1117.
- [13] Hall, B. J., 1978. Notes on the husbandry, behaviour and breeding of captive tegu lizards *Tupinambis teguixin*. *International Zoo Yearbook* 18, pp 91-95.
- [14] Funk, R. S., 2002. Lizard reproductive medicine and surgery. *Vet Clin of North Am: Exot Anim Pract* 5, 579–613.
- [15] DeNardo, D., 2006. Reproductive biology, in: Mader, D. (Ed.), *Reptile medicine and surgery*. Saunders/Elsevier, St. Louis, MO, pp 379-384.
- [16] Reed, N.R., Tucker, A.D., 2012. Determining age, sex and reproductive condition, in: McDiarmid RW, Foster MS, Guyer C, Gibbons JW, Chernoff N (Eds.), *Reptile biodiversity: standard methods for inventory and monitoring*. Los Angeles, California: University of California Press, p. 151.
- [17] Sprackland, R. G., 2009. *Giant lizards: The definitive guide to the natural history, care, and breeding of monitors, iguanas and other large lizards* T.F.H. Publications.
- [18] Morris, P. J., Alberts, A. C., 1996. Determination of sex in white-throated monitors (*Varanus albigularis*), Gila Monsters (*Heloderma suspectum*) and bearded lizards (*Heloderma horridum*) using two-dimensional ultrasound imaging. *J Zoo Wildl Med* 27, 371–377.
- [19] Schumacher, J., Toal, R. L., 2001. Advanced radiography and ultrasonography in reptiles. *Semin Avian Exot Pet* 10, 162–168.
- [20] Gartrell, B. D., Girling, J. E., Edwards, A., Jones, S. M., 2002. Comparison of noninvasive methods for the evaluation of female reproductive condition in a large viviparous lizard, *Tiliqua nigrolutea*. *Zoo Biol.* 21, 253–268.
- [21] Prades, R. B., Lastica, E. A., Acorda, J. A., 2013. Ultrasound features of the kidneys, urinary bladder, ovarian follicles and vaginal sacs of female water monitor lizard (*Varanus marmoratus*, Weigmann, 1834). *PJVAS* 39, 115–124.
- [22] Stetter, M. D., 2006. Ultrasonography, in: Mader, D. (Ed.), *Reptile medicine and surgery*. Saunders/Elsevier, St. Louis, MO, pp. 665–674.

- [23] Schildger, B.J., Wicker, R., 1989. Sex determination and clinical examination in reptiles using endoscopy. *Herp. Rev.* 20, 9-10.
- [24] Schildger, B. J., Haefeli, W., Kuchling, G., Taylor, M., Tehnu, H., Wicker, R., 1999. Endoscopic examination of the pleuro-peritoneal cavity in reptiles. *Seminars in Avian and Exotic animals Medicine* 8(3), 130-138.
- [25] Kuchling, G., 2006. Endoscopic sex determination in juvenile freshwater turtles, *Erymnochelys madagascariensis*: Morphology of Gonads and Accessory Ducts. *Chelonian Conservation and Biology* 5(1), 67-73.
- [26] Spadola, F., Insacco, G., 2009. Endoscopy of cloaca in 51 *Emys trinacris* (Fritz et al., 2005): morphological and diagnostic study *Acta Herpetologica* 4(1), 73-81.
- [27] Divers, S. J., 2010. Reptile diagnostic endoscopy and endosurgery. *Vet Clin North Am Exot Anim Pract.* 13(2), 217-42.
- [28] Innis, C. J., 2010. Endoscopy and endosurgery of the chelonian reproductive tract. *Vet Clin North Am Exot Anim Pract.* 13(2), 243-54.
- [29] Selleri, P., Di Girolamo, N., Melidone, R., 2013. Cystoscopic sex identification of posthatchling chelonians. *J Am Vet Med Assoc* 242, 1744-1750.
- [33] Martínez-Silvestre, A., Bargalló, F., Grifols, J., 2015. Gender identification by cloacoscopy and cystoscopy in juvenile chelonians. *Vet Clin North Am Exot Anim Pract.* 18(3), 527-539.
- [34] Perpignan, D., Martínez-Silvestre, A., Bargallo, F., Di Giuseppe, M., Oros, J., Pereira Da Costa, T., 2016. Correlation between endoscopic sex determination and gonad histology in pond sliders, *Trachemys scripta* (Reptilia: Testudines: Emydidae)' *Acta Herpetologica* 11(1), 91-94.
- [35] Geertzen, J., 2012. Inter-Rater Agreement with multiple raters and variables. Retrieved November 28, 2016.
- [36] Fox, H., 1977. The urinogenital system of reptiles, in Gans, C. (Ed.), *Biology of the Reptilia*. vol 6. New York: Academic Press, pp 1-157.
- [37] DeVoe, R., 2002. The herptile cloaca: anatomy, function and disease. *Proc Assoc Reptilian Amphib Vet.*, pp 127-130.
- [38] Aldridge, R.D., 1992. Oviductal anatomy and seasonal sperm storage in the southeastern crowned snake (*Tantilla coronata*). *Copeia*, 1103–1106.

- [39] Blackburn, D. G., 1998. Structure, function, and evolution of the oviducts of squamate reptiles, with special reference to viviparity and placentation. *J Exp Zool.* 282(4-5), 560-617.
- [40] Ludwig, M., Rahn, H., 1943. Sperm storage and copulatory adjustment in the prairie rattlesnake. *Copeia* 1, 15-28.
- [41] Spadola, F., Morici, M., 2015. Morphology of the cloacal structure of the chinese soft-shell turtle in *Pelodiscus sinensis* examined by endoscopy. *Russian journal of Herpetology* 22 (3), 175-178.
- [42] Spadola, F., Morici, M., Oliveri, M., Knotek, Z., 2016. Description of cloacoscopy in the loggerhead sea turtle (*Caretta caretta*) *Acta Vet. Brno* 85, 367-370.

Sex determination through endoscopic visualization of the urodeum slit in chelonians: an accurate and viable technique

Filippo Spadola¹, Emanuele Lubian¹, Matteo Oliveri², Manuel Morici¹, Zdenek Knotek²

¹ Department of Veterinary Science, University of Messina, Messina, Italy

² Avian and Exotic Animal Clinic, Faculty of Veterinary Medicine, University of Veterinary and Pharmaceutical Sciences Brno, Brno, Czech Republic

Abstract: Accurate sex determination is generally easily performed in adult chelonians, but it is much more difficult in juveniles and hatchlings. The objective of our study is to provide an accurate description of the morphological differences between the male and female urodeum in chelonians using endoscopy. These differences can be useful in gender determination of immature specimens. A total of 186 chelonians were included in this study. Sedated animals were placed in dorsal recumbence during the procedure. According to the dimension of the specimen, two different types of optics have been used for cloacoscopy: a rigid endoscope with linear vision 0° (8.5 cm length, 5 mm diameter) with working sheath, and a micro-endoscope with linear vision 0° (6.7 cm length, 1.25 mm diameter) with working sheath. Gender identification was achieved through visualization of the urodeum slit and genital papillae. The diagnosis was then confirmed through cystoscopy in the immature specimens, or displaying the genitalia (clitoris or phallus) in the adult specimens. The visualization of the urodeum slit by endoscopy has proven to be an effective and minimally invasive method in sex identification of turtles and tortoises.

Keywords: Cloaca; Cystoscopy; Endoscopy; Proctodeum; Urinary bladder; Urodeum

Introduction

Sex determination is the starting point for any captive breeding project. Accurate sex determination is generally easily performed in adult chelonians, but it is much more difficult in young chelonians (hatchlings and juveniles) that still don't display the classical sexual dimorphism. Most of the sexing methods described in the literature are either more invasive or unsuitable for young chelonians. Several authors described hormonal values on blood samples using radioimmunoassay (Owens et al. 1978, Gross et al. 1995), but this technique entail a major limitation due to the amount of blood required (particularly in small animals). Plasma testosterone assay revealed

to be the most suitable methodology for field studies, with an accuracy of 98% (Rostal et al. 1994), but specialized laboratory equipment is required and the standard value are available just for a few species (Gross 1995; Xia 2011). Endoscopic examination, either through the pre-femoral fossa or the urinary bladder, is extensively described in the literature (Divers 2009, Selleri et al. 2013; Martinez et al. 2015). These techniques however require the animal to be sedated and are extremely difficult in the smallest specimens. Therefore, the objective of our study is to provide an accurate description of the morphological differences between the male and female urodeum in chelonians using endoscopy. The urodeum hosts in fact several sex-related structures as the urogenital papillae and is likely to entail macroscopic differences between genders. These differences may allow early gender identification in young chelonians.

Material and methods

A total of 186 chelonians were included in this study (45 *Testudo hermanni*, 5 *Pseudemys concinna*, 15 *Pseudemys nelsoni*, 6 *Graptemys kohnii*, 80 *Trachemys scripta elegans*, and 35 *Trachemys scripta scripta*). Animals were divided in 3 groups according to the age: the juvenile group included 35 post hatchling turtles and tortoises (from 5 months to one year, average weight 112.93 ± 2.89 g); the sub adult group included 86 turtles and tortoises (from one year to 5 years, average weight 359 ± 3.66 g); the adult group included 65 turtles and tortoises (average weight 753.53 ± 22.34 g). The average weight of the whole group was 426.02 ± 183.56 g. Chelonians were chosen among the animals referred for clinical examination. Specimens used in the experiment were found healthy upon clinical examination. Sedation was achieved with a dose of 5 mg/kg of tiletamine/zolazepam (Zoletil®, Virbac, France) administrated intravenously in the dorsal cervical sinus. Sedation procedures was performed with the permission of the owners that signed an informed consent. The study was performed in compliance with directive 2010/63/EU of the European parliament and of the Council of the European Union.

Sedated animals were placed in dorsal recumbency on a heating pad during the procedure. Two different types of optics have been used for cloacoscopy: a rigid endoscope with linear vision 0° (8.5 cm length, 5 mm diameter. Olympus medical, Tokyo, Japan), and a micro-endoscope with linear vision 0° (6.7 cm length, 1.25 mm diameter. Olympus medical, Tokyo, Japan). In both cases, the optic was provided with a working sheath. Dimension of the optic was chosen according to the size of the specimen. The endoscope was connected to a camera (Telecam DX-II). A Karl Storz TELE PACK connected to the system was used for camera control and image documentation, and as a light source. Cloacoscopy was performed introducing the endoscope into the cloacal opening, and visualizing in sequence the proctodeum (and genitalia), and the urodeum. The urinary bladder was explored, in order to display the gonads, once the gender determination was performed visualizing the urodeum slit as a control method. Sterile saline solution (30°C , 0.9 % NaCl, S.A.L.F., Italy) combined with 3 ml/L lidocaine chlorohydrate (2% Lidocaine, Esteve, Italy), was injected through the working sheath to dilate the cloacal wall for a better visualization. Additional gentle flushing was performed using a syringe (60 mL, Pic

solutions/Artsana, Italy) connected with an intravenous drip line to the working sheath port. Once the cloacoscopy was performed, all chelonians have been closely monitored for a minimum of 48 hours. Complete recovery was uneventful in all the subjects.

Results

Once the endoscope is inserted through the cloacal sphincter, the proctodeum can be visualized. The genitalia (clitoris and phallus) can be observed tilting the scope ventrally. Both structures are on the ventral surface of the proctodeum, and their distinction poses no difficulty to the experienced clinician in the adult animal. Phallus and clitoris however cannot be distinguished in the immature specimen. The phallus consists of two parallel bands of sinusoidal tissue named corpora cavernosa. Between these structures lays the sulcus spermaticus, which is a groove that allows for the flow of the sperm during the copulation. The corpora cavernosa end in the glans, which is an enlarged structure that hosts the outlet of the sulcus spermaticus (Fig. 1 C and D). The female chelonian possesses a homologue of the penis named clitoris. The clitoris repeats the same structure of the phallus, but is generally smaller and is not directly involved in the copulation (Fig. 1 A and B). Both clitoris and phallus lay in the cloaca with the glans directed to the vent. The differences in these two structures are minimal in the young chelonians, and do not allow for an indisputable gender determination. After the visualization of the genitalia, the scope can be inserted forward to display the urodeum. Two main structures are visible in the urodeum: the entrance of the coprodeum (anal sphincter), and a V shaped muscular structure named the urodeum slit, which covers the urogenital papillae and the entrance of the urinary bladder. The urodeum slit can be visualized immediately dorsally to the anal sphincter, it is formed by two muscles that converge to cover the urogenital senum (Spadola and Isacco 2009), (Fig. 2). Emydidae possess two additional chambers that open in the ventro-lateral surface of the urodeum, these are the accessory bladders (Fig. 3). The morphological differences between male and female urodeum will be listed below.

In the male chelonian: the urodeum is characterized by a thin and highly vascularized mucosa. The urodeum slit is smaller and the surface of the mucosa is smooth (Fig. 2 C and D; Fig. 4; Fig. 5 A and B). The urogenital papillae (the emergences of the spermatic duct and ureters into the cloaca) are small and barely distinguishable in the male urodeum (Fig. 6 A and B).

In the female chelonian: the mucosa of the urodeum is deeply folded and presents a lesser vascularization (Fig. 2 A and B; Fig. 3; Fig. 7 A and B). The urodeum slit is larger and more prominent, and the urogenital papillae are bigger and observables. During the reproductive period the urodeum slit is enlarged and hyperaemic (Fig. 3 D). The urogenital papillae surface in the dorsal part of the urodeum, in proximity of the neck of the bladder and arise as two prominent and convoluted structures (Fig. 6 C).

These differences (shape and size of the urodeum slit) can be detected in young chelonians as well, and are a suitable method for gender identification (sex determination). The morphology of the cloaca is extremely variable among the different species. In our experiment however, the family Emydidae proved to be quite conservative

regarding the cloacal anatomy. A more detailed resume of the results, divided by species and ages, is presented in table 3.

After the visualization of the urodeum slit we confirmed our gender determination through more extensively described techniques. In sexually mature specimens the gender was confirmed by visualization of the phallus or clitoris (Fig 1). Otherwise, in young chelonians, trans-cloacal cystoscopy was performed to validate the sex determination: the endoscope was progressed through the cloaca, overcoming the urinary bladder neck and finally visualizing the interior of the urinary bladder (Fig 8). Once the scope was inserted into the urinary bladder, warm saline solution was flushed through the working sheath to allow the distension of the urinary bladder wall. The gonads were easily seen through the diaphanous mucosa (Fig 8), allowing for the sex confirmation. Trans-cloacal cystoscopy has proven to be accurate in sex determination for most of the specimens; however in 7 post hatchlings *Testudo hermanni* (3.76% of the sample size) gonads could not be distinguished. In Emydidae a suitable alternative to the traditional cystoscopy is the exploration of the accessory bladders. The accessory bladders are two diverticula that extend laterally and cranially in proximity of the neck of the urinary bladder. The gonads were easily visualized from the accessory bladders in the adults Emydidae (Fig. 5).

A total of 137 females, and 49 males (49.137) were sexed during the trial (*Testudo hermanni* 18.27; *Graptemys konhii* 3.3; *Pseudemys concinna* 0.5; *Pseudemys nelsoni* 3.12; *Trachemys scripta elegans* 13.67; *Trachemys scripta scripta* 28.7). Results are displayed in table 1. The visualization of the urodeum slit by endoscopy has proven to be an effective method for sex identification in 96.24% of the specimens examined (verified through cystoscopy or genitalia visualization).

Discussion

Endoscopic sex determination in young chelonians has been already described by Selleri et al. (2013). Their procedure includes cystoscopy and visualization of the gonads through the diaphanous wall of the urinary bladder. Although the cystoscopy allows for a good display of the genital structure in turtles and tortoises, the details of the gonads are not easily distinguished. Furthermore the risk of urinary bladder rupture shall be considered (Proenca and Divers 2015). A cloacoscopic sex determination technique was recently investigated by Perpignan et al. 2016. In this research, sex determination through genitalia (phallus/clitoris) is described with poor results. In fact genitalia can be extremely similar, leading to misdiagnosis.

According to Divers (2009) coelom endoscopy (coelioscopy) through the pre-femoral fossa permits a more detailed gonads visualization, and can be considered the most rapid and effective sexing method. Coelioscopy proven to be an accurate method for sex determination in chelonians (Martinez et al. 2015), however it requires a deep plane of anaesthesia and analgesia. Thus the development of a safe and minimally invasive method for sex determination in young chelonians is an important goal in reptile medicine and conservation (Burke et al. 1994). The use of cloacoscopy as minimally invasive method for sex determination in young chelonians showed to be promising (Schildger and Wicker 1989, Innis 2004 and 2010, Jekl et al. 2007). Our method can be

considered among the lesser invasive for sex determination in young chelonians. However, the cloacal morphology in chelonians shows enormous variability between the different species (Spadola and Morici 2015), and the clinician should achieve a detailed knowledge of these differences prior to attempt the sex determination through cloacoscopy. Furthermore the availability of the method is not uniform among the different species and ages. In table 2 we propose a resume of the difficulties that the clinician may find attempting the sex determination through the visualization of the urodeum.

Conclusions

The visualization of the urodeum slit by endoscopy has proven to be an effective and minimally invasive method in sex identification of turtles and tortoises. This method showed to be effective on young chelonians (juveniles and hatchlings) as well. We consider the endoscopic examination of the urodeum slit an adequate choice for gender identification in breeding program of endangered species, as it pose minimal risk for the health of the animals.

Acknowledgment

Authors would like to thanks all the supporting staff for this research (technician and students). No conflict of interest are present in this manuscript.

References

1. Burke RL, Jacobson ER, Griffith MJ, Guillette LJ. 1994. Non-invasive sex identification of juvenile gopher and desert tortoises (genus *Gopherus*). *Amphibia-Reptilia* 15:183-189.
2. Gross TS, Crain AD, Bjorndal KA, Bolten AB, Carthy RR. 1995. Identification of sex in hatchling loggerhead turtles (*Caretta caretta*) by analysis of steroid concentrations in chorioallantoic/amniotic fluid. *Gen. Comp. Endocrinol.* 99:204-210.
3. Hernandez-Divers SJ, Stahl SJ, Farrell R. 2009. An endoscopic method for identifying sex of hatchling Chinese box turtles and comparison of general versus local anaesthesia for coelioscopy. *J. Am. Vet. Med. Assoc.* 234:800-804.
4. Innis CJ. 2004. Innovative approaches to chelonian obstetrics. *Exotic DVM* 6(3):78-82.
5. Innis CJ. 2010. Endoscopy and endosurgery of the chelonian reproductive tract. *Vet. Clin. North Am. Exot. Anim. Pract.* 13:243-54.
6. Jekl V, Hauptman K, Knotek Z. 2007. Cloacoscopy in chelonians: a valuable diagnostic tool for reproductive tract evaluation. In: *Proceedings of the 43rd International Symposium on Diseases of Zoo and Wild Animals, Edinburgh, May 16-20*, pp 162-3.
7. Martínez-Silvestre A, Bargalló F, Grífols J. 2015. Gender Identification by Cloacoscopy and Cystoscopy in Juvenile Chelonians, *Veterinary Clinics of North America: Exotic Animal Practice* 18(3): 527-539.

8. Owens DW, Hendrickson JR, Lance VA, Canard P. 1978. A technique for determining sex of immature *Chelonia mydas* using radioimmunoassay. *Herpetologica* 34:270-273.
9. Perpignan, D, Martinez-Silvestre A, Bargallo F, Di Giuseppe M, Oros J, et al. 2016. Correlation between endoscopic sex determination and gonad histology in pond sliders, *Trachemys scripta* (Reptilia: Testudines: Emydidae) *Acta Herpetologica* 11(1): 91-94.
10. Proenca LS, Divers SJ. 2015. Comparison between coelioscopy versus cloacoscopy for gender identification in immature turtles (*Trachemys scripta*). In: proceedings of ICARE II, Paris, France, April 18-23, pp.142–43.
11. Rostal DC, Grumbles JS, Lance VA, Spotila JR. 1994. Non-lethal sexing techniques for hatchling and immature desert tortoises (*Gopherus agassizii*). *Herpetol. Monogr.* 8:72-82.
12. Schildger BJ, Wicker R. 1989. Sex determination and clinical examination in reptiles using endoscopy. *Herp. Rev.* 20:9-10.
13. Selleri P, Di Girolamo N, Melidone R. 2013. Cystoscopic sex identification of posthatchling chelonians. *J. Am. Vet. Med. Assoc.* 242: 1744-50
14. Spadola F, Morici M 2015: Morphology of The Cloacal Structure Of The Chinese Soft-Shell Turtle In *Pelodiscus Sinensis* Examined By Endoscopy. *Russian Journal of Herpetology* 22(3): 175–178.
15. Spadola F, Isacco G. 2009. Endoscopy of cloaca in 51 *Emys trinacris* (Fritz et al., 2005): morphological and diagnostic study. *Acta Herpetologica* 4(1):73-81.
16. Xia ZR, Li PP, Gu HX, Fong JJ, Zhao E. 2011. Evaluating non invasive methods of sex identification in green sea turtle (*Chelonia mydas*) hatchlings. *Chelonian conservation and biology* 10: 117-123.

Survey on cloacocystoscopy as a diagnostic tool for emidids and geoemidids

LUBIAN E.^{1,3,4}; PAGNINI N.²; BARDI E.³ & SPADOLA F.¹

¹ Department of Veterinary Science, University of Messina, Polo Didattico Annunziata 98168 Messina, Italy

² Ambulatorio Veterinario Galciana, Via Mannocci 32, 59100, Prato, Italy

³ MypetClinic, Viale Ranzoni 10, 20149, Milano, Italy

⁴ Ospedale Veterinario Universitario Piccoli Animali, Università degli Studi di Milano

The cloaca is a distinctive tract of avian and reptilian anatomy and has been subjected to numerous studies regarding the morphology, in order to identify species specific differences and to develop better endoscopic techniques. Cloacoscopy and cystoscopy in chelonians has been described not only to diagnose and treat pathologies of the cloacal tract itself, but also to observe the viscera, since the bladder wall is characterized by a great distensibility and transparency, especially regarding gonadal visualization in immature subjects. The present preliminary study values the diagnostic potential of cloacocystoscopy in Emydidae and Geoemydidae. In this study 36 different cloaco-cystoscopic studies were taken into account, all of them were performed by the same operator, with the same tools (rigid telescope with 2,7mm diameter, operating sheet of 4,8 mm diameter, xenon light source, endovideo, Ringer Lactate solution to irrigate the cloaca and the urinary bladder) on specimens from 120gr to 970gr weight. Turtles were not sedated and were kept in dorsal recumbency. Prevalence of visualization of the caudal margins of the liver, of the intestines and of the gonads was calculated, taking into account both the visualization obtained through the urinary bladder and through the accessory bladders. Results show a better visualization of the liver and the intestine through the bladder wall, and a better gonadal view through the accessory bladder. It's described also the possibility and the prevalence of entering in the distal part of the oviduct.

Survey on cloacocystoscopy as a diagnostic tool for Eastern Hermann's tortoise (*Testudo hermanni boettgeri*)

LUBIAN E.^{1,3,4}; ADINOLFI V.²; BARDI E.³ & SPADOLA F.¹

¹ Department of Veterinary Science, University of Messina, Polo Didattico Annunziata 98168 Messina, Italy,

² Centro Veterinario della Frascheta, via Vittorio Veneto 19, Pozzolo Formigaro, Italy

³ MypetClinic, Viale Ranzoni 10, 20149, Milano, Italy

⁴ Ospedale Veterinario Universitario Piccoli Animali, Università degli Studi di Milano

In this study we want to analyze, through a retrospective investigation of cystoscopies performed by the same operator, which are the organs that can be viewed through cystoscopy, trying to create a classification method to standardize this diagnostic procedure. In this study 23 different cloaco-cystoscopic studies in Eastern Hermann's tortoise (*Testudo hermanni boettgeri*) were taken into account, all of them were performed by the same operator, with the same tools (rigid telescope with 2,7mm diameter, operating sheath of 4,8 mm diameter, xenon light source, endovideo, Ringer Lactate solution to irrigate the cloaca and the urinary bladder) on specimens from 92gr to 1860gr weight. Chelonians were kept in dorsal recumbency without sedation. Prevalence of visualization of the caudal margins of the liver, of the intestines and of the gonads was calculated, considering weight, gender and age of the animals. In adults it was also possible to enter the oviduct (never reported in previous studies), so it could be considered a good method for diagnostics and therapy during dystocia. Cystoscopic sexing, although reported to be 100% sensitive by other authors, was not possible in all specimens in this study, due to the frequent presence of bladder stones and the more opacity of the bladder that did not allow for good visualization. It can be said that cloacocystoscopy is an excellent diagnostic method for the endoluminal evaluation in tortoises of the genus *Testudo*. This technique has proved to be very useful for transvesical diagnostic evaluation with minimal invasiveness and rapidity of execution; although there are some limitations, such as the difficulty of visualizing some organs due to the presence of bladder stones or the lower transparency of the bladder wall (especially if compared with Emydidae).

Comparison of Lateral and Dorsal Recumbency During Endoscope-Assisted Oophorectomy in Mature Pond Sliders (*Trachemys scripta*)

Edoardo Bardi^{1,*}, Giulia Antolini¹, Emanuele Lubian², Valerio Bronzo¹ and Stefano Romussi¹

¹ Department of Veterinary Medicine, University of Milan, via dell'Università 6, 26900 Lodi, Italy; giuliaantolini25@gmail.com (G.A.); valerio.bronzo@unimi.it (V.B.); stefano.romussi@unimi.it (S.R.)

² Veterinary Clinical and Husbandry Centre (CCVZS), University of Milan, via dell'Università 6, 26900 Lodi, Italy; emanuele.lubian@hotmail.com

* Correspondence: edoardo.bardi@unimi.it; Tel.: +39-38-9829-8365

Received: 8 August 2020; Accepted: 17 August 2020; Published: 19 August 2020

Simple Summary: Ovariectomy via the prefemoral fossa, with or without endoscopic assistance, is a well-described technique for elective and therapeutic sterilization in chelonians. The choice between lateral and dorsal recumbency is generally left to the surgeon's preference, with no data supporting an objective superiority of one over the other. In pond sliders, common pets but also an invasive alien species in Europe, we compared two different recumbencies (right lateral with a left fossa approach, and dorsal with a right fossa approach) regarding ease of access to the coelomic cavity, ease of identification of the ovary opposite to the surgical breach, first and second ovary removal times, and total surgical time. No significant difference was found between the two groups for any evaluated parameter. Endoscope-assisted prefemoral ovariectomy in mature pond sliders can be indifferently performed in lateral or dorsal recumbency, depending on the preference of the surgeon, on the animal's pathophysiologic status, or on the necessity to perform concurrent procedures.

Abstract: Ovariectomy via the prefemoral fossa is a well-described technique for sterilization in chelonians. The choice between lateral and dorsal recumbency is generally left to the surgeon's preference, with no data supporting an objective superiority of one over the other. Twenty-four sexually mature female pond sliders (*Trachemys scripta*) were enrolled for elective prefemoral endoscope-assisted oophorectomy, and were randomly divided in two groups: 12 animals were placed in right lateral recumbency with a left fossa approach (Group A), and 12 in dorsal recumbency with a right fossa approach (Group B). Scoring systems were applied to assess the ease of access to the coelomic cavity, and the ease of identification of the ovary opposite to the surgical incision. A negative correlation was found between the body weight of the animals and the ease of access to the coelom ($p = 0.013$), making the access easier in smaller animals. No significant difference was found between the two groups in terms of ease of access to the coelomic cavity, first ovary removal time, ease of identification of the second ovary, second ovary removal time, or total surgery time.

Keywords: chelonians; coelioscopy; endoscopic surgery; oophorectomy; pond slider; *Trachemys scripta*

1. Introduction

Historically, ovariectomy and ovariosalpingectomy in chelonians have been performed to deal with afflictions of the reproductive tract, and more recently, for population control.¹⁻⁴ The increase in requests for elective sterilization in these species is surely, in part, due to the development of minimally invasive techniques such as prefemoral coeliotomy, which allows the surgeon to avoid plastron osteotomy—a much more invasive

procedure with a prolonged recovery time and greater possibility of post-operative complications.^{5,6} Both elective and therapeutic oophorectomy/ovariosalpingectomy via prefemoral coeliotomy, with or without endoscopic assistance, have been extensively described and documented.^{2,3,5-10} However, to date, no indication has been given as to which recumbency better serves the purpose of a quicker and more comfortable procedure. Therefore, this decision is made based on the species, the size of the patient, and on the surgeon's preference.^{2,6}

The present work aims to investigate whether a recumbency (dorsal vs. lateral) is actually preferable for elective endoscope-assisted prefemoral oophorectomy in mature pond sliders (*Trachemys scripta*).

2. Materials and Methods

All the patients were privately owned animals referred to the Lodi Veterinary Teaching Hospital, between May and September 2019, for elective surgical sterilization with written, informed consent signed by the owners. The inclusion criteria consisted of clinically healthy adult females with a body weight (BW) over 900 g, maintained in the area of the Po Valley with correct outdoor management, which was defined as adequate space for swimming and basking, with good water quality, correct nutrition, the presence of nesting sites if they were active egg layers, and natural hibernation being allowed through the years. Before enrollment, a blood sample was collected from each animal from the cervical plexus to investigate packed cell volume (PCV), serum total protein (TP) using a refractometer, and white blood cell count (WBC) using the Natt and Herrik method.¹¹ For each animal, a dorsoventral X-ray projection was performed. Animals with the presence of eggs, PCV below 20% or over 35%, WBC over $19 \times 10^3/\mu\text{L}$, and TP below 1.5 or over 8 g/dL, were excluded from the study.¹²

All applicable international, national, and/or institutional guidelines for the care and use of the animals were followed. The protocol for care, handling, and sampling of animals defined in the present study was reviewed and approved by the University of Milan Animal Care and Use Committee (OPBA protocol 44/2020).

A total of 27 animals were selected, aged from 5 to 35 years (median 15 ± 7.7 years), with a BW from 925 to 2200 g (median 1480 ± 382.5 g). All the patients were hospitalized one week prior to surgery and individually housed outdoors; food was withheld 48 h prior to surgery.¹³ Each subject was randomly assigned to one recumbency group (Group A: right lateral recumbency with a left prefemoral fossa approach; Group B: dorsal recumbency with a right prefemoral fossa approach). All the procedures were performed by the same experienced surgeon, who had a record of over 20 endoscope-assisted oophorectomies with both techniques in this species prior to this study. For each subject, scoring systems based on those previously published in the literature¹³ were modified and applied by the surgeon to assess the ease of access to the coelom (Table 1) and the ease of identification of the ovary opposite to approached fossa (Table 2).

Table 1. Scoring system for ease of access to the coelom, modified from Divers et al., 2010.

Score		Time (Minutes)
5	Excellent	<1
4	Good	1 to 2
3	Satisfactory	>2 to 4
2	Difficult	>4 to 5
1	Very difficult	>5

Table 2. Scoring system for ease of identification of the ovary opposite to the surgical incision, modified from Divers et al., 2010.

Score	Identification
5	Immediately recognizable
4	Recognizable through a membrane (e.g., mesentery, mesovarium)
3	Not immediately recognizable, need for minor visceral manipulation
2	Not immediately recognizable, need for major visceral manipulation
1	Not recognizable, impossible to exteriorize

Before induction, an attempt to empty the urinary bladder was made by stimulating the cloaca with cotton tip applicators. Anesthesia was induced by an intramuscular (IM) administration of dexmedetomidine (Dexdomitor, Vetoquinol Italia S.r.l., Bertinoro, Italy) 100 µg/kg, ketamine (Nimatek, Dechra Pharmaceuticals PLC, Bladel, Netherland) 3 mg/kg, midazolam (Midazolam IBI, Giovanni Lorenzini S.p.A, Aprilia, Italy) 0.5 mg/kg, and alfaxalone (Alfaxan, Jurox Limited, Malvern, UK) 8.5 mg/kg. The animals were intubated with a 1.5 or 2.0 mm uncuffed endotracheal tube, and intermittent positive-pressure ventilation was manually provided (two breaths per minute) administering 100% O₂ without inhalant anesthetics. This protocol was selected as part of a separate study. The anesthetic parameters monitored were the palpebral and corneal reflexes, limb withdrawal latency, cloacal temperature, and heart rate via ECG.¹⁴

Once a surgical anesthetic plane was reached, the animals assigned to Group A were placed in right lateral recumbency inside an empty glovebox lined with a clean puppy pad to prevent rocking movements, and the left hindlimb was extended to better expose the fossa (Figure 1A). The prefemoral fossa and surrounding shell and thigh were aseptically prepared with chlorhexidine solution (Clorexyderm 4%, ICF s.r.l., Palazzo Pignano,

Italy), and a fenestrated drape was placed to isolate the surgical site. The animals assigned to Group B were placed in dorsal recumbency; a folded puppy pad was placed underneath to prevent rocking movements, and to create a 30° angle to better expose the right prefemoral fossa (Figure 1B). The ipsilateral hindlimb extension and aseptic dressing of the surgical site were the same as in Group A.



Figure 1. Patients placed in right lateral (A) and dorsal (B) recumbency, with their hindlimb extended to expose the prefemoral fossa.

The surgical procedure was performed as previously described:^{3,5} a craniocaudal skin incision was made and extended along 75% of the craniocaudal length of the prefemoral fossa, followed by blunt dissection of the subcutaneous tissue. After its exposure and identification, the aponeurosis of the ventral and oblique abdominal muscles, and the coelomic membrane, were pierced with the tip of mosquito forceps to gain access to the coelomic cavity, minimizing the risk of damaging the internal organs.

The coelomic cavity was inspected with a 30°, 2.7 mm × 18 cm rigid endoscope (Hopkins telescope, Karl Storz Endoscopia Italia S.r.l., Verona, Italy), inserted in a 3.5 mm sheath and connected to a xenon light source (Tele Pack XLED TP100, Karl Storz Endoscopia Italia S.r.l., Verona, Italy)

to investigate potential abnormalities that did not show up during the health assessment. Animals that showed coelomic alterations were excluded from the study. Cystocentesis was performed if the urinary bladder was distended.⁶ After coelomic inspection, the incision on the aponeurosis and on the membrane was extended to match the cutaneous incision, and in those subjects in dorsal recumbency, a ring retractor with elastic stays (Lone Star Retractor System, Cooper Surgical, Origio Italia S.r.l., Roma, Italy) was used to provide exposure.

Once the ovary was identified, the avascular interfollicular connective tissue was grasped with straight Debakey forceps and gentle traction was applied to completely exteriorize the ovary from the breach and expose vascularization (Figure 2A, B). The ovarian vessels were ligated with stainless steel surgical ligation clips (Ligature Clip, Aesculap AG, Tuttlingen, Germany), and the mesovarium was transected with scissors. After resection of the ovary, the mesovarium was replaced inside the coelom, and an endoscopic inspection of the cavity was performed to verify hemostasis and check for residual follicles. For both groups, the ovary resection

time was recorded from first grasping the interfollicular tissue to the endoscopic confirmation of total resection.

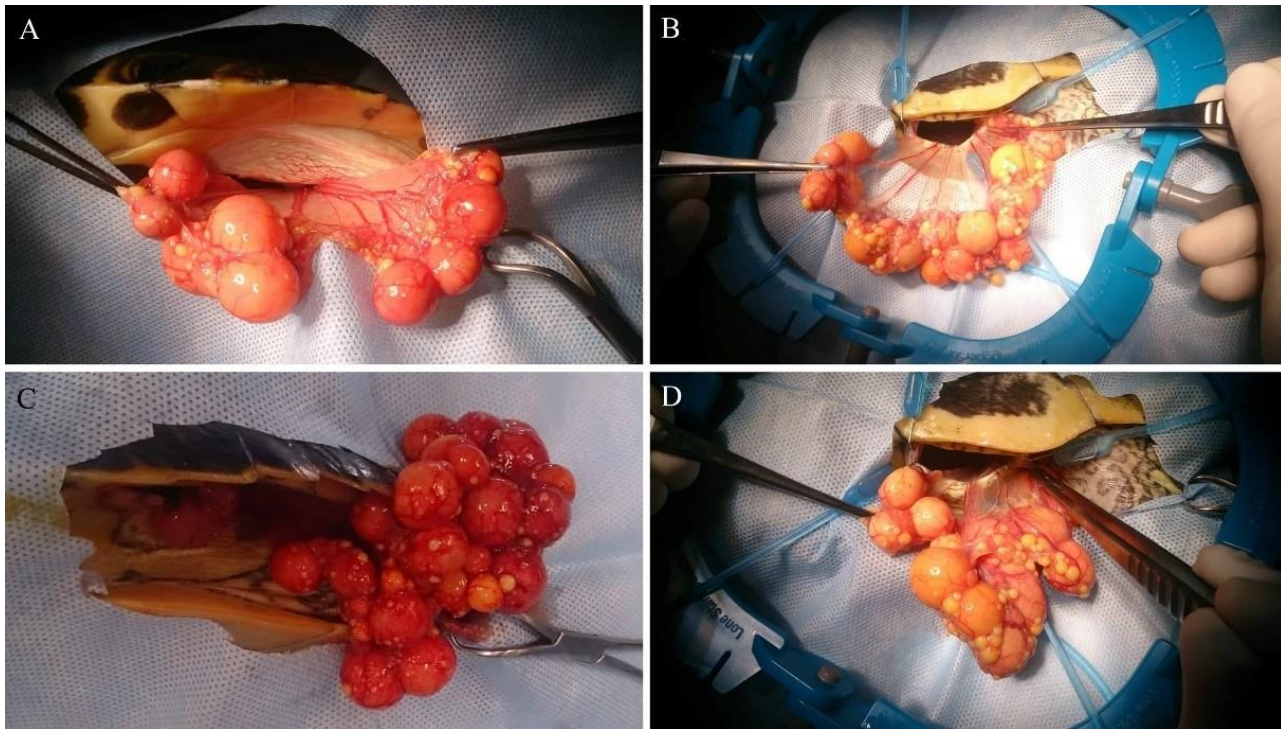


Figure 2. (A): Exteriorization of the left ovary from the left pre-moral fossa with the patient in right lateral recumbency. (B): Right ovary from the right pre-moral fossa with the patient in dorsal recumbency. (C): Right ovary from the left pre-moral fossa with the patient in right lateral recumbency. (D): Left ovary from the right pre-moral fossa with the patient in dorsal recumbency.

After the first ovary resection, the coelom was endoscopically inspected to identify the contralateral ovary. When possible, operative atraumatic forceps were used to grasp a portion of interfollicular tissue, and under endoscopic visualization, to apply gentle traction to it, drawing it to the incision and completely exteriorizing the ovary (Figure 2C,D) in order to perform the resection from the same surgical incision, in the same way as described above. For all groups, the second ovary resection time was recorded as described above.

The coelomic membrane and muscle aponeurosis were closed together with a 3.0 polydioxanone (PDS II, Ethicon, Johnson & Johnson, Pomezia, Italy) continuous suture pattern. The skin was closed with an everting horizontal mattress suture of the same material and covered with a thin layer of cyanoacrylate glue (Leukosan Adhesive, BSN Medical S.r.l., Agrate Brianza, Italy).

If extraction and resection of the second ovary were not feasible from a single surgical incision, access to the contralateral fossa was obtained, and surgery was performed as described above. In such cases, ease of identification would be recorded as 1 (Table 2).

Twenty minutes after closure, dexmedetomidine and midazolam were respectively reversed with an intravenous (IV) administration of atipamezole (Antisedan, Vetoquinol Italia S.r.l., Bertinoro, Italy) 1 mg/kg and flumazenil (Flumazenil, B. Braun Melsungen AG, Melsungen, Germany) 0.05 mg/kg.

A statistical analysis was performed using commercial statistical software (IBM SPSS statistics for Windows, Ver. 26.0). The Shapiro–Wilk test was applied to assess the normal distribution of the obtained values, and since the data were not normally distributed, a Mann–Whitney U test was applied to identify statistically significant differences (the null hypothesis being that no difference existed between the groups). Moreover, an ordinal logistic regression was applied to investigate the correlation between BW and ease of access to the coelom.

3. Results

Of the 27 turtles that met the inclusion criteria and underwent the procedure, three were excluded from the study after coelomic inspection: one animal had diffused coelomitis with hepatic granulomas, and two others revealed the presence of non-calcified eggs in the oviducts, which were not detected on the preoperative radiographic survey.

Regardless of the type of recumbency, the surgical access through the prefemoral fossa was easily achieved; this phase required less than 2 min (score 4 and 5), except in three cases (Table 3). No statistically significant differences were found between the scores describing the access to the coelom in both recumbencies, using a Mann–Whitney U test ($p = 0.92$). The median score of surgical access obtained in dorsal recumbency was 4 with an interquartile range (IQR) of 1, and 4.5 with an IQR of 1 for lateral recumbency.

Table 3. The score record regarding ease of access to the coelom and ease of identification of the ovary opposite to the surgical incision.

Recumbency	se of Access (score)	Number of Subjects/12	ntification Second Ovary (Score)	Number of Subjects/12
Lateral	1	0	1 *	2
	2	0	2	4
	3	2	3	3
	4	4	4	2
	5	6	5	1
Dorsal	1	0	1*	1
	2	0	2	3
	3	1	3	2
	4	6	4	3
	5	5	5	3

* In all cases that scored 1 in ease of identification of the second ovary, the ovary was identified but impossible to exteriorize from the first surgical breach.

The median BW was 1480 g (SD \pm 382.5 g; range 925–2200 g). A positive correlation was identified between BW and the access score by analyzing the data with ordinal logistic regression. As BW increased, the score decreased; the weight was therefore predictive of the difficulty in creating access to the coelom (Table 4).

Table 4. Correlation between the access score and weight.

<u>Coelom Access Score</u>	<u>Mean BW (g)</u>	<u>Standard Deviation</u>
3	1788.3	357.5
4	1592.5	489
5	1206.3	315.4
Total	1440	447.2
<i>p</i> value *	0.013	

BW= body weight. * analyzed with ordinal logistic regression.

In all cases, the ovary on the same side as the surgical incision could be directly identified without endoscopic assistance, while the contralateral ovary was more difficult to locate in both recumbencies, with its visualization often only being possible through the membrane, requiring more manipulation of the surrounding structures. Animals in lateral recumbency had a median score of 2.5 with an IQR of 2, while in dorsal recumbency a median score of 3.5 with an IQR of 3 was recorded. Differences between the recumbencies were not statistically significant, as assessed using a Mann–Whitney U test ($p = 0.23$).

Regarding the removal of the ovary ipsilateral to the surgical access, from first grasping the interfollicular tissue to the complete resection of the mesovarium, it took a median time of 6.5 min (an IQR of 6) in lateral recumbency and 7 min (an IQR of 6) in dorsal recumbency (Table 5). The contralateral ovary’s median time of asportation was 3.5 min (an IQR of 7) in lateral recumbency and 4 min (an IQR of 5) in dorsal recumbency; the time of removal of the second ovary was not calculated for those animals that required a bilateral approach (Table 5). The median surgery time of the whole procedure was 39 min (an IQR of 19). In dorsal recumbency, the median surgery time was 39 min (an IQR of 29), and in lateral recumbency it was 39.5 min (an IQR of 15). No statistically significant difference was found between the two types of recumbency regarding the first ovary removal time ($p = 0.52$), second ovary removal time ($p = 0.72$), or total surgical time ($p = 0.47$), analyzed with the Mann–Whitney U test (Tables 5 and 6).

Table 5. Surgical timing of ovary removal.

		Lateral Recumbency	Dorsal Recumbency	Total
First ovary removal time	Median	6.5	7.0	6.5
	(minutes) IQR	6.0	6.0	6.0
	<i>p</i> value *		0.52	
Second ovary removal time **	Median	3.5	4.0	4.0
	(minutes) IQR	7.0	5.0	6.0
	<i>p</i> value *		0.72	

IQR= interquartile range. * analyzed with Mann–Whitney U test; ** animals that required a bilateral approach were not included in the calculation.

Table 6. Total surgical timing.

	Median (minutes)	Lateral Recumbency	Dorsal Recumbency	Total
	15.0	39.5	39.0	39.0
	29.0			
	19.0			
	<i>p</i> value *	0.47		

* analyzed with Mann–Whitney U test.

In three cases (12.5%; one case in dorsal recumbency and two in lateral recumbency), a change in recumbency was necessary to remove the second gonad, it being necessary to switch the surgical access to the contralateral prefemoral fossa to carry out the surgery.

4. Discussion

No difference was observed between lateral and dorsal recumbency regarding ease of access to the coelom, ease of identification of the contralateral ovary, surgical times, or necessity to select a bilateral access. A single incision allowed the removal of both ovaries in 87.5% of the subjects, while the remaining animals needed a second incision due to a shorter and less extensible mesovarium, probably caused by seasonally related factors, which did not allow full exposure of the contralateral ovary. A positive correlation between BW and difficulty accessing the coelom was found.

Animals were selected from a limited geographical area to minimize environment-related variables, in order to have a more homogeneous population regarding ovarian cycles. Further distinction regarding the subspecies (*Trachemys scripta scripta*, *T.s. elegans*, *T. s. troostii*) was not considered necessary for the present work.

To assess the ease of access to the coelom cavity, a previously published scoring system¹³ was modified and applied in our study; modifications were necessary since, in the original paper, access to the coelom was gained with the placement of an operating sheath and the replacement of the obturator with a telescope, thus requiring more time compared to a plain surgical access technique, such as the one applied in the present work. Out of 24 animals, 21 had excellent-to-good ease of access (requiring less than 2 min), and the other three required up to 4 min (a score of 3). No statistical difference was found between the two groups, but a positive correlation was found between the BW of the animals and the difficulty to access the coelom. This can be explained by the fact that bigger animals have deeper prefemoral fossae (thus making tissue and instrument manipulation more difficult), and more abundance of subcutaneous tissues that need to be delicately dissected in order to avoid iatrogenic trauma to the coelomic organs. The left approach with right lateral recumbency and the right approach with dorsal recumbency were selected because they are more comfortable for a right-handed surgeon.

Ease of identification of the ovary opposite to the surgical incision was assessed by adapting a previously published scoring system;¹³ in the original paper, the scoring system was used to assess ease of identification of the coelomic organs, while in this case, the authors felt the necessity to slightly modify it in order to better adapt it to a large and mobile organ such as the chelonian mature ovary.

The mean total surgery time was consistent with previously published data,^{2,5-9} with no significant difference between the two recumbencies. In both recumbencies, removal of the first ovary took longer than the second, probably because the removal of the first ovary made more room inside the coelom, making it easier to completely exteriorize the second.

In 21 out of 24 animals (87.5%), bilateral oophorectomy could be achieved from a single incision. The three animals that required a bilateral approach underwent surgery in late August and early September. In these subjects, both ovaries were found to be smaller, and despite the fact that the contralateral ovary could be nonetheless easily identified and located, it could not be completely exteriorized due to the shorter length and lower extensibility of the mesovarium—thus the need for a second incision. The total surgery times in these subjects were 71, 40, and 68 min, and these were not excluded from the statistical analysis. A decrease in the mass of ovarian follicles from July to October has been described in wild specimens of *T. scripta elegans* in Southern Europe,¹⁵ but in our experience, such a decrease was observed only in late summer. This could suggest that in humid continental climates such as Po Valley, the best time to perform elective oophorectomy in this species is from middle–late spring to mid-August.

Further studies may be useful to also ensure the validity of our findings in other aquatic species with different anatomical features—for example, the Florida red-bellied cooter (*Pseudemys nelsoni*, which displays a high dome-shaped shell) or box turtles (*Terrapene* spp., *Cuora* spp.).

5. Conclusions

The results of this study are consistent with the previously published statement that the recumbency for prefemoral ovariectomy in pond sliders can be indifferently chosen based on the preference of the surgeon, on the animal's pathophysiological status (e.g., necessity for unilateral oophorectomy), or on the necessity to perform other procedures concurrently with ovariectomy (e.g., investigation of right or left liver lobe).

Author Contributions: Conceptualization, E.B. and S.R.; Data curation, E.B. and G.A.; Formal analysis, E.B. and V.B.; Investigation, E.B. and G.A.; Methodology, E.B., G.A., E.L. and S.R.; Project administration, E.B. and S.R.; Resources, E.B. and S.R.; Supervision, S.R.; Validation, V.B.; Writing—original draft, E.B. and G.A.; Writing—review and editing, G.A., E.L., V.B. and S.R. All authors have read and agreed to the published version of the manuscript. **Funding:** This research received no external funding. **Conflicts of Interest:** The authors declare no conflict of interest.

References

1. Skyes, J.M., IV. Updates and practical approaches to reproductive disorders in reptiles. *Vet. Clin. Exot. Anim.* **2010**, *13*, 349–373.
2. Knafo, S.E.; Divers, S.J.; Rivera, S.; Cayot, L.J.; Tapia-Aguilera, W.; Flanagan, J. Sterilisation of hybrid Galapagos tortoises (*Geochelone nigra*) for island restoration. Part 1: Endoscopic oophorectomy of females under ketamine-medetomidine anaesthesia. *Vet. Rec.* **2011**, *168*, 47, doi:10.1136/vr.c6520.
3. Proença, L.M.; Divers, S.J. Coelioscopic and endoscope-assisted sterilization of chelonians. *Vet. Clin. N. Am. Exot. Anim. Pr.* **2015**, *18*, 555–570, doi:10.1016/j.cvex.2015.05.004.
4. Stahl, S.J. Surgery-reproductive tract. In *Mader's Reptile and Amphibian Medicine and Surgery*, 3rd ed.; Divers, S.J., Stahl, S.J., Eds.; Elsevier Inc.: St. Louis, MO, USA, 2019; pp. 1077–1089.
5. Innis, C.J.; Hernandez-Divers, S.; Martinez-Jimenez, D. Coelioscopic-assisted prefemoral oophorectomy in chelonians. *J. Am. Vet. Med Assoc.* **2007**, *230*, 1049–1052, doi:10.2460/javma.230.7.1049.
6. Di Girolamo, N.; Mans, C. Reptile soft tissue surgery. *Vet. Clin. N. Am. Exot. Anim. Pr.* **2016**, *19*, 97–131, doi:10.1016/j.cvex.2015.08.010.
7. Nutter, F.B.; Lee, D.D.; Stamper, M.A.; Lewbart, G.A.; Stoskopf, M.K. Hemiovariosalpingectomy in a loggerhead sea turtle (*Caretta caretta*). *Vet. Rec.* **2000**, *146*, 78–80.
8. Mans, C.; Sladky, K.K. Diagnosis and management of oviductal disease in three red-eared slider turtles (*Trachemys scripta elegans*). *J. Small Anim. Pr.* **2012**, *53*, 234–239, doi:10.1111/j.17485827.2011.01172.x.
9. Takami, Y. Single-incision, prefemoral bilateral oophorosalingectomy without coelioscopy in an Indian star tortoise (*Geochelone elegans*) with follicular stasis. *J. Vet. Med Sci.* **2017**, *79*, 1675–1677, doi:10.1292/jvms.17-0182.
10. Wüst, E.; Divers, S.J. Surgery-chelonian prefemoral coeliotomy. In *Mader's Reptile and Amphibian Medicine and Surgery*, 3rd ed.; Divers, S.J., Stahl, S.J., Eds.; Elsevier Inc.: St. Louis, MO, USA, 2019; pp. 1054–1056.
11. Campbell, T.W. Hematologic techniques in lower vertebrates. In *Exotic Animal Hematology and Cytology*, 4th ed.; Campbell, T.W., Ed.; John Wiley & Sons Inc.: Ames, IO, USA, **2015**; pp. 199–205.
12. Klaphake, E.; Gibbons, P.M.; Sladky, K.K.; Carpenter, J.W. Reptiles. In *Exotic Animal Formulary*, 5th ed.; Carpenter, J.W., Ed.; Elsevier Inc.: St. Louis, MO, USA, **2018**; pp. 81–166.
13. Divers, S.J.; Stahl, S.J.; Camus, A. Evaluation of diagnostic coelioscopy including liver and kidney biopsy in freshwater turtles (*Trachemys scripta*). *J. Zoo Wildl. Med.* **2010**, *41*, 677–687, doi:10.1638/2010-0080.1.

14. Sladky, K.K.; Mans, C. Clinical anesthesia in reptiles. *J. Exot. Pet Med.* **2012**, *21*, 17–31, doi:10.1053/j.jepm.2011.11.013.
15. Perez-Santigosa, N.; Díaz-Paniagua, C.; Hidalgo-Vila, J. The reproductive ecology of exotic *Trachemys scripta elegans* in an invaded area of Southern Europe. *Aquat. Conserv. Mar. Freshw. Ecosyst.* **2008**, *18*, 1302–1310, doi:10.1002/aqc.974.

Determination of efficacy of single and double 4.7 mg deslorelin acetate implant on the reproductive activity of female pond sliders (*Trachemys scripta*)

Edoardo Bardi^{1*}, Martina Manfredi¹, Raffaella Capitelli², Emanuele Lubian³, Alessandro Vetere⁴, Alessandro Montani⁵, Tommaso Bertoni⁶, Elisa Talon², Gabriele Ratti¹, Stefano Romussi¹

¹ Department of Veterinary Medicine, University of Milan, via dell'Università 6, 26900 Lodi, Italy

² Csv-Labvet, via J. Kennedy 10, 23873 Missaglia (LC), Italy

³ Veterinary Clinical and Husbandry Centre (CCVZS), University of Milan, via dell'Università 6, 26900 Lodi, Italy

⁴ Clinica Veterinaria Modena Sud, piazza dei Tintori 1, 41057 Spilamberto (MO), Italy

⁵ Faculty of Veterinary Medicine, University of Teramo, Località Piano d'Accio, 64100 Teramo, Italy

⁶ MySpace Lab, Department of Clinical Neuroscience, University of Lausanne, rue du Bugnon 21, 1011 Lausanne, Switzerland

***Corresponding Author**

Address correspondence to: Edoardo Bardi DVM, PhD Student, via dell'Università 6, 26900 Lodi, Italy.

E-mail: edoardo.bardi@unimi.it

Telephone: +39 389 8298365

Simple Summary

North American pond sliders (*Trachemys scripta*) are invasive alien species that, following the release of pet specimens in the wild over the decades, have established breeding populations outside their native habitat, with detrimental effects on local biodiversity. Their commerce and breeding have been recently banned in the European Union, and national programs are being introduced by Union Members to eradicate and control their presence. Among other means for population control, the use of long-acting drugs for chemically induced infertility could be a promising tool to prevent reproduction of these animals. Efficacy of single and double intramuscular deslorelin acetate implants has been investigated during a one-season follow up: plasmatic sexual hormones concentration and morphometric evaluation of ovarian activity by computed tomography have been performed about every thirty days to detect differences between control group (no implant), single-implant group and double-implant group. Results show no inhibition of reproductive activity for the ongoing reproductive season, but suggest possible infertility starting from the following season.

Abstract

The use of long-acting GnRH-agonists to suppress fertility has been poorly investigated in reptiles, and the few available studies show inconsistent results. Efficacy of single and double intramuscular 4.7 mg deslorelin acetate implants in captive pond sliders (*Trachemys scripta*) has been investigated, with 20 animals divided into three groups: one single-implant groups (6 animals), one doubleimplant group (6 animals) and one control group (no implant). During one reproductive season (March to October), plasmatic concentration of sexual hormones (estradiol, progesterone and testosterone) and ovarian morphometric activity via computed tomography were monitored about every 30 days. A significative decrease in the number of phase-II ovarian follicles was detected in the double-implant group when compared with the control group, but no significant difference was noted regarding the number of phase-III and phase-IV follicles, egg production, and sexual hormones plasmatic concentration. Results show that neither a single or double deslorelin acetate implant can successfully inhibit reproduction in female pond sliders during the ongoing season, but the lower number of phase-II follicles in the double-implant group can possibly be associated to a reduced fertility in following seasons.

Keywords

Contraception; deslorelin acetate; GnRH-agonist; pond slider; reptile; *Trachemys scripta*; turtle

1. Introduction

American pond sliders (*Trachemys scripta*) are among the most common pet turtles all over the world since the 1970's, but as consequence of their frequent release in the wild, they are considered invasive aliens species in many countries. With well-established populations outside their native distribution,¹⁻⁴ they pose a threat for native species⁵⁻¹¹ and possible risks for domestic animal and human health.¹²⁻¹⁴ For these reasons, *T. scripta* is listed among the 100 most invasive species by the International Union for Conservation of Nature (IUCN)¹⁵ and its breeding and commerce have been recently prohibited inside the European Union, with Regulations (EU) 1143/2014 and 1141/2016, leading to the necessity for means of population control. Synthetic Gonadotropin-Releasing Hormone (GnRH) analogues are used to inhibit sexual hormones production, with deslorelin acetate (DA) being one of the most common GnRH-agonists in veterinary practice. Its mechanism of action consists in a powerful stimulation of the pituitary gland to produce gonadotropins (flare-up phase) and consequent long-term down-regulation of pituitary receptors for endogenous GnRH, leading to temporary suppression of fertility.¹⁶⁻¹⁸

In mammal practice, DA implants are regularly used in dogs, cats and ferrets,¹⁸ but there are species in which they showed no efficacy, such as primates and marsupials.^{19,20} In avian practice, DA implants are rarely employed, and usually to medically reduce aggressivity or treat sex-related disorders such as excessive eggs laying.¹⁸ Depending on the species, efficacy and duration can be extremely variable, ranging from the complete elimination of sexual behavior to no efficacy at all, lasting from one to 10 months.^{18,21-25} In reptiles, GnRH-agonists have been poorly investigated so far: in lizards, suppression of gonadic activity with DA slow-release implants has been attempted in female *Iguana iguana*, *Chamaeleo calypttratus* and *Eublepharis macularius*, with sign of efficacy reported only in iguanas,^{18,26-28} and to successfully reduce aggressivity in a male *Pogona vitticeps*.²⁹ Regarding chelonians, annual applications of DA implants reduced serum testosterone levels after fourth treatment in a male *Chelonia mydas*;³⁰ DA was successfully used to treat chronic ovodeposition problems in a *Testudo graeca* up to 24 months after implantation.³¹ In *T. scripta*, subcutaneous implantation showed no statistical differences in serum hormonal concentration or reproductive activity between case and control groups both in male and female,^{26,32} but males showed a transient increase in testosterone levels two weeks after implantation.³²

The purpose of the present work is to evaluate the effects of single and double intramuscular DA slow-release implants on ovarian and reproductive activity of mature female pond sliders, by serial measurements of hormonal plasmatic concentrations and morphometric evaluations of the ovaries.

2. Materials and methods

Twenty adult, clinically healthy female sliders (minimum plastron length 18 cm)³³ from Lombardy, Italy, with a history of correct outdoor management were enrolled for the study. In mid-March 2019, each animal received a complete physical examination and a radiography to rule out egg retention from the previous reproductive season. Turtles were individually marked with a nanochip (Nanochip for Exotic Animals, Therapet Bioforlife, Milano, Italy) in the left pectoral muscle, and randomly assigned to Group 1 (control group, 8 animals), 2 or 3 (6 animals each): animals assigned in Group 2 received a single 4.7 mg DA implant (Suprelorin 4.7 mg, Virbac Italia, Milano, Italy) in the right pectoral muscle; animals assigned to Group 3 received a double 4.7 mg DA implant in the right and left pectoral muscle. Time points were set every month, from late March 2019 to early October 2019, for a total of 7 time points. In between monthly evaluations, the animals were randomly housed in groups of 4 animals in outdoor semi-natural conditions, with possibility to lay eggs if needed; in each group, a healthy adult male was added to properly stimulate the females.

Ovarian morphometric evaluation

From T0 (March 29th 2019, prior to DA implantation) to T6 (October 4th 2019), a full-body helical CT scan (GE BrightSpeed Elite 16 slice – slice thickness 1.25 mm, 0.938 pitch, 180 mAs, 120 kVp) was performed each month for ovarian morphometric evaluation. Sliders were placed in ventral recumbency on a flat surface during images acquisition. Images were reconstructed using both bone and soft tissue algorithms. The soft tissue algorithm series (window width: 400, window level: 40) was used for measurements on an open-source DICOM viewer (Horos v.3.3, <https://www.horosproject.org>). Total and differential count for follicles belonging to classes II, III and IV of the Moll and Legler classification^{3,33} was performed, and the presence and number of eggs were recorded.

Plasmatic hormones concentration

From T0 (March 29th 2019, prior to DA implantation) to T6 (October 4th 2019), a blood sample from the cervical plexus was obtained from each animal and stored in lithium-heparine test tube, plasma was immediately separated by centrifugation and frozen at -20°C. Samples were processed no more than 15 days after collection. Estrogen (17 β -estradiol, E₂) and progesterone (P₃) plasmatic concentration were measured for every time point. Testosterone (T) plasmatic concentration was measured at T0, T4 (July 27th 2019) and T5 (August 31st 2019). Fluorescence Polarization Immunoassay (FPIA, competitive enzyme immunoassay) technology of the Tosoh 600 Analyzer was used to evaluate plasma E₂, P₃ and T concentration. The values of E₂ are expressed in pg/ml, P₃ in ng/ml and T in ng/dl.

Statistical analysis

The number of follicles and the concentration of hormones were compared between experimental groups through two-way mixed-design ANOVAs, with group as a between-subjects variables, and time as a within-

subjects variable. Due to the nature of the analysis, we had to exclude animals for which complete data was not available. Specifically, for the total number of follicles, four animals were excluded due loss at follow-up (2 animals in the single implant group, 2 in the control group), leaving 6 animals in the control group, 4 in the single implant group and 6 in the double implant group. Additionally, and only for T0, missing data from two animals in the control group was replaced by the global mean computed at T0 across the three groups. This was done to avoid losing data for the whole observation period, and since no intervention had taken place at T0 the groups could be assumed as homogeneous. After each ANOVA, we checked for the assumption of normality by running a Shapiro-Wilk test on the residuals. Statistical analyses were conducted through the R statistical software (version 4.0.2), using the afex package (<https://CRAN.Rproject.org/package=afex>, version 0.28-0) for ANOVAs.

Prior to running statistical analyses on hormone concentrations, a check was performed on the amount of missing or below threshold values, which was 67 % for E₂, 12.1 % for P₃ and 32 % for T. We therefore chose to exclude E₂ values from further analyses due to the amount of missing values. Moreover, we analyzed the distribution of T and P₃, and found the latter to be affected by outliers, with 95 % of the values below 1 ng/ml, and 5 % of the values going as high as 20 ng/ml. We therefore excluded from further analyses values above 1 ng/ml.

Ethical statement

All applicable international, national, and/or institutional guidelines for the care and use of animals were followed. The protocol for care, handling, and sampling of animals defined in the present study was reviewed and approved by the University of Milan Animal Care and Use Committee (protocol no. 69/19).

3. Results

Values regarding plastron length (PL), body weight (BW) and age were normally distributed, according to the Shapiro-Wilk test, both in the total population and inside each group. Mean PL was 19.97 cm ± 1.2 standard deviation (SD), mean (BW) was 1.37 kg ± 0.26, and mean age was 11.5 years ± 2.5. No significant difference was recorded between the three groups using t Student test.

As a first analysis, we run a statistical comparison between groups on the total number of eggs laid during the observation period. Since the distribution of the number of eggs was strongly non normal, Wilcoxon signed-rank tests were used. We found no significant difference ($p = 0.57$) between the control (mean = 6.17 ± 7.6 SD) and the single implant (mean = 13.5 ± 16.6 SD) group, and a marginally significant ($p = 0.053$) difference between the control and the double implant group, with animals in the double implant group laying significantly more eggs (mean = 18.5 ± 10.8 SD) than in the single implant group (Figure 1).

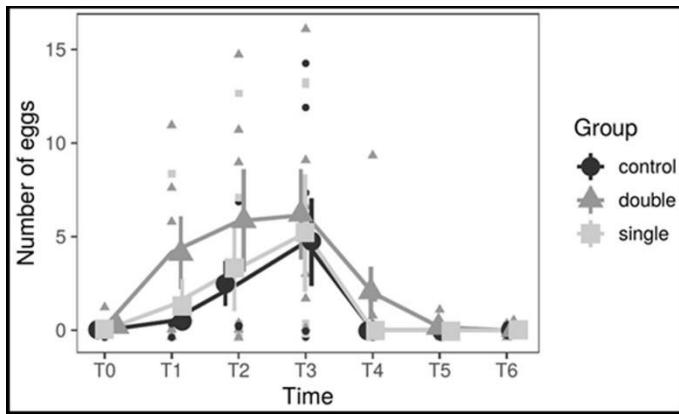


Figure 1 - number of eggs by experimental group and date. Large dots represent means by group and timepoint, and vertical bars represent standard errors.

Focus was put on the total number of follicles of stages II, III IV. In order to evaluate differences between groups over the whole observation period, a two two-way ANOVAs

was

run contrasting the control group to the single or double implant group.

A significant group*time interaction would therefore indicate that the variation in time of the number of follicles is different between the compared groups, suggesting an effect of our intervention. The first comparison, control VS single implant, yielded no significant results for the group*time interaction ($p = 0.85$). As confirmed by visual inspection of the graphs (Figure 2), the single implant group seems to start with a slightly lower number of follicles but decreases only slightly across the observation period in a similar manner to the control group. When running the same comparison against the double implant group, instead, we found a significant group*time interaction ($F(6,60) = 3.06, p = 0.011$). A Shapiro-Wilk test run on the residuals failed to reject the normality hypothesis ($p = 0.065$), confirming the validity of the analysis, and the result holds also when applying Greenhouse-Geisser and Huynh-Feldt Corrections for Departure from Sphericity ($p = 0.043$). The two groups have matching values until T2, then the double implant group has a sharp decrease, while the control group decreases only moderately, so the result is not driven by preexisting differences (Figure 2). In order to assess this effect quantitatively, we divided the observation period in two (pre: until T3 included, post: after T3), assuming T3 as a watershed between first and further clutches of follicles,^{3,34} and computed the mean variation in the number of follicles for each animal. A decrease in the number of follicles was observed for all groups (control: -4.90 ± 1.15 , single implant: -2.19 ± 5.47 , double implant: -11.2 ± 1.59 , mean \pm S.E.M.), but the decrease in the double implant group was significantly larger than in the control group (Welch's ttest, $t(1, 9.12) = 3.21, p = 0.010$). The decrease in the control group did not differ significantly from the decrease in the single implant group ($p = 0.65$).

In order to better investigate the source of the observed differences, differential count for the three classes of follicles was performed (Figure 2).

We run the same analyses as for the number of follicles on T and P₃ concentration values, comparing both the single and the double implant group to the control group. The residuals were normally distributed (all Shapiro-Wilk p-values above 0.23), and comparison yielded significant results, with all p-values above 0.22 (Figure 3).

4. Discussion

Reproductive activity in reptiles is influenced by endogenous and exogenous factors. Species from temperate climates tend to be seasonal breeders, depending on environmental variables such as temperature,

photoperiod, and food availability;³⁵ for *T. scripta*, breeding season usually starts right after winter hibernation (March-May in the boreal hemisphere, depending on the geographic localization).

Hormonal regulation of reproductive cycle is similar to other vertebrates, relying on the hypothalamo-pituitary-gonadal axis: in female chelonians, under the influence of pulsatile hypothalamic secretion of GnRH, pituitary gland secretes gonadotropins (LH-like and FSH-like) to stimulate the ovaries to produce testosterone, estrogens and progesterone.³⁵⁻³⁶ In females, T plays a role in mating behavior and follicular development.³⁷ Estradiol is mainly secreted by the granulosa cells and is responsible for follicular development, vitellogenesis (yolk deposition, stimulating hepatic production of vitellogenic proteins) and ovulation, while P₃, like in mammals, is secreted by the corpora lutea during the post-ovulatory phase (and, occasionally, by the adrenal glands), contributing to maintaining pregnancy/egg formation;^{35,36,38,39} a surge in plasma concentration immediately before ovulation suggests that P₃ may play a role in the positive feedback regulation of the LH peak in turtles.⁴⁰⁻

42

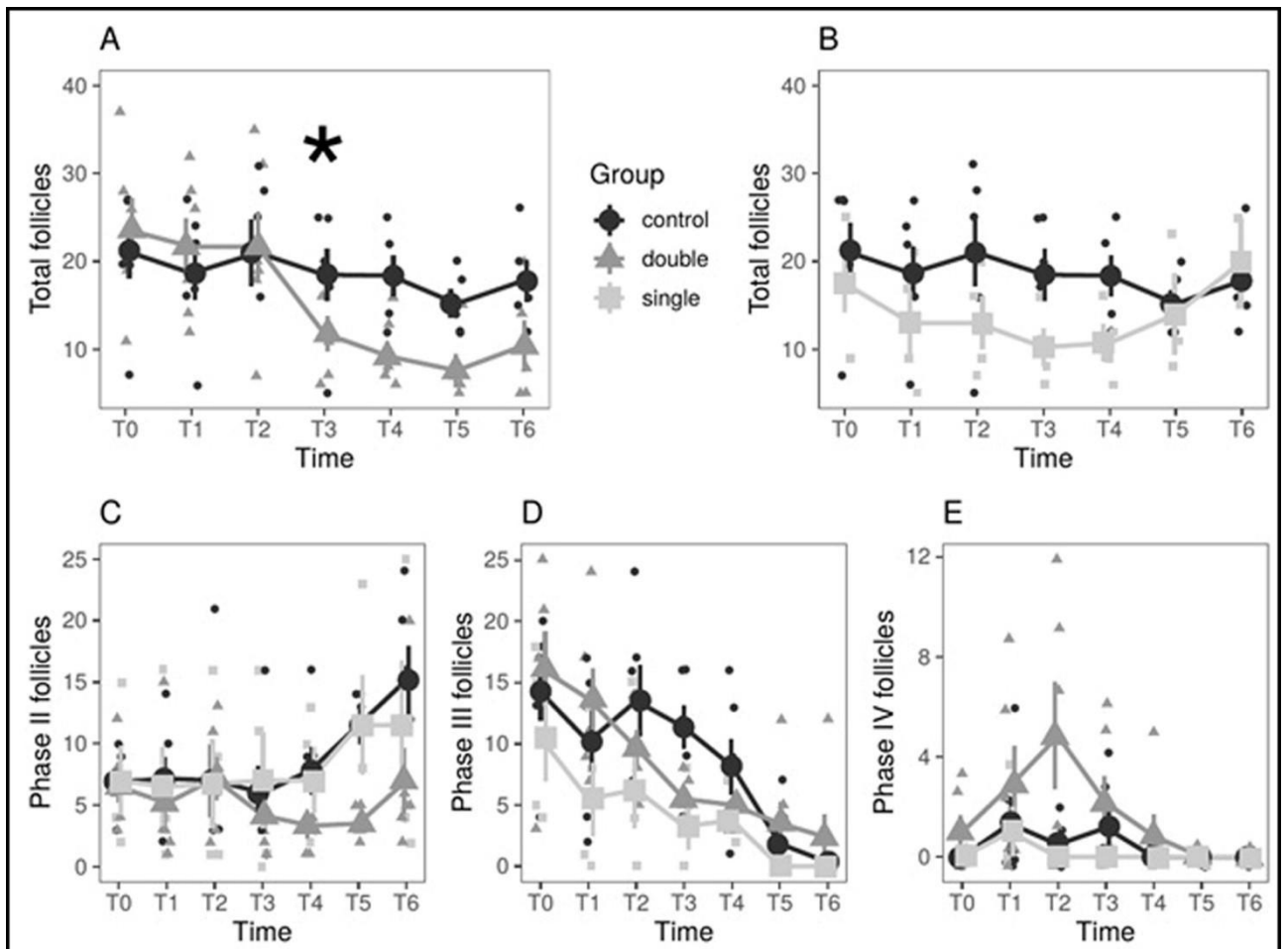


Figure 2 - comparison of the number of follicles between experimental groups and across timepoints. **A, B:** comparison between control and double (A) or single (B) implant group, respectively. **C, D, E:** comparison between the three experimental groups for follicles in phase II (C), III (D) and IV (E) separately. In all panels, large dots represent means by group and timepoint, and vertical bars represent standard errors.

Temperate climate turtles tend to display a postnuptial reproductive cycle,³⁴ meaning that full follicular development (end of vitellogenesis) is achieved in autumn right before hibernation, during which there is no further activity, and after which the animals are immediately ready to mate; some species like *Crysemys picta* show vitellogenic activity both in spring and autumn.⁴³ Deposition usually takes place in summer (late June to early August) and, depending on environmental and individual factors, one or two more depositions can take place from August to October; if a single clutch is laid, ovarian follicles decrease in size during deposition period, and vitellogenesis starts again in late summer and autumn.^{3,34}

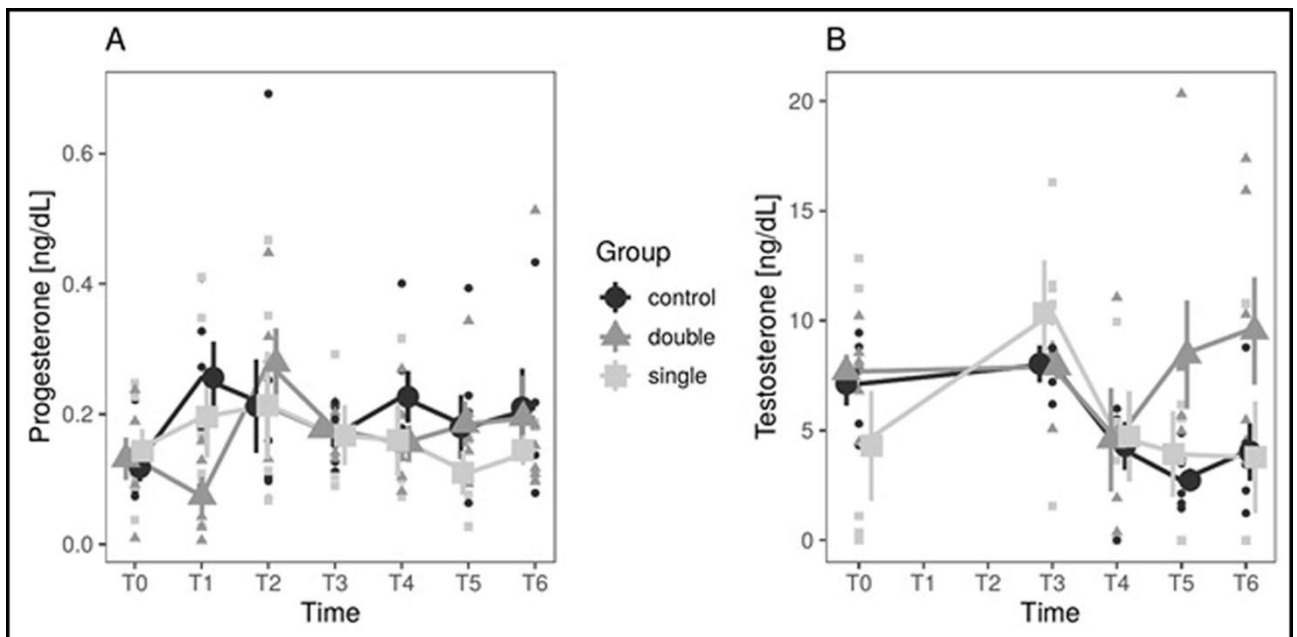


Figure 3 - hormone concentration values in the different experimental groups and measurement dates. Progesterone values are shown in panel A while testosterone values are shown in panel B. Large dots represent means by group and timepoint, and vertical bars represent standard errors.

Determining the stage of follicular development is not straightforward, as in the examined species there are no available data associating follicular size/radiodensity to their histological structure; in 1971 Moll and Legler proposed a four-classes classification according to their diameter in *Trachemys venusta*: I <7mm, II 7-13mm, III 14-20 mm, IV >20mm.^{3,33} Follicles from classes III and IV are considered to be late-vitellogenesis and pre-ovulatory stages,³ as in other species the biggest follicles are demonstrated to be the pre-ovulatory ones.⁴⁴ Variations in ovarian mass were described in wild *T. scripta* in Spain,³ with a decrease of total follicle number from May to July, a plateau from July to September, and an increase in November before winter hibernation. In our study, a similar pattern was observed for all the three groups except for what concerns the pre-hibernation increase, since our last evaluation was performed at the beginning of October; this was decided in order not to stress out the animals in the period immediately preceding hibernation. In the present study, the difference in the total number of follicles between control and double-implant group was largely dependent on the variations of stage II follicles, with a significant decrease at T3 (end of June) and slight increase at T6 in

the double-implant group; stage III follicles were observed to progressively decrease in all three groups without significant differences, while the double-implant group showed a spike in the number of stage IV follicles at T2 (early June, 65 days after implant administration), suggesting a flare-up effect of the DA implants on the hypothalamus-pituitarygonadal axis. Since stage II follicles are assumed to be related to the clutches of the following year,³ it can be hypothesized that the double implant could decrease or even suppress fertility starting from the second reproductive season after administration.

No statistical difference was found between the single-implant group and the others, but this can also be due to the fact that this group suffered the loss of two subjects at T3 and T4, thus depriving the group of statistical power.

Although not statistically significant, total number of eggs in the double-implant group was higher than the control group ($p=0.53$), enhancing the hypothesis of a moderate flare-up effect of the DA implant.

The hormonal pattern is poorly described in pond sliders, but extrapolations can be made from other species: for example, high plasmatic T concentration is observed in spring right before ovulation of the first clutch of follicles in *Sternotherus odoratus* and *Terrapene carolina*,^{40,45} while in *Graptemys flavimaculata*, T shows an increase in summer as well, corresponding to second clutches ovulations;⁴⁶ P₃ and E₂ increase in periovulatory periods, with P₃ showing a small plateau phase right after ovulation, and E₂ highly increases in late summer and autumn enhancing follicular growth for the following season.³⁴⁻⁴⁰ In *Chrysemys picta*, E₂ levels are low throughout the season except for one/two pre-ovulatory spike(s), when also T and P₃ rise accordingly, only to rapidly drop after ovulation. Some short peaks of E₂ can also be associated to the production of small follicles in the ovary.⁴⁷ In the present study, FPI was elected instead of the more described radioimmunoassay:^{36,45,46,48,49} chemiluminescent immunological assays are among the methods currently used to evaluate plasma hormones concentration in domestic animals⁵⁰ and, since steroid hormones are well conserved among the vertebrates,³⁶ FPI was chosen by virtue of its lower costs and non-requiring of radioactive isotopes.⁵¹ In the present study, hormonal values were not a reliable tool to assess differences between the groups. The unavailability of most values for E₂ (and consequent inadequacy for statistical analysis) can be explained by intrinsic features of this hormone such as physiologically low hematic concentration,⁴⁷ and extrinsic difficulties related both to the sampling and/or processing. Variations in results obtained for E₂ are a well-known phenomenon, with methodologic and calibration differences along with poor low-end sensitivity advocated to be the major cause.⁵² Another variable to consider is that changes in plasma hormone concentration in turtles may occur within a few hours, and that stress derived from manipulation may alter the plasma steroid levels;^{36,45} in the present study, all samples were obtained in the morning, but it cannot be excluded that circadian or stress-induced variations may have altered the results.

No differences were found between the groups regarding the overall pattern of P₃ and T, but some punctual differences were recorded. Regarding P₃, a particularly low concentration was noted in the double-implant group at T1 (early May), preceding the above described spike in stage IV follicles and thus probably correlated to the hypothesized flare-up phase. Testosterone pattern showed a decrease starting at T3 (end of June), followed by a plateau phase in control and single-implant groups, while the double-implant group displayed an increase starting at T4 (end of July) until T6. Such an increase was not correlated to any significant variation in follicular pattern neither at T4, T5 or T6; hypothetically, the increase could be interpreted as a preovulatory surge but, lacking further evaluation in November to witness an increase in stage III and IV follicles, its biological meaning remains unclear.

5. Conclusions

Neither single or double deslorelin acetate implant was successful in suppressing gonadal activity and preventing reproduction in adult female pond sliders during a one-season follow-up. This result is consistent with previously published works.^{26,32} Morphometric evaluation of the ovaries by CT scan proved more useful than hormonal evaluation to monitor variations in the gonadal activity. Since partial effect was noted in the double-implant group, further studies with a longer follow-up and/or measurement of deslorelin plasmatic concentration are required to investigate the efficacy in further breeding seasons.

Aknowledgements

The authors thank Virbac Italia for donating the implants used in the present study. Virbac Italia had no role in the design, execution, interpretation, or writing of the study.

Author Contributions: Conceptualization, E.B., E.L., A.V and A.M.; Data curation, E.B., M.M. and R.C.; Formal analysis, T.B.; Investigation, E.B., M.M., R.C., E.L., E.T. and G.R.; Methodology, E.B., M.M. and R.C.; Project administration, E.B. and S.R.; Resources, S.R., M.M. and R.C.; Supervision, S.R.; Validation, M.M., R.C., and E.T.; Visualization: E.B. and T.B.; Writing—original draft, E.B., M.M., R.C. and T.B.; Writing—review and editing, E.L., A.V., A.M., G.R. and S.R. All authors have read and agreed to the published version of the manuscript. **Funding:** This research received no external funding.

Conflicts of Interest: The authors declare no conflict of interest.

References

1. Ferri, V.; Soccini, C. Riproduzione di *Trachemys scripta elegans* in condizioni seminaturali in Lombardia (Italia Settentrionale). *Natura Bresciana Ann. Mus. Civ. Sc. Nat.*, **2003**, *33*, 89-92.
2. Cadi, A.; Delmas, V.; Prévot-Julliard, A.C.; Joly, P.; Pieau, C.; Girondot, M. Successful reproduction of the introduced slider turtle (*Trachemys scripta elegans*) in the south of France. *Aquat. Conserv. Mar. Freshw. Ecosyst.*, **2004**, *14*, 237–246, <https://doi.org/10.1002/aqc.607>
3. Perez-Santigosa, N.; Diaz-Paniagua, C.; Hidalgo-Vila, G. The reproductive ecology of exotic *Trachemys scripta elegans* in an invaded area of southern Europe. *Aquatic. Conserv.: Mar. Freshw. Ecosyst.*, **2008**, *18*, 1302–1310, <https://doi.org/10.1002/aqc.974>
4. Global Invasive Species Database (2020) Species profile: *Trachemys scripta elegans*. <http://www.iucngisd.org/gisd/speciesname/Trachemys+scripta+elegans>, accessed 11/11/2020.

5. Cadi, A.; Joly, P. Competition for basking places between the endangered European pond turtle (*Emys orbicularis galloitalica*) and the introduced red-eared turtle (*Trachemys scripta elegans*). *Can. J. Zool.*, **2003**, *81*, 1392–1398, <https://doi.org/10.1139/z03-108>
6. Cadi, A.; Joly, P. Impact of the introduction of the red-eared slider (*Trachemys scripta elegans*) on survival rates of the European pond turtle (*Emys orbicularis*). *Biodivers. Conserv.*, **2004**, *13*, 2511-2518, <https://doi.org/10.1023/B:BIOC.0000048451.07820.9c>
7. Polo-Cavia, N.; Lopez, P.; Martin, M. Competitive interactions during basking between native and invasive freshwater turtle species. *Biol. Invasions*, **2010**, *12*, 2141-2152, DOI:10.1007/s10530-009-9615-0
8. Polo-Cavia, N.; Lopez, P.; Martin, M. Aggressive interactions during feeding between native and invasive freshwater turtle species. *Biol. Invasions*, **2011**, *13*, 1387-1396, DOI:10.1007/s10530010-9897-2
9. Pearson, S.H.; Avery, H.W.; Spotila, J.R. Juvenile invasive red-eared slider turtles negatively impact the growth of native turtles: Implications for global freshwater turtle populations. *Biol. Conserv.*, **2015**, *86*, 115-121. <https://doi.org/10.1016/j.biocon.2015.03.001>
10. Meyer, L.; Du Preez, L.; Bonneau, E.; Héritier, L.; Quintana, M.F.; Valdeón, A.; Sadaoui, A.; Kechemir-Issad, N.; Palacios, C.; Verneau, O. Parasite host-switching from the invasive American red-eared slider *Trachemys scripta elegans*, to the native Mediterranean pond turtle, *Mauremys leprosa*, in natural environments. *Aq. Inv.*, **2015**, *10*, 79-91, <http://dx.doi.org/10.3391/ai.2015.10.1.08>
11. Héritier, L.; Valdeón, A.; Sadaoui, A.; Gendre, T.; Ficheux, S.; Bouamer, S.; Kachemir-Issad, N.; Du Preez, L.; Palacios, C.; Verneau, O. Introduction and invasion of the red-eared slider and its parasites in freshwater ecosystems of Southern Europe: risk assessment for the European pond turtle in wild environments. *Biodivers. Conserv.*, **2017**, *26*, 1817-1843, <https://doi.org/10.1007/s10531-017-1331-y>
12. Hidalgo-Vila, J.; Díaz-Paniagua, C.; Pérez-Santigosa, N.; de Frutos-Escobar, C.; Herrero-Herrero, A. *Salmonella* in free-living exotic and native turtles and in pet exotic turtles from SW Spain. *Res. Vet. Sci.*, **2008**, *85(3)*, 449–452, 10.1016/j.rvsc.2008.01.011
13. Harris, J.R.; Neil, K.P.; Behravesh, C.B.; Sotir, M.J.; Angulo, F.J. Recent multistate outbreaks of human salmonella infections acquired from turtles: a continuing public health challenge. *Clin. Infect. Dis.*, **2010**, *50(4)*, 554-559, <https://doi.org/10.1086/649932>
14. Rzezutka, A.; Kaupke, A.; Gorzkowski, B. Detection of *Cryptosporidium parvum* in a Red-Eared Slider Turtle (*Trachemys scripta elegans*), a Noted Invasive Alien Species, Captured in a Rural Aquatic Ecosystem in Eastern Poland. *Acta Parasitol.*, **2020**, *65*, 768-773, doi: 10.2478/s11686020-00180-8
15. Lowe, S.; Browne, M.; Boudjelas, S.; De Poorter, M. 100 of the World's Worst Invasive Alien Species. IUCN/SSC Invasive Species Specialist Group (ISSG), Auckland, New Zealand. **2000**, http://www.issg.org/pdf/publications/worst_100/english_100_worst.pdf
16. Rispoli, L.A.; Nett, T.M. Pituitary gonadotropin-releasing hormone (GnRH) receptor: structure, distribution and regulation of expression. *Anim. Reprod. Sci.*, **2005**, *88(1-2)*, 57-74, DOI: 10.1016/j.anireprosci.2005.05.004
17. Goericke-Pesch, S. Long-term effects of GnRH agonists on fertility and behavior. *Reprod. Domest. Anim.*, **2017**, *52(2)*, 336-347, <https://doi.org/10.1111/rda.12898>
18. Schoemaker, N.J. Gonadotrophin-Releasing Hormone Agonists and Other Contraceptive Medications in Exotic Companion Animals. *Vet. Clin. Exot. Anim.*, **2018**, *21*, 443-464, DOI:10.1016/j.cvex.2018.01.011
19. Lunn, S.F.; Cowen, G.M.; Morris, K.D.; Fraser, H.M. Influence of the gonad on the degree of suppression induced by an LHRH agonist implant in the marmoset monkey. *J. Endocrinol.*, **1992**, *132*, 217–224, <https://doi.org/10.1677/joe.0.1320217>

20. Herbert, C.A.; Trigg, T.E.; Renfee, M.B.; Shaw, G.; Eckery, D.C.; Cooper, D.V. Effects of a gonadotropin-releasing hormone agonist implant on reproduction in a male marsupial, *Macropus eugenii*. *Biol. Reprod.*, 2004, 70, 1836–1842, <https://doi.org/10.1095/biolreprod.103.025122>
21. Cowan, M.L.; Martin, G.B.; Monks, D.J.; Johnston, S.D.; Doneley, R.J.; Blackberry, M.A. Inhibition of the reproductive system by deslorelin in male and female pigeons (*Columba livia*). *J. Avian Med. Surg.*, 2014, 28, 102–108, <https://doi.org/10.1647/2013-027>
22. Molter, C.M.; Fontenot, D.K.; Terrell, S.P. Use of deslorelin acetate implants to mitigate aggression in two adult male domestic turkeys (*Meleagris gallopavo*) and correlating plasma testosterone concentrations. *J. Avian Med. Surg.*, 2015, 29, 224–230, <https://doi.org/10.1647/2014-041>
23. Petritz, O.A.; Guzman, D.; Hawkins, M.G.; Kass, P.H.; Conley, A.J.; Paul-Murphy, J. Comparison of two 4.7-milligram to one 9.4-milligram deslorelin acetate implants on egg production and plasma progesterone concentrations in Japanese quail (*Coturnix coturnix japonica*). *J. Zoo Wildl. Med.*, 2015, 46(4), 789–97, <https://doi.org/10.1638/2014-0210.1>
24. Montani, A.; Collarile, T.; Selleri, P.; Speer, B.L.; Huynh, M.; Pecchia, F.; Di Girolamo, N. Evaluation of the efficacy and duration of single administration of 4.7-mg deslorelin acetate implant on follicular activity and plasma sex hormones in lovebird (*Agapornis* spp.) in a randomized controlled trial. Proceeding of 3rd International Congress for Avian, Reptile and Exotic Mammal, Venice, Italy, March 25th-29th, 2017, p. 508.
25. Summa, N.M.; Guzman, D.; Wils-Plotz, E.L.; Riedl, N.E.; Kass, P.H.; Hawkins, M.G. Evaluation of the effects of a 4.7-mg deslorelin acetate implant on egg laying in cockatiels (*Nymphicus hollandicus*). *Am. J. Vet. Res.*, 2017, 78(6), 745–51, <https://doi.org/10.2460/ajvr.78.6.745>
26. Grundmann, M., Möstl, E., Knotkova, Z., Knotek, Z. The use of synthetic GnRH agonist implants (deslorelin) for the suppression of reptile endocrine reproductive activity. Proceeding of 1st International Congress for Avian, Reptile and Exotic Mammal, Wiesbaden, Germany, April 20th-26th, 2013, p. 248.
27. Knotek, Z.; Cermakova, E.; Oliveri, M. Reproductive medicine in lizards. *Vet. Clin. Exot. Anim.*, 2017, 20, 411–438, doi: 10.1016/j.cvex.2016.11.006.
28. Cermakova, E.; Oliveri, M.; Knotkova, Z.; Knotek, Z. Effect of GnRH agonist (deslorelin) on ovarian activity in leopard gecko (*Eublepharis macularius*). *Vet. Med-Czech*, 2019, 64(5), 228230, <https://doi.org/10.17221/167/2018-VETMED>
29. Rowland, M.N. Use of a deslorelin implant to control aggression in a male bearded dragon (*Pogona vitticeps*). *Vet. Rec.*, 2011, 169, 127, <http://dx.doi.org/10.1136/vr.d2007>
30. Graham, K.M.; Mylniczenko, N.D.; Burns, C.M.; Bettinger, T.L.; Wheaton, C.J. Examining factors that may influence accurate measurement of testosterone in sea turtles. *J. Vet. Diagn. Invest.*, 2015, 1-8, <https://doi.org/10.1177/1040638715618989>
31. Iannaccone, M.; Ulivi, V.; Campolo, M. Use and duration of Deslorelin acetate in a *Testudo graeca* to solve a chronic reproductive disorder. Proceedings of Zoo and Wildlife Health Conference, Berlin, Germany, May 24th-27th, 2017, pp. 113-116.
32. Potier, R.; Monge, E.; Loucachevsky, T.; Hermes, R.; Göritz, F.; Rochel, D.; Risi, E. Effects of deslorelin acetate on plasma testosterone concentrations in captive yellow-bellied sliders (*Trachemys scripta* sp.). *Acta Vet Hung.*, 2017, 65, 440–445, <https://doi.org/10.1556/004.2017.041>
33. Ernst, C.H.; Lovich, J.E. *Turtles of the United States and Canada*, 2nd ed.; The John Hopkins University Press, Baltimore, MD, USA, 2009.
34. Blanvillain, G.; Owens, D.W.; Kuchling, G. Hormones and Reproductive Cycles in Turtles. In *Hormones and Reproduction of Vertebrates. Volume 3: Reptiles*; Norris, D.O., Lopez, K.H., Eds.; Academic Press: London, UK, 2011; 277-303.

35. Stahl, S.J.; DeNardo, D.F. Theriogenology. In *Mader's Reptile and Amphibian Medicine and Surgery*, 3rd ed.; Divers, S.J., Stahl, S.J., Eds.; Elsevier Inc.: St. Louis, MO, USA, **2019**; pp. 849-893.
36. Licht, P. Endocrine patterns in the reproductive cycles of turtles. *Herpetologica*, **1982**, *38*, 516-1, https://www.jstor.org/stable/3892361?seq=1#metadata_info_tab_contents
37. Boyer, T.H.; Innis, C.J. Chelonian Taxonomy, Anatomy and Physiology. In *Mader's Reptile and Amphibian Medicine and Surgery*, 3rd ed.; Divers, S.J., Stahl, S.J., Eds.; Elsevier Inc.: St. Louis, MO, USA, **2019**; pp. 31-49.
38. Jones, S. Hormonal Regulation of Ovarian Function in Reptiles. In *Hormones and Reproduction of Vertebrates. Volume 3: Reptiles*; Norris, D.O., Lopez, K.H., Eds.; Academic Press: London, UK, **2011**; pp. 89-115.
39. Oliveri, M.; Zampetti, M.; Knotek, Z. Fisiopatologia della riproduzione. In *Medicina e Chirurgia dei Cheloni*; Spadola, F., Di Giuseppe, M., Morici, M., Oliveri, M., Eds.; Genoma srl, Santa Teresa di Riva, Italy, **in press**.
40. McPherson, R.J.; Boots, L.R.; MacGregor, R.; Marion, K.R. Plasma steroids associated with seasonal reproductive changes in a multiclutched freshwater turtle, *Sternotherus odoratus*. *Gen. Comp. Endocrinol.*, **1982**, *48(4)*, 440-451, DOI:10.1016/0016-6480(82)90179-4
41. Etches, R.J.; Petitte, J.N. Reptilian and avian follicular hierarchies: models for the study of ovarian development. *J. Expt. Zool.*, **1990**, *4*, 112-122. <https://doi.org/10.1002/jez.1402560419>
42. Callard, I.P.; Fileti, L.; Perez, L.; Sorbera, L.; Giannoukos, G.; Klosterman, L.; Tsang, P.; McCracken, P. Role of the corpus luteum and progesterone in the evolution of vertebrate viviparity. *Am. Zool.*, **1992**, *32*, 264-275, <https://doi.org/10.1093/icb/32.2.264>
43. Rollinson, N.; Farmer, R.G.; Brooks, R.J. Widespread reproductive variation in North American turtles: temperature, egg size and optimality. *Zoology*, **2012**, *115(3)*, 160-169, DOI:10.1016/j.zool.2011.10.005
44. Perez-Bermudez, E.; Ruiz-Urquiola, A.; Lee-Gonzalez, I.; Petric, B.; Almeguer-Cuenca, N.; SanzOchotorena, A.; Espinosa-Lopez, G. Ovarian follicular development in the hawksbill turtle (*Cheloniidae: Eretmochelys imbricata* L.). *J. Morphol.*, **2012**, *273(12)*, 1338-1352, <https://doi.org/10.1002/jmor.20062>
45. Currylow, A.F.; Tift, M.S.; Meyer, J.L.; Crocker, D.E.; Williams, R.N. Seasonal variations in plasma vitellogenin and sex steroids in male and female Eastern Box Turtles, *Terrapene carolina carolina*. *Gen. Comp. Endocrinol.*, **2013**, *180*, 48-55, DOI:10.1016/j.ygcen.2012.11.005
46. Shelby, J.A.; Mendonica, M.T.; Horne, B.D.; Seigel, R.A. Seasonal variation in reproductive steroids of male and female yellow-blotched map turtles, *Graptemys flavimaculata*. *Gen. Comp. Endocrinol.*, **2000**, *119*, 43-51, DOI:10.1006/gcen.2000.7490
47. Callard, I.P.; Lance, V.; Salhanick, A.R.; Barad, D. The annual ovarian cycle of *Chrysemys picta*: Correlated changes in plasma steroids and parameters of vitellogenesis. *Gen. Comp. Endocrinol.*, **1978**, *35(3)*, 245-257, [http://dx.doi.org/10.1016/0016-6480\(78\)90069-2](http://dx.doi.org/10.1016/0016-6480(78)90069-2). PMID:689359.
48. Currylow, A.F.T.; Rafeliasoa, T.H.; Louis, E.E.; Stanford, C.B.; Randrianjafizanaka, S.T.; Chinn, S.M.; Crocker, D.E. Characterization of seasonal reproductive and stress steroid hormones in wild Radiated Tortoises, *Astrochelys radiata*. *Gen. Comp. Endocrinol.* **2017**, *253*, 70-78, DOI:10.1016/j.ygcen.2017.09.001
49. Freneau, G.E.; Sà, V.A.; Franci, C.R.; Vieira, D.; Freneau, B.N. Gonadotrophic, prolactin, corticosterone, and gonadal hormones levels over 15 months in Giant Amazon River Turtles - *Podocnemis expansa* (Schweigger, 1812) (Testudines: Podocnemididae), in captive conditions. *Braz. J. Biol.*, **2017**, *77(2)*, 347-355, <http://dx.doi.org/10.1590/1519-6984.04515>
50. Andersson, H. Clinical Reproductive Endocrinology. In *Clinical Biochemistry of Domestic Animals*, 6th ed.; Kaneko, J., Harvey, J., Bruss, M., Eds.; (ed 6). Elsevier Academic Press, Burlington, MA, USA, 2008; pp. 635-662.
51. Xia, Z.R.; Li, P.P.; Gu, H.X.; Fong, J.J.; Zhao, E.M. Evaluating Noninvasive Methods of Sex Identification in Green Sea Turtle (*Chelonia mydas*) Hatchlings. *Chelonian Conserv. Bi.*, **2011**, *10*, 117-123, DOI:10.2744/CCB-0852.1

52. Graham P. ESVE Veterinary Endocrinology External Quality Assessment Scheme ESVE REPORT. Release Number 010, **2017**. <https://www.esve.org/esve/eve-qas/ESVE-Report-010.pdf>, accessed 11/11/2020.

Chapter 2.3: Anaesthetic protocols

Acta Veterinaria Eurasia, 2021, 47(2), pp.88-92

Difference between Cranial and Caudal Intravenous Alfaxalone Administration in Yellow-Bellied Sliders (*Trachemys scripta scripta*)

Morici M.^b, Lubian E.^{a,c}, Costa G.L.^a, Spadola F.^a

^a Veterinary Teaching Hospital, Department of Veterinary Science, University of Messina, Polo Didattico Annunziata 98168 Messina, Italy,

^b Pombia Safari Park, Via Larino 3, 28050 Pombia, Italy,

^c Ospedale Veterinario Universitario Piccoli Animali, Università degli Studi di Milano, 26900, Lodi, Italy

Abstract

This study aimed to compare the hypnotic and muscle relaxant effects of alfaxalone administered IV in 2 different sites, namely cranial and caudal. A total of 20 healthy adult yellow-bellied sliders (*Trachemys scripta scripta*) were randomly assigned to 1 of the 2 groups. In the first group, the drug was administered through the cervical dorsal sinus; in the second group, the drug was administered through the coccygeal vein. A dose of 5 mg/kg of alfaxalone was used for each turtle. Induction time (IT), tracheal tube insertion time (TTiT), surgical plane of anesthesia (SPA), and full recovery time (FR) were recorded. The quality of sedation (SS) was recorded as the anesthesia score from 0 to 4. In the first group, mean IT was within $.68 \pm .37$ minutes. The mean TTiT was within $1.04 \pm .60$ minutes. The time of SPA was on average 23.82 ± 6.47 minutes, and FR occurred on average of 30.12 ± 9.52 minutes. The mean SS achieved was $4.9 \pm .32$. In the second group, mean IT was within 4.63 ± 4.44 minutes. The mean TTiT was within 6.83 ± 6.75 minutes. The time of SPA was on 22.27 ± 4.66 minutes, and FR occurred at 27.97 ± 6.76 minutes. The mean SS achieved was $3.3 \pm .82$. We believe that caudal intravenous administration of alfaxalone can be performed without risk, but an increased dose is required for anesthesia when caudal vessels are used.

Keywords: Alfaxalone, anesthesia, intravenous, renal portal system, turtles

Address for Correspondence: Emanuele LUBIAN • E-mail: emanuele.lubian@hotmail.com

Received Date: July 30, 2020 • Accepted Date: January 29, 2021 • DOI10.5152/actavet.2021.20041

Available online at actavet.org

Introduction

Alfaxalone (3 α -hydroxy-5 α -pregnane-11, 20-dione) is a synthetic neuroactive steroid that increases the binding of gamma-aminobutyric acid–A receptor to its ligand within the central nervous system, resulting in systemic muscular relaxation and hypnosis (Chiu et al., 2016; Jones, 2012). Alfaxalone is currently labeled for use only in dogs and cats in several countries but is commonly employed “off-label” in reptilian species owing to its well-known characteristics of a smooth induction time; rapid recovery time; and unlike propofol, the ability to be administered intramuscularly (IM), intracoelemically (IC), and subcutaneously (SC) (Bardi et al., 2020; Bertelsen & Sauer, 2011; Ferreira et al., 2019; Hansen & Bertelsen, 2013; Johnson, 2005; Kischinovsky et al., 2012; Lawrence & Jackson, 1983; Ratliff et al., 2019; Shepard et al., 2013; Strahl-Heldreth et al., 2019; Yaw et al., 2018). Intravenous (IV) administration in reptilian species, even if challenging, is possible and advised to decrease the induction and recovery times (Carmel, 2002; Knotek et al., 2013; Knotek, 2014; Morici et al., 2016; Olsson et al., 2013; Scheelings et al., 2010; Simpson, 2004). The recommended administration sites are jugular vein, ventral caudal vein, sub-carapacial sinus, and cervical dorsal sinus (Knotek et al., 2013; Knotek, 2014; Scheelings, 2013). The effects of caudal administration of alfaxalone were never investigated.

Similar to other reptiles, chelonians own a renal portal system (RPS), a ring of vessels surrounding the kidney, comprising the cranial and the caudal portal veins. Blood flows from the caudal area through coccygeal and iliac veins, and it breaks into the afferent renal portal vein, which transfers blood to the kidneys (Murray, 2006; O’Malley, 2005). Blood tubular perfusion leaves the kidney via the efferent portal vein, which joins the post-cava vein. The RPS is necessary to perfuse the kidney during dehydration, ensuring an adequate blood supply into renal tubules when the glomerular flow is reduced, and consequently it avoids ischemic damage (Holz et al., 1997b; Holz & Raidal, 2006). Depending on the hydration status, blood from the caudal portion can directly flow to the kidneys or may bypass it and flow straight into the systemic circulation. This apparatus is ruled by a system of valves located between the abdominal vein and the femoral vein. The RPS makes drug administration challenging in numerous reptile species. The common advice is to administer drugs into the cranial quarter of the body to avoid an accelerated excretion by RPS, increase clearance, lower plasma levels of the drug, and efficacy. Several studies have shown that clinical relevance of this concern is minimal and that probably RPS may have a greater influence in dehydrated animals only (Giorgi et al., 2015; Holz & Raidal, 2006). However, a study into the subcutaneous or IM administration in forelimbs or hind limbs of the same dosage of dexmedetomidine and ketamine mixture showed a strong difference in the sedative effect (Lahner et al., 2011). Because clinical evidence is missing, drug administration is recommended into the cranial quarter (Sladky & Mans, 2012).

Considering the benefits of alfaxalone, its use in reptile practice, and the lack of information regarding the influence of RPS with caudal administration; this study aimed to investigate and compare the hypnotic and muscle relaxant effects of alfaxalone IV administered in 2 different sites, namely cranial and caudal. Our hypotheses were that cranial IV administration of alfaxalone would provide a better sedation score, short

induction time, and longer surgical state of anesthesia than caudal IV administration, and therefore that RPS may negatively influence alfaxalone anesthesia.

Method

A total of 20 healthy adult yellow-bellied sliders (*Trachemys scripta scripta*) were used for this study. These turtles underwent sedation for clinical reasons or to perform diagnostic tests, such as to safely collect pharyngeal swabs. The turtles were private-owned animals, and the owners signed an informed consent. Upon physical examination and after biochemical tests performed (Abaxis VetScan Classic Analyzer; Abaxis, CA, USA), unhealthy animals were excluded from the data collection. The turtles were acclimatized for 3 days before the sedative procedures and were housed individually in aquatic tanks, with air temperatures maintained at approximately 26°C, water temperatures between 25°C and 28°C, and basking areas with a multipurpose mercury vapor lamp providing heat, ultraviolet A (UVA) and UVB light (Exoterra Solar Glo, Hagen Inc., Canada). During the sedation procedure, the room temperature was approximately 26°C.

The turtles were randomly assigned to 1 of the 2 groups; cranial administration group (CR) and caudal administration group (CA). In the CR group, the drug was administered through the cervical dorsal sinus.

In the CA group, the drug was administered through the coccygeal vein. For both the procedures, the animals were manually restrained when an operator (MM) injected alfaxalone intravenously using a 1 mL syringe with 26G needle (PIC, Italy). For the cervical sinus administration, the neck of the animal was gently extended, and the needle was inserted at a 90° angle in the dorsal midline; the cervical dorsal sinus was easily located in the neck soon after the needle touched a vertebra.

For coccygeal vein administration, the tail was gently extended, and the needle was inserted at a 45° angle into the dorsal midline. Once the needle touched a coccygeal vertebra, negative pressure was created with the syringe, and at the same time, the needle was gradually pulled back until the vein was reached.

A dose of 5 mg/kg of alfaxalone (Alfaxan, Vetoquinol, France) was used for each turtle, the dose was chosen according to previous studies (Knotek, 2014). The alfaxalone used was in a concentration of 10 mg mL⁻¹ with a 2-hydroxypropyl-beta-cyclodextrin excipient.

After the drug administration, the animals were placed in a fauna box (Faunarium, Exoterra, Hagen Inc., Canada), positioned on a heating pad (Pet Mat, Australia) set up at 30°C, and maintained on it until the end of the procedure.

The measurements and data recording were performed by 2 researchers (GLC, FS) blinded to the administration route.

Slow movements, pinching reflex lost (PRL), mandibular tone lost (MTL), mandibular tone recovery, pinching reflex recovery (PRR), and full movements recovery (FM) were recorded. The time from the drug administration to PRL was recorded as induction time (IT). The time from the drug administration to MTL was recorded as tracheal tube insertion time (TTiT). The time from IT until the PRR was recorded as the surgical plane of

anesthesia (SPA). The time from IT until the FM was recorded as full recovery time. Pinching reflexes were evaluated using a hemostatic forceps and applying a gentle pressure on the limb extremities.

Under manual restraint, heart rate (HR) values were obtained using a 3 MHz vascular Doppler (PD1v Pocket Vascular Doppler, Ultrasound Technologies, UK). Respiratory frequency (RR) values were obtained counting chest excursions.

Heart rate and RR were assessed at T(2), T(4), T(6), T(8), T(10), T(12), T(14), T(16), T(18), T(20), T(25) T(30), T(35), T(40), T(60), although full recovery occurred in shorter or longer time. Quality of sedation (SS) was recorded as the anesthesia score from 0 to 4 (0-fully active animal; 1-righting reflex being delayed; 2-toe pinch reflex being delayed but palpebral reflex still present; 3-disappearance of the palpebral reflex and biting reflex being delayed; 4-disappearance of the biting reflex, tracheal tube insertion possible) as described by Schnellbacher et al. (2012).

Statistical Analysis

The descriptive data were analyzed with Student's t test and analysis of variance followed by Bonferroni test using Graphpad Prism 4.03 (GraphPad Software Inc., San Diego, CA, USA). A value of $p < .05$ was considered to be significant.

Results

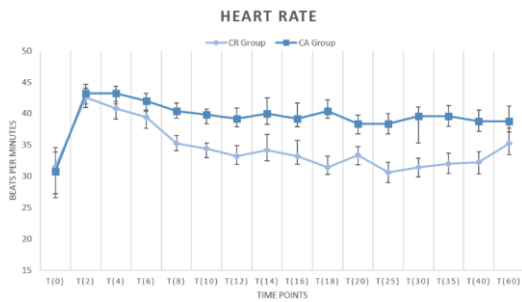
The results of this study are reported in Table 1. All recorded HR and RR values are reported in Figures 1 and 2. The body weight of the animals in this study ranged from .62 to 1.7 kg, average 1.17 kg. Mean quantity of the injected anesthetic was $.45 \pm .17$ mL. In the CR group, the mean SS achieved was $4.9 \pm .32$. In the CA group, the mean SS achieved was $3.3 \pm .82$.

Table 1

	Cranial Administration (CR)	Caudal Administration (CA)
Basal HR	31.5 ± 9.6	30.8 ± 13.4
Basal RR	10.6 ± 4.4	16.2 ± 8.4
Slow movements	.39 ± .06	2.31 ± 2.77
Induction time	.68 ± .37	4.63 ± 4.44
Tracheal tube insertion time	1.04 ± .60	6.83 ± 6.75
Surgical plane of anaesthesia	23.82 ± 6.47	22.27 ± 4.66
Full movement recovery	30.12 ± 9.52	27.97 ± 6.76

Basal Heart Rates (Beats Per Minutes), Basal Respiratory Rates (Breaths Per Minutes), Slow Movements, Induction Time, Tracheal Tube Insertion Time, Surgical Plane of Anaesthesia and Full Movement Recovery (All Values Reported in Minutes), in Both Administration Groups

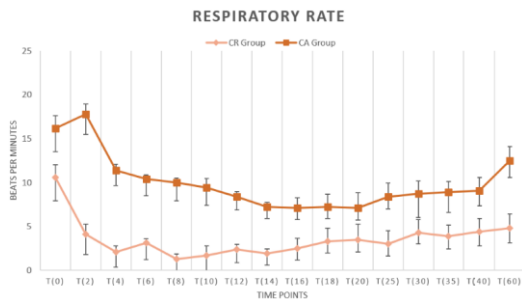
Figure 1



Mean \pm Standard Deviation of Heart Rates of Adult YellowBellied Sliders (*Trachemys Scripta Scripta*) During Anesthesia with 5 mg/kg of Alfaxalone Administered Intravenously in 2 Different Sites (in the Cranial Group, the Drug was Administered Through the Cervical Sinus; in the Caudal Group, the Drug was Administered Through the Coccygeal Vein).

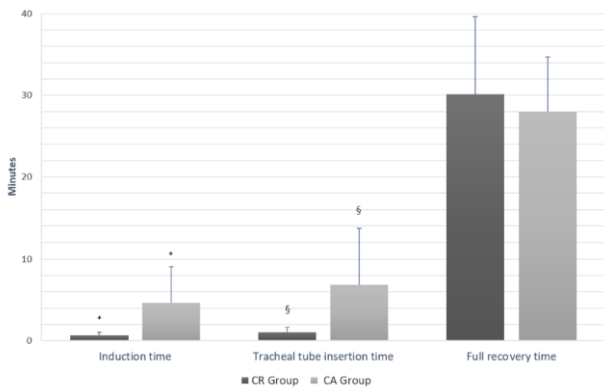
In 2 animals (2/10) of the CA group, mandibular tone was never lost during procedure. HR values were significant lower in the CR group at T(18), T(20), T(25) than those in the CA group. During cranial administration of alfaxalone in the CR group, most of the turtles achieved a semi-apnea status for several minutes; therefore, RR values were significant lower at T(2), T(4), T(6), T(8), T(10), and also at T(60). Induction time and TTiT were significant lower ($t = 2.3909$, $p = .0279$; $t = 2.3934$, $p = .0293$, respectively) in the CR group compared with the CA group values (Figure 3). No other values were statistically significant.

Figure 2



Mean \pm Standard Deviation of Respiratory Rates of Adult YellowBellied Sliders (*Trachemys Scripta Scripta*) During Anesthesia with 5 mg/kg of Alfaxalone Administered Intravenously in 2 Different Sites (in the Cranial Group, the Drug was Administered Through the Cervical Sinus; in the Caudal Group, the Drug was Administered Through the Coccygeal Vein)

Figure 3



Time (Mean ± Standard Deviation) Elapsed between Injection of Alfaxalone to Induction, Positive Tracheal Tube Insertion Attempts (Tracheal Tube Insertion Time [TTiT]), and Recovery from Anesthesia for Each Treatment Group (Cranial [CR] and Caudal [CA] Administration). Significant Differences in Induction Time are (*) and TTiT (§) between the CR and CA Groups, $p \leq .05$

Discussion, and Conclusion and Recommendations

In a previous study on IV alfaxalone anesthesia in chelonians (Knotek, 2014; Scheelings, 2013), several doses were suggested, and IT, RT, and quality of sedation obtained were different. Knotek (2014) obtained IT values of $.21 \pm .8$ minutes, whereas TTiT, SPA, and FR were $.275 \pm .12$, 26.40 ± 4.72 , and 33.70 ± 4.76 minutes, respectively, on administering a bolus dose of 5 mg/kg of alfaxalone via the subcarapacial sinus in red-ear sliders (*Trachemys scripta elegans*). The cranial administration route (cervical dorsal sinus) in our study may have slightly influenced the values recorded (IT $.68 \pm .37$ minutes, TTiT $1.04 \pm .60$ minutes, SPA 23.82 ± 6.47 minutes, and FR 30.12 ± 9.52 minutes). Different outcomes have been obtained by Scheelings (2013) in Macquarie River Turtles (*Emydura macquarii*); a mean sedation time of 14.3 minutes was recorded after jugular vein administration. In our study, we compared the cranial and caudal routes of administration to identify how RPS influenced the alfaxalone anesthesia. This analysis has already been conducted for other drugs but never for alfaxalone.

In this study, IV administration of alfaxalone at 5 mg/kg provided a prompt and reliable induction of sedation when administered in the cranial quarter as demonstrated in previous studies (Knotek, 2014), but provided a lower quality sedation ($3.3 \pm .82$ of SS) when administered in the caudal quarter. The same effect of RPS in the North American pond turtle has already been demonstrated on propofol (Di Giuseppe et al., 2018) and on antibiotics (Holz et al., 1997a). Although the anesthetic effect of alfaxalone has never been studied in chelonians, the influence of RPS on its effect in ball pythons has been demonstrated. The authors in that survey demonstrated that the same dosage injected into the cranial site led to deeper anesthesia than when injected caudally; the drug was administered intramuscularly (James et al., 2018), whereas the same effect was demonstrated in turtles after IV injection in our study.

The level of achieved sedation in the CA group was only appropriate for minor procedures; however, combination with other anesthetic drugs would allow better sedation quality (Bardi et al., 2020). IT and TTiT were significantly longer in the CA group, probably owing to the renal or hepatic extraction rate modified by

RPS activity as hypothesized in previous studies (Di Giuseppe et al., 2018; James et al., 2018). However, despite renal and hepatic influence, this effect on anesthetic power cannot be considered clinically important because the clinical sedation quality was appropriate in both groups.

We did not find any significant difference in the full recovery time between the CA and CR groups; therefore, both administration sites could be used for rapid diagnostic or surgical procedures. As mentioned earlier, sedation in chelonians is often essential to allow a complete clinical examination, especially if further diagnostic procedures (x-rays, endoscopy, or microbiological swab) are required. Alfaxalone could be a valid and rapid solution to obtain it.

Interestingly in 2 animals in the CA group, the mandibular tone was never lost, making intubation impossible; therefore, we recommend the cranial administration route or a combination with other anesthetic drugs for long-term or painful surgery. Low values of HR and RR at several time points in the CR group can be explained with the stronger activity of the drugs when administered cranially.

One of the limitations of this study was the dose administered of 5 mg/kg; probably a higher dose administered IV in caudal quarter may produce a better quality of sedation, improving our records. Higher dosages are reported for IM administration of alfaxalone in this species and for IV administration in other species (Bardi et al., 2020; Knotek et al., 2013; Johnson, 2005). Another limitation is the absence of data on blood pressure, pulse oximetry, blood gas analysis, and capnography; and we believe an in-depth study on the safety of the described protocol is needed in further studies. However, our described protocol did not result in any anesthetic deaths, thus we can admit that the protocol we used could be considered safe.

This study confirmed our hypotheses regarding the negative influence of RPS on alfaxalone anesthesia; however, we admit that negative effects do not influence the quality of sedation. The administered doses were clinically suitable for tracheal tube insertion attempts in most (18/20) of the turtles, but induction was delayed in the CA group. Therefore, one anesthetic option could be to increase the doses of alfaxalone administered in the caudal quarter or its use in conjunction with other drug classes to achieve better hypnosis. This information is particularly useful as IV caudal administration, never reported before for alfaxalone, can be used without risk when cranial vessels of the chelonian patients are unreachable for various reasons, such as aggressiveness, morphological characteristics, or lesions in the cranial quarter of the body. Further studies are also necessary to evaluate the influence of repeated bolus of alfaxalone on the parameters we have already checked and whether there is a significant difference between their CR and CA administrations.

Ethics Committee Approval: The study was performed in compliance with directive 2010/63/EU of the European Parliament and of the Council of the European Union and following an Italian law (D.M. 116192) and US laws (Animal Welfare Assurance No A5594-01, Department of Health and Human Services, USA).

Peer-review: Externally peer-reviewed.

Author Contributions: Concept – M.M.; Design – M.M., F.S.; Supervision – F.S., G.L.C.; Resources – M.M., E.L., F.S.; Materials – M.M., F.S.; Data Collection and/or Processing – M.M., G.L.C., F.S.; Analysis and/or interpretation – M.M., E.L.; Literature search – M.M., E.L.; Writing Manuscript – E.L., M.M.; Critical review – E.L., M.M., F.S., G.L.C.

Conflict of Interest: The authors have no conflicts of interest to declare.

Financial Disclosure: The authors declared that this study has received no financial support.

References

- Bardi, E., Antolini, G., Lubian, E., Bronzo, V., & Romussi, S. (2020). Comparison of Lateral and Dorsal Recumbency during Endoscope-Assisted Oophorectomy in Mature Pond Sliders (*Trachemys scripta*). *Animals*, 10(1451), 1-8.
- Bertelsen, M. F., & Sauer, C. D. (2011). Alfaxalone anaesthesia in the green iguana (*Iguana iguana*). *Veterinary Anaesthesia and Analgesia*, 38(5), 461-466.
- Carmel, B. (2002). Use of Alfaxan-CD for intravenous anaesthesia in reptiles. In *Control and Therapy*. Post Graduate Foundation in Veterinary Science, No: 4413.
- Chiu, K. W., Robson, S., Devi, J. L., Woodward, A., & Whitem, T. (2016). The cardiopulmonary effects and quality of anesthesia after induction with alfaxalone in 2-hydroxypropyl- β -cyclodextrin in dogs and cats: a systematic review. *Journal of Veterinary Pharmacology and Therapeutics*, 39(6), 525-538.
- Di Giuseppe, M., Luparello, M., Nastasi, B., & Spadola, F. (2018). Preliminary survey on influence of renal portal system during propofol anesthesia in yellow-bellied turtle (*Trachemys scripta scripta*). *Journal of Veterinary Medicine and Allied Science*, 2(1), 12-15.
- Ferreira, T. H., Mans, C., & Di Girolamo, N. (2019). Evaluation of the sedative and physiological effects of intramuscular lidocaine in bearded dragons (*Pogona vitticeps*) sedated with alfaxalone. *Veterinary Anaesthesia and Analgesia*, 46(4), 496-500.
- Giorgi, M., Salvadori, M., De Vito, V., Owen, H., Demontis, M. P., & Varoni, M. V. (2015). Pharmacokinetic/pharmacodynamic assessments of 10 mg/kg tramadol intramuscular injection in yellow-bellied slider turtles (*Trachemys scripta scripta*). *Journal of Veterinary Pharmacology and Therapeutics*, 38(5), 488-496.
- Hansen, L. L., & Bertelsen, M. F. (2013). Assessment of the effects of intramuscular administration of alfaxalone with and without medetomidine in Horsfield's tortoises (*Agrionemys horsfieldii*). *Veterinary Anaesthesia and Analgesia*, 40(6), e68-75.
- Holz, P., Barker, I. K., Burger, J. P., Crawshaw, G. J., & Conlon, P. D. (1997a). The effect of the renal portal system on pharmacokinetic parameters in the red-eared slider (*Trachemys scripta elegans*). *Journal of Zoo and Wildlife Medicine*, 28(4), 386-393.

- Holz, P., Barker, I. K., Crawshaw, G. J., & Dobson, H. (1997b). The anatomy and perfusion of the renal portal system in the red-eared slider (*Trachemys scripta elegans*). *Journal of Zoo and Wildlife Medicine*, 28(4), 378-385.
- Holz, P., & Raidal, S. (2006). Comparative Renal Anatomy of Exotic Species. *Veterinary Clinics of North America: Exotic Animal Practice*, 9(1), 1-11.
- James, L. E., Williams, C. J., Bertelsen, M. F., & Wang, T. (2018). Anaesthetic induction with alfaxalone in the ball python (*Python regius*): dose response and effect of injection site. *Veterinary Anaesthesia and Analgesia*, 45(3), 329-337.
- Johnson, R. (2005). The Use of Alfaxalone in Reptiles. *Proceedings of the Australian Veterinary Association Conference, Broadbeach, QLD, Australia*, pp. 1-4.
- Jones, K. L. (2012). Therapeutic review: alfaxalone. *Journal of Exotic Pet Medicine*, 21(4), 347-353.
- Kischinovsky, M., Duse, A., Wang, T., & Bertelsen, M. F. (2012). Intramuscular administration of alfaxalone in red-eared sliders (*Trachemys scripta elegans*)-effects of dose and body temperature. *Veterinary Anaesthesia and Analgesia*, 40(1), 13-20.
- Knotek, Z., Hrdá, A., Knotková, Z., Trnková, Š., & Babák, V. (2013). Alfaxalone anaesthesia in the green iguana (*Iguana iguana*). *Acta Veterinaria Brno*, 82, 109-114.
- Knotek, Z. (2014). Alfaxalone as an induction agent for anaesthesia in terrapins and tortoises. *Veterinary Record*, 175(13), 327.
- Lahner, L., Mans, C., & Sladky, K. K. (2011). Comparison of anesthetic induction and recovery times after intramuscular, subcutaneous or intranasal dexmedetomidine-ketamine administration in redeared slider turtles (*Trachemys scripta elegans*). *Proceedings of AAZV Conference*, 136-137.
- Lawrence, K., & Jackson, O. F. (1983). Alphaxalone/alphadolone anaesthesia in reptiles. *Veterinary Record*, 112(2), 26-28.
- Morici, M., Di Giuseppe, M., & Spadola, F. (2016). Preliminary study on intravenous alfaxalone anaesthesia in leopard geckos (*Eublepharis macularius*). *Proceedings of X Congress International on Exotic-Yaboumba World, Animauxsauvages&Exotiques*, 47-48.
- Murray, M. M. (2006). Cardiopulmonary anatomy and physiology. In D. Mader (Ed.), *Reptile Medicine and Surgery* (pp.124-128). St. Louis, MO, Saunders/Elsevier.
- Olsson, A., Phalen, D., & Dart, C. (2013). Preliminary studies of alfaxalone for intravenous immobilization of juvenile captive estuarine crocodiles (*Crocodylus porosus*) and Australian freshwater crocodiles (*Crocodylus johnstoni*) at optimal and selected sub-optimal thermal zones. *Veterinary Anaesthesia and Analgesia*, 40(5), 494-502.
- O'Malley, B. (2005). Tortoises and turtles. In B. O'Malley (Ed.), *Clinical Anatomy and Physiology of Exotic Species* (pp. 41-56). Philadelphia, PA, Elsevier/Saunders.

- Ratliff, C., Parkinson, L. A. B., & Mans, C. (2019). Effects of the fraction of inspired oxygen on alfaxalone-sedated inland bearded dragons (*Pogona vitticeps*). *American Journal of Veterinary Research*, 80(2), 129-134.
- Scheelings, T. F., Holz, P., & Haynes, L. (2010). A preliminary study of the chemical restraint of selected squamate reptiles with alfaxalone. *Proceedings of ARAV, South Padre Island*, 114-115.
- Scheelings, T. F. (2013). Use of intravenous and intramuscular alfaxalone in macquarie river turtles (*Emydura macquarii*). *Journal of Herpetological Medicine and Surgery*, 23(3-4), 91-94.
- Schnellbacher R. W., Hernandez S. M., Tuberville T. D., Mayer, J., Alhamhoom, Y., & Arnold, R. D. (2012). The efficacy of intranasal administration of dexmedetomidine and ketamine to yellow-bellied sliders (*Trachemys scripta scripta*). *Journal of Herpetological Medicine and Surgery*, 22(3-4), 91-98.
- Shepard, M. K., Divers, S., Braun, C., & Hofmeister, E. H. (2013). Pharmacodynamics of alfaxalone after single-dose intramuscular administration in red-eared sliders (*Trachemys scripta elegans*): a comparison of two different doses at two different ambient temperatures. *Veterinary Anaesthesia and Analgesia*, 40(6), 590-598.
- Simpson, M. (2004). Anaesthesia of Reptiles. *Proceedings of UEPS/AVA National Conference*, 119-126.
- Sladky, K. K., & Mans, C. (2012). Clinical anesthesia in reptiles. *Journal of Exotic Pet Medicine*, 21(1), 17-31.
- Strahl-Heldreth, D. E., Clark-Price, S. C., Keating, S. C. J., Escalante, G. C., Graham, L. F., Chinnadurai, S. K., & Schaeffer, D. J. (2019). Effect of intracoelomic administration of alfaxalone on the righting reflex and tactile stimulus response of common garter snakes (*Thamnophis sirtalis*). *American Journal of Veterinary Research*, 80(2), 144-151.
- Yaw, T. J., Mans, C., Johnson, S. M., Doss, G. A., & Sladky, K. K. (2018). Effect of injection site on alfaxalone-induced sedation in ball pythons (*Python regius*). *Journal of Small Animal Practice*, 59(12), 747-751.

ANAESTHETIC INDUCTION WITH ALFAXALONE IN JUNGLE CARPET PYTHON (*MORELIA SPILOTA CHEYNEI*)

Running title:

The use of alfaxalone as a short-acting anaesthetic agent for induction to inhalation anaesthesia in jungle carpet python; study to evaluate how it works on respiratory rate, heart rate recording deep anaesthesia and full recovery time.

Authors: Manuel Morici^{1,2*}, Filippo Spadola¹, Matteo Oliveri³, Emanuele Lubian^{1,4} Zdenek Knotek⁵

¹Veterinary Teaching Hospital, Department of Veterinary Science, University of Messina, Polo Didattico Annunziata 98168 Messina, Italy,

² Pombia Safari Park, Via Larino 3, 28050 Pombia, Italy,

³Veterinary Teaching Hospital, Faculty of Veterinary, University of Teramo, 64100 Piano D'accio, Teramo, Italy,

⁴ Ospedale Veterinario Universitario Piccoli Animali, Università degli Studi di Milano, 26900, Lodi, Italy

⁵University of Veterinary and Pharmaceutical Sciences Brno, Faculty of Veterinary Medicine, Avian and Exotic Animal Clinic, Palackeho tr. 1946/1, 61242 Brno, Czech Republic;

Corresponding author: Dr. Emanuele Lubian, DVM, PhS, GPCert(ExAP), EM. Ospedale Veterinario Universitario Piccoli Animali, Università degli Studi di Milano, Italy Email: emanuele.lubian@hotmail.com

Abstract: The aim of this investigation was to assess clinical use of alfaxalone as a short-acting anaesthetic agent for induction to inhalation anaesthesia in jungle carpet python (*Morelia spilota cheynei*). Ten captive, healthy sub-adult jungle carpet pythons (1.1 ± 0.32 kg bw) were anaesthetised using a dose of 10mg/kg of alfaxalone, administered intravenously to the ventral tail vein. Heart rate (HR) and respiratory rate (RR) were recorded before administration (T_0), and every 5 minutes until snake were full recovered from anaesthesia. The induction time, time of tail-pinch reflex loss, tracheal tube insertion time, interval of deep anaesthesia and time of full recovery were recorded. The induction time occurred within 3.1 ± 0.8 minutes. The tail-pinch reflex loss was lost within 5.6 ± 0.7 minutes. The mean tracheal tube insertion time, the interval of deep anaesthesia, and the time of full recovery were 6.9 ± 0.9 minutes, 18.8 ± 4.7 minutes, and 36.7 ± 11.4 minutes, respectively. A prolonged time of full recovery was recorded just in two snakes (61.3 and 62.6 minutes, respectively).

Mean heart rate was statistically higher ($p < 0.05$) at T₅, T₁₅ and T₂₀ when compared with basal HR at T₀. Respiratory rate in snakes dropped in T₅ and was statistically lower ($p < 0.05$) from T₅ until T₂₀ when compared with RR in all other time points. In two snakes apnoea was recorded at T₅. Intravenous administration of alfaxalone proved to be a valuable method of induction suitable for a subsequent inhalation anaesthesia in jungle carpet pythons.

Keywords: reptile; snake; anaesthesia; alfaxalone; *Morelia spilota*

INTRODUCTION

Many anaesthetic protocols have been used for induction of anaesthesia in ophidian species, generally with varying results. Most of these protocols resulted in prolonged induction and recovery time, with some of them exceeding 24 hours (Glenn, 1972; Harding, 1977; Chudzinski, 1989; Charland, 1991; Stirl, 1996; Schumacher, Copeia 1997; Bennett, 1998; Anderson, 1999; Carregaro, 2009). Intravenous administration of alfaxalone is advised in reptiles to decrease induction time of inhalation anaesthesia (Simpson, 2004; Carregaro, 2009; Knotek, 2013; Olsson, 2013; Scheelings, 2013; Knotek, 2014; Yaw, 2018; Ferreira, 2019; Ratliff, 2019; Strahl-Heldreth, 2019). This method proved feasible sedation of some chelonians and lizard species (Simpson, 2004; Scheelings, 2013; Knotek, 2017). Alfaxalone is a synthetic neuroactive steroid that increases binding of the gamma-aminobutyric acid receptor to its ligand in the central nervous system, resulting in complete muscular relaxation and hypnosis (Jones, 2012; Chiu, 2016). Intravenous administration of alfaxalone resulted in smooth induction to inhalation anaesthesia with rapid recovery time. In comparison with propofol, alfaxalone can be also administered intramuscularly, intracoelemic and subcutaneously (Lawrence, 1983; Johnson, 2005; Bertelsen, 2011; Hansen, 2013; Kischinovsky, 2013; Knotek, 2013, Chiu, 2016; Yaw, 2018; Morici, 2018; Ferreira, 2019; Ratliff, 2019; Strahl-Heldreth, 2019). This may be advantageous in small reptiles where intravenous access is challenging. Moreover, even if administered perivascular, alfaxalone will not cause any tissue reaction unlike propofol (Yaw, 2018; Ferreira, 2019; Ratliff, 2019; Strahl-Heldreth, 2019). Results of alfaxalone anaesthesia in snakes was reported by Scheelings et al. (Shepard, 2013) but a single species studies were never performed except in common garter snakes (*Thamnophis sirtalis*) (Strahl-Heldreth, 2019). Our hypothesis was that alfaxalone can provide a short induction and recovery time, and moreover it can allow a safe endotracheal intubation even in common kept snake species. The aim of the present study was to evaluate clinical use of intravenous alfaxalone as a short-acting anaesthetic agent for induction to inhalation anaesthesia in jungle carpet python (*Morelia spilota cheynei*).

MATERIAL AND METHODS

Animals

Ten (two males and eight females) healthy sub-adult jungle carpet pythons (*Morelia spilota cheynei*) were involved in this study. The body weight of snakes was 1.1 ± 0.32 kg with the range 0.72 – 1.55 kg. All snakes came from the same captive private breeder and were housed in the same environmental condition. The owner signed an informed consent, all the snakes were sedated to collect diagnostic swabs. One week before anaesthesia all snakes were housed individually in glass terrariums (Exoterra Natural Terrarium Medium/Tall, Exoterra, Hagen Inc., Canada). The air temperature was maintained at 28°C (with maximum of 32°C on the basking spot areas) with a multipurpose mercury vapour lamp (Exoterra Solar Glo, Hagen Inc., Canada). Snakes were kept under 10 hours on light and 14 hours on dark as daily regime. Air humidity within terrariums was maintained at 70% with the use of manual vaporization once a day. The snakes were kept fasted for 10 days before the anaesthesia, but clean water was offered *ad libitum*. After physical examination blood was collected from the ventral tail vein (Redrobe, 1999) for blood profile analyses. Packed cell volume (PCV) was measured using microhematocrit capillary tubes, total red blood cell and white blood cells counts were performed manually, using a hemocytometer with Natt and Herrick's solution. Blood smears were prepared using a coverslip technique and differential leukocyte counts were assessed by enumeration of 200 cells in each smear. Blood chemistry was performed with the use of Abaxis VetScan Classic Analyzer; Abaxis, CA, USA. Clinically healthy snakes with the blood profile within the normal range for pythons (Centini, 2002) were included in the investigation. All of ten python were considered healthy and were enrolled in the investigation.

Anaesthesia and monitoring

The air temperature within the room where the anaesthesia was performed was set at 26°C.

The snakes were manually restrained and the basal heart rate (HR, in T_0) was recorded using a vascular Doppler probe (PD1v Pocket Vascular Doppler, Ultrasound Technologies, UK). The basal respiratory rate (RR, in T_0) was assessed by checking the snake body wall expansions at rest. Alfaxalone (Alfaxan, 10 mg/mL, Vetoquinol, France) was administered intravenously into the ventral tail vein in a dose of 10 mg/Kg (0.93 ± 0.37 mL) with 1 or 2.5 mL syringes with 26G needle (PIC, Italy). Alfaxalone was administered in a single bolus over a period of few seconds; the time was calculated starting from the end of alfaxalone administration.

Snakes were placed into a plastic box (Faunarium, Exoterra, Hagen Inc., Canada) placed on a heating pad (Pet Mat, Australia) set up at 30 °C. HR, RR and reflexes (righting reflex, tail-pinch reflex, tracheal tube insertion) were assessed in five minute intervals ($T_5, T_{10}, T_{15}, T_{20}, T_{25}, T_{30}, T_{35}, T_{40}, T_{45}, T_{50}, T_{55}, T_{60}$) until full recovery of snakes occurred. Reflexes were evaluated by the same operator (MM). Righting reflex was checked with the snake being gently positioned in dorsal

recumbency. Tail-pinch reflex was evaluated applying a gentle pressure on tail extremity with haemostatic forceps. The retraction to the pressure would have been stated as a positive response to tail-pinch reflex. For tracheal tube insertion the relaxation of mandibular tone was assessed. The snake's mouth was gently opened manually by the surgeon (MM) and intravenous plastic catheter without needle (14, 16 or 18 gauge depending on the snake size, Artsana, Italy) was used as endotracheal tube inserted into trachea (Leanne C, 2011). The length of endotracheal tube was based on snake dimension, considering the extremely long snake's trachea if compared with other species and the presence of a vestigial lung, intubation is a secure procedure (Mans C, 2019). Once the tracheal tube was inserted, snakes were ventilated with environmental air (flow rate of 0.2–0.4 l/min) to avoid negative influence on normal breathing and on full recovery time due to O₂ ventilation (Mans C, 2019). Tracheal tube was connected to a non-rebreathing circuit. Positive pressure ventilation (4-6 breaths/minute) was manually performed in those snakes that had spontaneous respiratory rates lower than 1 breath per minute, to guarantee the desired volume (Leanne C, 2011; Bennet RA, 1998).

The time of alfaxalone administration to the loss of the righting reflex was recorded as the induction time. The time from alfaxalone administration to the loss of the tail-pinch-reflex was recorded as the time of tail-pinch reflex loss. The time from alfaxalone administration to the loss of mandibular tone and tracheal tube insertion was recorded as tracheal tube insertion time. The time interval from the loss of the tail-pinch reflex to its restoration was recorded as the interval of deep anaesthesia. The time interval from the loss of the righting reflex to its restoration was recorded as the time of full recovery. Descriptive statistical analyses of measured indicators - minimum, maximum, mean and standard deviation (SD) were performed by statistical software GraphPad Prism 4.03 (GraphPad Software, Inc., USA), with assessment of distribution of the data (Shapiro-Wilk test) and ANOVA followed by Bonferroni test. Differences in HR and RR values in T₀ and T₅, T₁₀, T₁₅, T₂₀, T₂₅, T₃₀, T₃₅, T₄₀, T₄₅, T₅₀, T₅₅, were compared and differences were considered to be significant if $p < 0.05$.

RESULTS

The values of HR and RR before (T₀) and after the alfaxalone administration are illustrated in Figure 1. The mean basal heart rate in T₀ was 51.4±3.41 beats per minutes. The mean basal respiratory rate at T₀ was 5±1.25 breaths per minutes. Mean heart rate was significantly higher ($p < 0.05$) at T₅, T₁₅ and T₂₀ when compared with basal HR at T₀. Respiratory rate in snakes dropped at T₅ and was significantly lower ($p < 0.05$) from T₅ until T₂₀ when compared with all other time points. In two snakes apnea was recorded at T₅, and spontaneous breathing started again after one to two minutes of assisted ventilation. Anaesthetic results are summarized in table 1. A prolonged time of full recovery (mean recovery 36.7 minutes) was recorded just in two snakes (61.3 and 62.6 minutes, respectively).

DISCUSSION

While alfaxalone has been advised for rapid induction of anaesthesia in chameleons, iguanid lizards, agamid lizards (Knotek, 2013, 2017) and chelonian species (Scheelings et al., 2011; Knotek, 2014) observed different results in five snake species (red-bellied black snake *Pseudechis porphyriacus*, lowland copperhead *Austrelaps superbus*, tiger snake *Notechis scutatus*, black-headed python *Aspidites melanocephalus* and eastern carpet python *Morelia spilota mcdowelli*). A probable explanation of observed differences in alfaxalone action is that the species preferred optimal body temperature (and thus metabolism) may greatly influence alfaxalone action. Moreover, above said differences could be explained by different accuracy of intravenous administration in some snakes and lizards. In fact, intravenous administration of drug in big snakes (pythons and boid snakes) is rather difficult and more challenging method than the similar method in small snakes or lizards. Nevertheless, the ventral tail vein is the standard site for intravenous administration of anaesthetics in snakes and this method was therefore used in the present study. Intra-cardiac administration is associated with the risk of cardiac tamponade, myocardium inflammation and degeneration (McFadden, 2011) and drug administration in the palatal veins (*venae palatinae*) could cause haematoma (Stahl, 2006).

Unlike some previous studies reporting a suggested dose of 5mg/kg IV in reptiles (Knotek, 2014, 2017), we used a dose of alfaxalone of 10 mg/kg. This decision was taken after numerous difficult inductions by using 5mg/kg IV in snakes referred to our clinic (MM, FS) and considering the more recent scientific literature concerning this topic (Yaw, 2018; Ferreira, 2019; Ratliff, 2019; Strahl-Heldreth, 2019). In comparison with our previous results with alfaxalone in lizards (Knotek, 2017), the induction time, the time of tail-pinch reflex loss, the tracheal tube insertion time, the interval of deep anaesthesia and the time of full recovery were longer in the present study with jungle carpet pythons, even with the higher dose being used (10 mg/kg vs 5 mg/kg). It might be caused by specific anatomical and physiological differences in renal portal system in lizards and snakes. Moreover, the slow blood pressure and slow metabolic rate of ophids (if compared with lizards) may have affect tremendously the IV administration of alfaxalone. Anyway, is reported a difference in alfaxalone induction between cranial and caudal subcutaneous injections in ball phyton (Yaw, 2018); our decision to use the ventral tail vein could evidence different anaesthetic times than another cranial venous access.

Alfaxalone administered intravenously to ten sub-adult jungle carpet pythons (*Morelia spilota cheynei*) at a dose of 10 mg/kg acted rapidly. Anaesthesia was achieved in all snakes, and tracheal tube insertion was performed without difficulty. Skeletal muscle relaxation, loss of the righting reflex, tail-pinch-reflex and mandibular tone were observed in all pythons in this study. Within the time interval from the 5th to the 20th minute after alfaxalone administration, heart rate increased significantly while the respiratory rate decreased. Heart rate increasing associated with a decreased respiratory rate is a common report using alfaxalone. In two snakes apnea was present at the 5th minute after the alfaxalone administration.

This is in accordance with previous experience of one author (ZK) with alfaxalone administration to lizards at a dose of 10 mg/kg. The mean intubation time and the time of full recovery for jungle carpet pythons (*Morelia spilota cheynei*) in the present study were similar to the intubation time for eastern carpet pythons (*Morelia spilota macdowelli*), and full recovery time for black-headed python (*Aspidites melanocephalus*), using the same methodology, as reported recently by Scheelings et al. (2011).

Intravenous use of alfaxalone proved to be a suitable method of induction and subsequent tracheal tube insertion in jungle carpet pythons. Mean heart rate increased significantly while respiratory rate decreased significantly from T₅, until T₂₀ and apnoea was recorded in two snakes at T₅ after alfaxalone administration. More studies are needed in order to find an optimal dose of alfaxalone for the different species of snakes.

REFERENCES

1. ALWORTH, L.C., HERNANDEZ, S.M., DIVERS, S.J. (2011). Laboratory Reptile Surgery: Principles and Techniques. JAALAS, Vol 50(1): 11–26
2. ANDERSON, N.L., WACK, R.F., CALLOWAY, L., HETHERINGTON, T.E., WILLIAMS, J.B. (1999). Cardiopulmonary effects and efficacy of propofol as an anesthetic agent in brown tree snakes, *Boiga irregularis*. Bull Assoc Reptile Amphib Vet; 9: 9-15
3. BENNETT, R.A. (1998). Reptile anesthesia. Semin Avian Exot Pet Med. 7: 30-40
4. BERTELSEN, M.F., SAUER, C.D. (2011). Alfaxalone anaesthesia in the green iguana (*Iguana iguana*). Vet Anaesth Analg; 38(5): 461-466
5. CARREGARO, A.B., CRUZ, M.L., CHERUBINI, A.L., LOUREIRO LUNA, S.P.(2009). Influence of body temperature on rattlesnakes (*Crotalus durissus*) anesthetized with ketamine. Pesq. Vet. Bras.; 29(12): 969-973
6. CENTINI, R., KLAPHAKE, E. (2002). Hematologic values and cytology in a population of captive jungle carpet pythons, *Morelia spilota cheynei*. In: ARAV Conference, Reno, NV. 107–111
7. CHARLAND, M.B. (1991). Anesthesia and transmitter implantation effects of gravid garter snakes (*Thamnophis sirtalis* and *T. elegans*). Herpetol Rev; 22: 46-47
8. CHIU, K.W., ROBSON, S., DEVI, J.L., WOODWARD, A., WHITTEM, T. (2016). The cardiopulmonary effects and quality of anesthesia after induction with alfaxalone in 2-hydroxypropyl- β -cyclodextrin in dogs and cats: a systematic review. J Vet Pharmacol Ther; 39(6): 525-538
9. CHUDZINSKI, A.M., SEELAENDER, M.C., KELEN, E.M.A. (1989). Standardization of anesthesia with pentobarbital in the snake *Bothrops jararaca*. Mem. Inst. Butantan; 51: 147-152

10. FERREIRA, T.H., MANS, C., DI GIROLAMO, N. (2019). Evaluation of the sedative and physiological effects of intramuscular lidocaine in bearded dragons (*Pogona vitticeps*) sedated with alfaxalone. *Vet Anaesth Analg.* 46(4): 496-500
11. GLENN, J.L., STRAIGHT, R., SNYDER, C.C. (1972). Clinical use of ketamine hydrochloride as an anesthetic agent for snakes. *Am. J. Vet. Res.*; 33: 1901-1903
12. HANSEN, L.L., BERTELSEN, M.F. (2013). Assessment of the effects of intramuscular administration of alfaxalone with and without medetomidine in Horsfield's tortoises (*Agrionemys horsfieldii*). *Vet Anaesth Analg*; 40(6): e68-75
13. HARDING, K.A. (1977). The use of ketamine anaesthesia to milk two tropical rattlesnakes (*Crotalus durissus terrificus*). *Vet Rec*; 100(14): 289-90.
14. JOHNSON, R. (2005). The Use of Alfaxalone in Reptiles. In: Australian Veterinary Association Conference, Broadbeach, QLD, Australia. 1-4
15. JONES, K.L. (2012). Therapeutic Review: Alfaxalone. *J Exot Pet Med*; 21(4): 347-353.
16. KISCHINOVSKY, M., DUSE, A., WANG, T., BERTELSEN, M.F. (2013). Intramuscular administration of alfaxalone in red-eared sliders (*Trachemys scripta elegans*)-effects of dose and body temperature. *Vet Anaesth Analg*; 40(1): 13-20
17. KNOTEK, Z. (2014) Alfaxalone as an induction agent for anaesthesia in terrapins and tortoises. *Vet Rec.*; 175(13): 327
18. KNOTEK, Z. (2017). Induction to inhalation anaesthesia in agamid lizards with alfaxalone. *Veterinary Medicine (Prague)*; 62(1): 41-43
19. KNOTEK, Z., HRDÁ, A., KNOTKOVÁ, Z., TRNKOVÁ, S., BABÁK, V. (2013). Alfaxalone anaesthesia in the green iguana (*Iguana iguana*). *Acta Vet Brno*; 82(1): 109-114
20. LAWRENCE, K., JACKSON, O.F. (1983). Alphaxalone/alphadolone anaesthesia in reptiles. *Vet Rec*, 112(2): 26-8
21. MANS, C., SLADKY, K.K., SCHUMACHER, J. (2019). General Anesthesia. In *Mader's Reptiles and amphibians medicine and surgery*. Third Edition. Elsevier. 447-474
22. MCFADDEN, M.S., BENNETT, R.A., REAVILL, D.R., RAGETLY, G.R., CLARK-PRICE, S.C. (2011). Clinical and histologic effects of intracardiac administration of propofol for induction of anesthesia in ball pythons (*Python regius*). *J Am Vet Med Assoc*; 239(6): 803-7

23. MORICI, M., DI GIUSEPPE, M., SPADOLA, F., OLIVERI, M., KNOTKOVÁ, Z., KNOTEK, Z. (2018). Intravenous alfaxalone anaesthesia in leopard geckos (*Eublepharis macularius*). *J Exot Ped Med* 27:11-14
24. OLSSON, A., PHALEN, D., DART, C. (2013). Preliminary studies of alfaxalone for intravenous immobilization of juvenile captive estuarine crocodiles (*Crocodylus porosus*) and Australian freshwater crocodiles (*Crocodylus johnstoni*) at optimal and selected sub-optimal thermal zones. *Vet Anaesth Analg*; 40(5): 494-502
25. RATLIFF, C., PARKINSON, L.A.B., MANS, C. (2019). Effects of the fraction of inspired oxygen on alfaxalone-sedated inland bearded dragons (*Pogona vitticeps*). *Am J Vet Res.* 80(2):129-134
26. REDROBE, S., MACDONALD, J. (1999). Sample collection and clinical pathology of reptiles. *Vet Clin North Amer - EAP*; 2: 709-730
27. SCHEELINGS, T.F. (2013). Use of Intravenous and Intramuscular Alfaxalone in Macquarie River Turtles (*Emydura macquarii*). *J Herpetol Med Surg*; 23(3-4): 91-94
28. SCHEELINGS, T.F., BAKER, R.T., HAMMERSLEY, G., HOLLIS, K., HOLZ, P. (2011). A preliminary investigation into the chemical restraint with alfaxalone of selected Australian Squamate species. *J Herpetol Med Surg*; 21(2-3): 63-67
29. SCHUMACHER, J., LILLYWHITE, H.B., NORMAN, W.M., JACOBSON, E.R. (1997). Effects of ketamine HCl in cardiopulmonary function in snakes. *Copeia*; 2: 395-400
30. SHEPARD, M.K., DIVERS, S., BRAUN, C., HOFMEISTER, E.H. (2013). Pharmacodynamics of alfaxalone after single-dose intramuscular administration in red-eared sliders (*Trachemys scripta elegans*): a comparison of two different doses at two different ambient temperatures. *Vet Anaesth Analg*; 40(6): 590-8
31. SIMPSON, M. (2004). Anaesthesia of Reptiles. In: UEPS/AVA National Conference. Sydney, Australia. 119-126
32. STAHL, S. (2006). Reptile haematology and serum chemistry. In: North American Veterinary Conference, Orlando, FL. 1672-1676
33. STIRL, R., KRUG, P., BONATH, K.H. (1996). Tiletamine/zolazepam sedation in *Boa constrictor* and its influence on respiration, circulation and metabolism. In: EAZWV Congress. Rostock, Germany. 16-18
34. STRAHL-HELDRETH, D.E., CLARK-PRICE, S.C., KEATING, S.C.J., ESCALANTE, G.C., GRAHAM, L.F., CHINNADURAI, S.K., SCHAEFFER, D.J. (2019). Effect of intracoelomic administration of alfaxalone on the righting reflex and tactile stimulus response of common garter snakes (*Thamnophis sirtalis*). *Am J Vet Res.* 80(2):144-151
35. YAW, T.J., MANS, C., JOHNSON, S.M., DOSS, G.A., SLADKY, K.K. (2018). Effect of injection site on

Table 1: Induction to anaesthesia with alfaxalone (10 mg/kg) administered intravenously to 10 sub adult jungle carpet python (*Morelia spilota cheynei*).

Value	Induction time (minutes)	Time of tail-pinch reflex loss (minutes)	Tracheal tube insertion time (minutes)	Interval of deep anaesthesia (minutes)	Time of full recovery (minutes)
Minimum	1.5	4.4	5.4	14.1	28.2
Maximum	4.5	6.6	8.8	26.7	62.6
Mean	3.1	5.6	6.9	18.8	36.7
SD	0.8	0.7	0.9	4.7	11.4

Figure 1: Mean (\pm SD) heart rate and respiratory rate in 10 sub adult jungle carpet pythons (*Morelia spilota cheynei*) during intravenous anaesthesia with alfaxalone (10 mg/kg).

Comparison between cloacocystoscopic and coeloscopic gender identification using two anaesthetic protocols in burmese star tortoise (*Geochelone platynota*)

LUBIAN E.^{1,3,4}; DUSE F.^{2,3}; BARDI E.² & SPADOLA F.¹

¹ Department of Veterinary Science, University of Messina, Polo Didattico Annunziata 98168 Messina, Italy

² MypetClinic, Viale Ranzoni 10, 20149, Milano, Italy

³ Ospedale Veterinario Universitario Piccoli Animali, Università degli Studi di Milano

Cloacoscopy, coelioscopy and cystoscopy are the three demonstrated endoscopic methods to identify gender in chelonians. Few studies have been published regarding all these three methods but there aren't comparative studies and till now there is not the possibility to recognize which one is better. Coelioscopy allow the direct visualization of the gonads but the animals need to be anesthetized, contrary cloacoscopy and cystoscopy can be performed without sedation but gonads visualization is transvescical or trancloacal. In this study we performed cloaco-cystoscopy and coelioscopy in 12 specimens of Burmese star tortoise between 61g to 151g, using two different anaesthetic protocols. Cloacoscopy has been performed without sedation, in dorsal recumbency, to identify the health status of the animals before to perform coelioscopy. Coelioscopy has been performed using two different anaesthetic protocols (Alfaxalone 5 mg/kg and local lidocaine 2 mg/kg – Alfaxalone 5 mg/kg, dexmedetomidine 10 mg/kg, local lidocaine 2 mg/kg antagonized with atipamezole 50 mg/kg). Results show that gender identification in the animals we studied was extremely hard using cloacocystoscopic method (due to presence of cloacal calculus, opacity of bladder wall and the difficult to identify the genital papillae) compared with coelioscopic method (in which gonads have been identify in less than 10 minutes in all animals). Between two anaesthetic protocols the one with dexmedetomidine provide a good muscular relaxation, a good sedation and a rapid and smooth awake, optimal to perform the coelioscopic investigation.

Comparison between cloaco-cystoscopic analysis performed with and without intrathecal anaesthesia

LUBIAN E.^{1,3,4}; DUSE F.^{2,3}; BARDI E.² & SPADOLA F.¹

¹ Department of Veterinary Science, University of Messina, Polo Didattico Annunziata 98168 Messina, Italy

² MypetClinic, Viale Ranzoni 10, 20149, Milano, Italy

³ Ospedale Veterinario Universitario Piccoli Animali, Università degli Studi di Milano

Cloacoscopy and cloacoscopy are performed in chelonians for routinary diagnostic procedures. They could be performed without anaesthesia, under sedation or under complete anaesthesia. In last ten years a new anaesthetic technique is performed in surgical procedures of the caudal portion of the chelonian body; the intrathecal anaesthesia using lidocaine has been demonstrated to be useful for procedures of tail, cloaca, urinary bladder, genitalia and hindlimbs, allowing minor surgeries in the caudal body, such as phallectomy. In this retrospective study we compare the cloacocystoscopic procedure with and without intrathecal anaesthesia. 36 animals were included into this preliminary survey, 23 without anaesthesia and 13 subjected to intrathecal anaesthesia between 247g and 1815 g, both males and females. Intrathecal anaesthesia was performed using 2 mg/kg of lidocaine as already reported in previews studies. Our results demonstrated that intrathecal anaesthesia guarantee to reduce time of entire procedure, to reduce stress on the animal and to be able to visualize better the coelomic organs and cloacal lumen because there aren't contractions that empty the urinary bladder and because there isn't faecal material inside cloaca. This study is pioneering for future cloacal and cystic investigation, because demonstrated that using intrathecal anaesthesia is possible to reduce animal stress and to increase the performance of the entire procedure.

Chapter 3 - Discussion

Endoscopy in exotic species is one of the most important diagnostic procedure, its powerful is yet to be completely known and its use is continually increasing in all exotic pets; especially in birds and reptiles. Between these two classes, birds have been intensively studied and it has been demonstrated that they are perfect endoscopic patients. Reptiles, instead, are not as known as birds for endoscopic procedures, but the importance that endoscopy have in birds could be as well in reptiles. Indeed, most species of these two classes are small, especially if compared with other domestic pets, and the most important characteristic of endoscopy is to magnify the image to allow to see also very small structures. Minimally invasive procedures are the way to perform surgery in these species.^{1,2,3,4,5}

Endoscopy, compared with other diagnostic techniques, allows the direct visualization of the organs. Other diagnostic imaging procedures (x rays, ultrasound, CT scan...), often, aren't able to provide enough information for a precise diagnose, especially in for coelomic organ. As already demonstrated, endoscopy provides an optimal visualization of the coelomic cavity, that could be direct or indirect (transvescical); in some animals this method could be the only pre mortem that allows the visualisation of the lesions and that permit to have an antemortem diagnosis. Furthermore, endoscopy allows to take biological samples (biopsies, microbiology...)^{6,7,8,9,10,11,12}

The PhD candidate tried to standardize, especially, the cloacoscopic investigation of the internal organs, with the goal to recognize the powerful and the limits of this procedure. One survey before this thesis demonstrated which are coelomic organs visible with cystoscopy.¹³ This survey didn't consider the possible differences between various chelonians orders and didn't consider the transcloacal visualization of the internal organs, for example trough the accessory bladders. As explained before, in this thesis it has been demonstrated which are the organs and which are the possibilities to visualize them with cloacoscopy and with cystoscopy, considering, especially, the difference between genders and dimensions of the animals; furthermore, the work has been done separately considering the taxonomic difference of the animals; for example: in *Testudo* sp. (we analyzed *Tesdudo hermanni boettgeri*) there aren't urinary bladders, which are present, instead, in Emydidae and Geoemydidae. This study tried to recognize the ability of this diagnostic approach in the different pet species (e.g. the most commons *Trachemys* sp. and *Testudo* sp.) and in wild species (*Emys orbicularis* and *Testudo* sp.). The surveys explained that endoscopy is a good diagnostic tool to analyze the coelomic cavity trough cloacoscopy and cystoscopy, to explore liver, gonads, and some gastrointestinal areas. Furthermore, these surveys are the first that demonstrated that is possible to enter in the oviducts in order to explore the lumen (useful for example during dystocia) and the internal walls. The presence of an egg could be evidenced also with x-rays but this method doesn't allow to recognize if the egg is in the oviducts, in the cloaca or inside the urinary bladder; using endoscopy it is possible, and easy, recognize that. Further studies are necessary to obtain more data and to recognize better the ability of this diagnostic procedure, to make it routinary during normal clinical examination of chelonians.

Moreover, we demonstrated in this thesis that cloacoscopy is a good method to recognize gender in lizards, also in hatchlings. In these species hatchlings can have a cloacal anatomy very similar to adults; in author experience this happens in some species, not just in *Tiliqua* sp. as demonstrated in our PhD studies, but, for example, also in *Tegu* sp.¹⁴ To understand better the powerful of endoscopy in gender identification in lizards, further studies are necessary. It's important

to standardize the method in other species or genus to identify if what we found in *Tiliqua* sp. and *Tegu* sp. could be extended to other lizards.

To identify gender in chelonians, coelioscopy remains the gold standard method, since with cystoscopy you could have several conditions: pathologic condition (e.g. cloacal or urinary bladder calculus) can make impossible the gonadal visualization; opacity of urinary bladder in some chelonian species; lack of accessory urinary bladders in Testudinidae; difficulty to visualize the genital papillae in some animals.

Furthermore, there are new sexing methods that have been studied in last years that can revolutionize the gender identification in chelonians, these are based on molecular diagnosis, using, particularly, the PCR. Hormonal evaluation from chorioallantoic/amniotic fluid, as already said, has been performed comparing testosterone and oestradiol concentration; especially the ratio E/T is significantly lower in males than in females.^{15,16} This method has been studied in loggerhead turtles, in green turtles and in North American pond turtle and in common snapping turtle, but necessities to be verified in other chelonian species, so further studies are necessary to demonstrate its operation. The other critic point of this method is the necessity to incubate the eggs or to quickly find the juveniles. Moreover, hormonal evaluation on hatchlings has been done with research of Anti-Mullerian Hormone (AMH) that can be reliably detected in blood samples from neonate male turtles but not females and can be used as a sex-specific marker. In the study performed in 2020, verification of sex via histology or laparoscopy revealed that this method was 100% reliable for identifying sex in both *T. scripta* and *C. caretta* 1–2 day-old hatchlings and 90% reliable for identifying sex in 83–177 day-old (120–160g) loggerhead juveniles.¹⁷ The data published in this study can be the right solution to a perfect sexing method in chelonians, but the authors consider this method as non-invasive method, even if it isn't a right consideration. In candidate's opinion, PCR methods will be in the future the best solution to identify the gender in reptiles, especially in chelonians, but, currently, there aren't enough knowledges and studies about them.

Considering anaesthesia, the candidate studied the new drugs and the recent anaesthetic protocols. Firstly, he published data, already collected in the department, regarding the powerful of alfaxalone injected in the cranial or caudal part of the body in North American pond turtle. In this article has been demonstrated that renal portal system has an important rule on drug circulation and drug efficacy.

As said before, coeloscopic investigation should be performed with deep sedation, or, better with proper anaesthesia. Several anaesthetic protocols have been reported, none of them with a proper survey and with a good comparison of different protocols. Moreover, chelonian species are very different and, in author opinion, the responses to anaesthetic and analgesic protocols varies between different species. During the PhD program the candidate have tried to evaluate the best anaesthetic protocols in the available species; especially two of them (alfaxalone 5 mg/kg and local lidocaine 2 mg/kg – alfaxalone 5 mg/kg, dexmedetomidine 10 mg/kg, local lidocaine 2 mg/kg antagonized with atipamezole 50 mg/kg) have been studied better in some exotic species (*A. radiata*, *K. belliana*, *P. aracnoides*, *G. platynota*). The comparison of two anaesthetic protocols gives us the possibility to recognize the best one; we observed different induction time, muscles relaxation and different awakening from anaesthesia in *G. platynota* using the two protocols; we demonstrated that the protocol with the combination of alfaxalone and dexmedetomidine provides a better sedation to perform coelioscopy than alfaxalone alone. Since we couldn't collect enough data in other species, we didn't have, currently, the possibility to make the same comparison. Moreover, the author observed different species response to the same anaesthetic protocols (these

evaluations have not yet been published because we lack enough data to have the possibility to make a scientific comparison). All these data could be important because, currently, there are just clinical reports about coelioscopic anaesthetic protocols and there aren't studies that compare different species and different protocols.

Intrathecal anaesthesia has been performed for several procedure of the half behind of the chelonian body; no study has been carried on about cloacoscopy performed with and without this kind of anaesthesia. We performed it in 13 north American pond sliders (*Trachemys scripta*) which were submitted to cloacoscopy and we demonstrated that intrathecal anaesthesia guarantees a better muscle relaxation and reduce drastically the time of the procedure; moreover, the use of anaesthetic protocols, also for this less invasive procedure, is a right solution to perform it in respecting animal welfare. Furthermore, we have used the same dosage reported in literature (2 mg/kg lidocaine) and we recorded the same induction time and the same duration of the anaesthesia previously reported.^{18,19,20}

To conclude in this PhD thesis has been demonstrated the powerful of cloacoscopy as good coelomic diagnostic technique, as well as good gender identification technique for lizards and chelonians, despite, in this case, it works better with aquatic than terrestrial chelonians (in which we demonstrated that coeloscopy is the gold standard method, at least in *G. platynota*). The anaesthetic protocols used to perform coeloscopy were already studied but never compared each other and never compared between species; the intrathecal anaesthesia was performed for the first time for cloacoscopy and has been evidenced that is a good and right practice. In authors opinion, further studies are necessary to evaluate which is the best way to recognize gender in chelonians, especially comparing different species, and to better understand anaesthesia which is again a challenge for the clinician.

REFERENCES

1. Capello V., Lennox A.M. (2011). Diagnostic Imaging of the Respiratory System in Exotic Companion Mammals. *Journal of Veterinary Clinics Exotic Animal Practice*. Vol 14. pg 369–389
2. Hernandez-Divers S.J. (2008). Clinical Technique: Dental Endoscopy of Rabbits and Rodents. *Journal of Exotic Pet Medicine*. Vol 17(2). pg 87–92 5)
3. Hernandez-Divers S.J., Stahl S.J., Camus A. (2010). Evaluation of diagnostic coelioscopy including liver and kidney biopsy in freshwater turtles (*Trachemys scripta*). *Journal of Zoo and Wildlife Medicine*. Vol 41. pg 677–687.
4. Hernandez-Divers S.J. (2019). Diagnostic Endoscopy. In: Hernandez-Divers S.J., Stahl S.J. (Eds.), *Mader's Reptile and Amphibian Medicine and Surgery* (Third edition). Elsevier Inc.. St. Louis. pg 604-614
5. Hernandez-Divers S.J. (2015). Making the difference in Exotic Animal Practice: the Value of Endoscopy. *Journal of Veterinary Clinics Exotic Animal Practice*
6. Hernandez-Divers S.J. (2010). Endoscopy Equipment and Instrumentation for Use in Exotic Animal Medicine, *Journal of Veterinary Clinics Exotic Animal Practice*, vol 13, pg 171–185
7. Hernandez-Divers S.J. (2011). Rigid Endoscopy in Exotic Companion Animals: a New Era in Minimally Invasive Diagnostics and Surgery. *North America Veterinary Clinics Conference*, pg 1695-1699
8. Capello V., Lennox A.M. (2011). Diagnostic Imaging of the Respiratory System in Exotic Companion Mammals. *Journal of Veterinary Clinics Exotic Animal Practice*. Vol 14. pg 369–389

9. Hernandez-Divers S.J. (2008). Clinical Technique: Dental Endoscopy of Rabbits and Rodents. *Journal of Exotic Pet Medicine*. Vol 17(2). pg 87–92 5)
10. Hernandez-Divers S.J., Stahl S.J., Camus A. (2010). Evaluation of diagnostic coelioscopy including liver and kidney biopsy in freshwater turtles (*Trachemys scripta*). *Journal of Zoo and Wildlife Medicine*. Vol 41. pg 677–687.
11. Hernandez-Divers S.J. (2019). Diagnostic Endoscopy. In: Hernandez-Divers S.J., Stahl S.J. (Eds.), *Mader's Reptile and Amphibian Medicine and Surgery* (Third edition). Elsevier Inc.. St. Louis. pg 604-614
12. Hernandez-Divers S.J. (2015). Making the difference in Exotic Animal Practice: the Value of Endoscopy. *Journal of Veterinary Clinics Exotic Animal Practice*
13. N. Di Girolamo, P. Selleri, Clinical Applications of Cystoscopy in Chelonians, *Journal of 36 Veterinary Clinics Exotic Animal Practice*, vol 18, pp 507–526, 2015
14. Morici M., Di Giuseppe M., Oliveri M., Knotek Z. & Spadola F. (2017). Cloacoscopic sex determination in Tegu lizards. *Proceedings of Venice Icare 2017*: 544-545
15. Gross T.S., Crain D.A., Bjordal K.A., Bolten A.B., Carthy R.R. (1995). Identification of Sex in Hatchling Loggerhead Turtles (*Caretta caretta*) by Analysis of Steroid Concentrations in Chorioallantoic/Amniotic Fluid. *General and Comparative Endocrinology*, Vol 99, pg 204-210
16. Xia Z.R., Li P.P., Gu H.X., Fong J.J., Zhao E.M. (2011). Evaluating Noninvasive Methods of Sex Identification in Green Sea Turtle (*Chelonia mydas*) Hatchlings. *Chelonian Conservation Biology*, Vol 10, pg 117–123
17. Tezak B., Sifuentes-Romero I., Milton S., Wyneken J. (2021). Identifying Sex of Neonate Turtles with Temperature-dependent Sex Determination via Small Blood Samples. *Scientific Report* Vol 10, pg 5012. <https://doi.org/10.1038/s41598-020-61984-2>
18. Mans C. (2014). Intrathecal drug administration in turtles and tortoises. *Journal of Exotic Pet Medicine*. Vol 23(1). pg 67-70
19. Rivera S., Divers S.J., Knafo S.E., Martinez P., Kayot L.J., Tapia-Aguilera W., Flanagan J. (2011). Sterilization of hybrid Galapagos tortoises (*Geochelone nigra*) for island restoration. Part 2: phallectomy of males under intrathecal anaesthesia with lidocaine. *Veterinary Records*. Vol 168. pg 78
20. Makau C.M., Towett P.K., Abelson K.S.P., Kanui T.I. (2014). Intrathecal administration of clonidine or yohimbine decreases the nociceptive behavior caused by formalin injection in the marsh terrapin (*Pelomedusa subrufa*). *Brain Behaviour*. Vol 4(6). pg 850-857

Chapter 4 - Further works during the PhD period

During the 3 years of the PhD period, the candidate has produced different collateral works not directly correlated to the main project.

In the candidate's opinion, these works deserve to be included because of their inherence to reptile and exotic animal practice *sensu lato* or wildlife and conservation practice. They consist, from the less to the most recent, in:

- A case report on first Italian case in mycobacteriosis in pet rabbit; this case report was performed during routinary clinical practice of the candidate
- A case report on the use of thrombocyte-leukocyte rich plasma (TLRP) to treat chronic oral cavity disorders in two species of reptiles. This work was the result of a multidisciplinary collaboration between the candidate and different sections of the Veterinary Teaching Hospital and the Department of Veterinary Medicine of this University, including Anaesthesia Section, Imaging, Pathology and Clinical Pathology Sections of University of Milan.
- A case report of isolation of *Trichophyton erinacei* from a European hedgehog (*Erinaceus europaeus*) in Italy, this is the first report of this pathogen in our country, and it has been isolated during a survey performed on cutaneous microbiology of European hedgehog. This survey has been performed during clinical practice of the candidate in the Wildlife Rescue Centre close to Milan where he works and in collaboration with the Microbiology department of University of Milan.
- A survey on *Toxoplasma gondii* and *Neospora caninum* infection in wild birds of prey admitted in the Wildlife Rescue Centre in which the candidate works, in this survey we evaluated prevalence of infection in several species of birds of prey. This survey has been performed in collaboration with the Parasitology department of University of Milan.

First Italian case of mycobacteriosis in a pet rabbit

Emanuele Lubian MedVet, GPCert(ExAP)^{1,4,7}; **Serena Famà** MedVet²; **Roberta Peradotto** MedVet³; **Matteo Lodi** MedVet, PhD⁵; **Lucia Rita Gibelli** MedVet⁶; **Edoardo Bardi** MedVet, GPCert(ExAP)^{1,4}

Keywords - Mycobacterium, rabbit, mycobacteriosis, zoonosis.

¹ MyPetClinic, Milan, Italy

² Ambulatorio veterinario Dr Famà, Vidigulfo, Pavia, Italy

³ Petlife, Basiglio, Milan, Italy

⁴ Small Animal Veterinary University Hospital, Università degli Studi di Milano, Italy

⁵ Ecografia Veterinaria Città Studi, Milan, Italy

⁶ Histology Laboratory, Istituto Zooprofilattico Sperimentale della Lombardia ed Emilia Romagna, Milan, Italy

⁷ Faculty of Veterinary Medicine, Messina, Italy

*Corresponding Author (emanuele.lubian@hotmail.com)

Received: 08/11/2018 - Accepted: 05/11/2019

Work already presented as a poster at the SCIVAC Rimini International Congress 2018 and at ExoticsCon 2018.

Mycobacteriosis are important zoonoses and clinicians should be aware of their potential risks. A rescued 3-year-old rabbit was presented for acute rhinitis. After 10 days of antibiotic therapy, no improvement was noted and intermittent diarrhoea, dysorexia and weight loss arose. The patient was hospitalized and haematological and faecal examinations were performed. A later ultrasound examination showed intestinal subocclusion. After stabilization, an explorative laparotomy was performed and several caseous nodules were found on the small intestine walls. The rabbit was euthanized and necropsy showed other nodules in the lungs, along with swelling of mesenteric lymph nodes. Cytological and histological examination revealed the presence of acid-fast-resistant bacteria, which were identified as *Mycobacterium avium*. Mycobacterial infections are uncommon in pet rabbits but their potential impact on human health and the unspecific clinical signs should suggest to include them in the differential diagnoses for respiratory and gastrointestinal disorders.

Mycobacteriosis are important zoonoses and clinicians should be aware of their potential risks. A rescued 3-year-old rabbit was presented for acute rhinitis. After 10 days of antibiotic therapy, no improvement was noted and intermittent diarrhoea, dysorexia and weight loss arose. The patient was hospitalized and haematological and faecal examinations were performed. A later ultrasound examination showed intestinal subocclusion. After stabilization, an explorative laparotomy was performed and several caseous nodules were found on the small intestine walls. The rabbit was euthanized and necropsy showed other nodules in the lungs, along with swelling of mesenteric lymph nodes. Cytological and histological examination revealed the presence of acid-fast-resistant bacteria, which were identified as *Mycobacterium avium*. Mycobacterial infections are uncommon in pet rabbits but their potential impact on human health and the unspecific clinical signs should suggest to include them in the differential diagnoses for respiratory and gastrointestinal disorders.

CASE REPORT

INTRODUCTION

Mycobacteriosis are major zoonotic diseases and veterinarians should be aware of their potential consequential risks. Bacteria belonging to the genus *Mycobacterium* are aerobic, acid-resistant, immobile, non-spore forming Gram-positive pleomorphic bacilli that are highly resistant to environmental conditions.¹

Tubercular mycobacteria (in particular *M. tuberculosis*) are still today a serious global health threat:² it is estimated that approximately one third of the world's population is infected and in 2010 the World Health Organization (WHO) reported 8.8 million new cases worldwide.^{3,4} In human medicine, *M. tuberculosis* is normally associated with pulmonary, spinal and musculoskeletal disorders.^{5,6}

With regard to mycobacteriosis in the rabbit, most of our knowledge derives from the fact that this species has been widely used as an experimental model for therapeutic protocols and to study immune responses, immune biomarkers as well as vaccine immunity.^{2,5,7}

Mycobacteriosis caused by non-tubercular mycobacteria are the cause of increasing concern in immunocompetent and non-immunocompetent human patients, as well as in many animal species where they cause focal dermal lesions or systemic infections.⁸ The various subspecies of *M. avium* are extremely widespread in the environment and can come into contact with human and animal hosts; the infection can be transmitted from animals to humans through contaminated food or via direct contact.⁹ Reports of mycobacteriosis in pet rabbits are few and only refer to non-tubercular mycobacteria (in particular the *M. avium* complex); the clinical signs reported in such cases are heterogeneous and consist of chronic rhinitis, emaciation and joint swelling.^{10,11} The anatomopathological lesions described include nodular inflammatory lesions of the lungs, liver, kidneys, intestine, lymph nodes and joints.^{10,11}

Mycobacterium avium has been isolated as a pathogen in both adult and young animals; contact with avian droppings is the suspected source of infection.^{11,12} The diagnosis can be made by culture, histology or polymerase chain reaction (PCR).¹

CLINICAL CASE

A rescued, 3-year-old, 2.5 kg castrated male rabbit was presented for acute rhinitis. The patient could roam freely in a flat with access to the balcony; the owner also had two clinically healthy guinea pigs and a hamster, which had no direct contact with the rabbit. The clinical examination only showed the presence of bilateral mucosal rhinitis. An oral therapy with enrofloxacin 10 mg/kg q24h [Baytril tablets 50 mg - Bayer S.p.A.] was started.^{13,14} A second clinical examination was performed 10 days later; no improvement was detected and in addition signs of occasional diarrhoea, dysorexia and weight loss were now present. The patient was hospitalized and the ongoing therapy was integrated with metoclopramide 2 mg/kg SC q12h [Vomend injectable 5mg/ml - Eurovet Animal Health B.V.],¹⁵ meloxicam 0.5 mg/kg SC q24h [Metacam injectable 5 mg/ml - Boehringer Ingelheim S.p.A.],¹⁶ subcutaneous fluid therapy with saline solution [Sodium chloride 0.9% - B. Braun Milano S.p.A.] corresponding to 2% of the body weight q24h and a diet change (higher amount of fibre - increasing the quantity of hay - and lower amount of carbohydrates). During hospitalization, haematological, haematobiochemical and parasitological faecal tests were performed. The blood count and parasitology test did not show any alterations; the blood and biochemistry examination showed hypophosphatemia (1 mmol/L) and hypotriglyceridaemia (109 mg/dL).¹⁷ After an initial recovery, and despite the good appetite, after a few days the rabbit started again to lose weight. An abdominal ultrasound examination was then performed, revealing the presence of abdominal effusion, abundant

meteorism of the cecum and colon, thickening of the wall of the small intestine with loss of the normal echostructure and presence of a suspected subocclusion; the liver, gallbladder and kidneys did not present any alterations [Fig. 1]. To confirm the diagnostic suspicion an exploratory laparotomy was performed: the patient was premedicated with dexmedetomidine (0.05 mg/kg) [Sedastart 1mg/ml injectable solution - Esteve SpA], butorphanol (0.1 mg/kg) [Dolorex 10mg/ml injectable solution - MSD Animal Health S.R.L.] and ketamine IM (5mg/kg) [Imalgene 100 mg/ml injectable solution - Merial Italia SpA];¹³ mask induction was achieved with isoflurane [Vetfluorane vial 100 mg/g - Virbac S.R.L.]; the rabbit was then intubated with a 2.5 mm orotracheal catheter and the anaesthesia was maintained by inhalation with 1.5% isoflurane in 100% oxygen. Upon opening of the abdominal cavity numerous caseous nodular lesions (diameter from 1 to 10 mm) were immediately detected in the serosa and intestinal wall [Fig. 2]. Being these lesions responsible for the intestinal subocclusion, intraoperative euthanasia was performed by intravenous administration of a commercial formulation [Tanax injectable solution - MSD Animal Health S.R.L.], followed by necropsy. The *post mortem* examination showed the presence of numerous intestinal nodules (some occupying the entire space and responsible for the sub-occlusion) and pulmonary nodules [Fig. 3], in addition to mesenteric lymph node enlargement (5-8 mm in diameter). Cytological examination of the lesions and lymphnodes revealed the presence of numerous macrophages and multinucleated giant cells with abundant basophilic cytoplasm and containing several optically clear, rod-shaped vacuolizations compatible with the presence of *Mycobacterium sp.* Given the suspicion of mycobacteriosis, the entire corpse was sent to the Istituto Zooprofilattico Sperimentale (IZS) in Brescia to perform a necropsy, which revealed the presence of granulomatous enteritis, lymphadenitis and pneumonia characterized by the presence of numerous multinucleated cells. Ziehl-Neelsen staining revealed a myriad of intracellular acid-alcohol-resistant bacilli in the cytoplasm of multinucleated giant cells. PCR confirmed the definitive diagnosis of mycobacteriosis caused by *M. avium* [Fig. 4, Fig. 5].

DISCUSSION

Mycobacteriosis is still a poorly described disease in the domestic rabbit and, to the knowledge of the authors, this work represents the first report of the disease in a rabbit in Italy.¹

In most animals, mycobacteriosis appears as a slow and progressive disease. The *Mycobacterium avium* complex has been isolated in birds, humans, bovids, dogs, cats, rodents and rabbits. In these species the main clinical signs reported are similar to the ones of the clinical case presented, i.e. lethargy and weight loss. The symptoms, which can be intermittent, are: vomiting, anorexia, diarrhoea, haematochezia, fever; more rarely, also: lameness, paresis, hyperesthesia, subcutaneous swelling, anterior uveitis, dyspnoea. As for the clinical conditions of the patient in question, the symptoms were already known to be potentially compatible with mycobacteriosis.¹⁸ The case is important as the patient was initially brought in and treated for symptoms common in several diseases that are epidemiologically more frequent in this species, and the final diagnosis was reached only *post mortem*, relying on a reference centre.

Pathogens that spread through the environment, wildlife, livestock and human movements are a major challenge for the safeguard of human health, for the protection of pets, for agricultural management and for the preservation of wildlife. In wild rabbits only few reports on mycobacteriosis are available and hence the epidemiological role of this species has not yet been clarified.¹

Since mycobacteria infections are important zoonotic infections and a real threat to public health, it is the duty of the clinical veterinarian to include them in differential diagnoses in the case of wild, rescued or unknown subjects.

REFERENCES

1. Arrazuria R, Juste RA, Elguezabal N. Mycobacterial Infections in Rabbits: From the Wild to the

- Laboratory. *Transboundary and emerging diseases* 64: 1045-1058. 2017.
2. Chen H, Liu X, Ma X et al. A New Rabbit-Skin Model to Evaluate Protective Efficacy of Tuberculosis Vaccines. *Frontiers in Microbiology* 8:842. 2017.
 3. Lönnroth K, Castro KG, Chakaya JM et al. Tuberculosis control and elimination 2010-50: cure, care, and social development. *The Lancet* 375: 1814-1829. 2010.
 4. Ramsay A, Steingart KR, Cunningham J et al. Translating tuberculosis research into global policies: the example of an international collaboration on diagnostics. *International Journal of Tuberculosis and Lung Disease* 15: 1283–1293. 2011.
 5. Guo XH, Bai Z, Qiang B et al.. Roles of monocyte chemotactic protein 1 and nuclear factor- κ B in immune response to spinal tuberculosis in a New Zealand white rabbit model. *Brazilian Journal of Medical and Biological Research* 50(3): e5625. 2017.
 6. Dehnad A, Ravindran R, Subbian S et al. Development of immune-biomarkers of pulmonary tuberculosis in a rabbit model. *Tuberculosis (Edinb)* 101:1-7. 2016 .
 7. Lanoix JP, Tasneen R, O'Brien P et al. High Systemic Exposure of Pyrazinoic Acid Has Limited Antituberculosis Activity in Murine and Rabbit Models of Tuberculosis. *Antimicrobial Agents and Chemotherapy* 20; 60(7):4197-4205. 2016.
 8. Pekkarinen H, Airas N, Savolainen LE et al. Non-tuberculous Mycobacteria can Cause Disseminated Mycobacteriosis in Cats. *Journal of Comparative Pathology* 160:1-9. 2018.
 9. Arrazuria R, Sevilla IA, Molina E et al. Detection of Mycobacterium avium subspecies in the gut associated lymphoid tissue of slaughtered rabbits. *BMC Veterinary research* 11-130: 1-11. 2015.
 10. Kelleher SA. Rabbit respiratory diseases. *Proceedings of the 80th Western Veterinary Conference, Las Vegas, 2008.* pp. v471.
 11. Lehmecker A, Pfeifer F, Moser I et al. Kaninchen, Arthritis, Tuberkulose, Mycobacterium avium ssp. avium-Spontane enzootische aviare Tuberkulose bei Hauskaninchen (*Oryctolagus cuniculus*). *Kleintier Praxis* 55: 21. 2010.
 12. Kriz, P, Slana I, Kralik P et al. Outbreak of Mycobacterium avium subsp. avium infection in one flock of domestic pigeons. *Avian Disease* 55: 503–508. 2011.
 13. Carpenter JW. *Exotic animals formulary*, fourth edition. 2013. 519.
 14. Elmas M, Uney K, Yazar E et al. Pharmacokinetics of enrofloxacin following intravenous and intramuscular administration in Angora rabbits. *Research in Veterinary science.* 82(2): 242-245. 2007.
 15. Schuhmann B, Cope I. Medical treatment of 145 cases of gastric dilatation in rabbits. *Veterinary records* 175(19): 484. 2014.
 16. Delk KW, Carpenter JW, Kukanich B et al. Pharmacokinetics of meloxicam administered orally to rabbits (*Oryctolagus cuniculus*) for 29 days. *American Journal of Veterinary Research.* 75(2):195- 199. 2014.
 17. Di Girolamo N, Nardini G. Patologia clinica dei piccoli mammiferi esotici. *Veterinaria.* 31(4):189-196. 2017.
 18. Greene CE, Gunn-Moore GA. Mycobacterial Infections. In: *Infectious disease of dog and cat.* Fourth edition. St. Louis (Missouri): Elsevier. 2012. 500.

Use of thrombocyte-leukocyte rich plasma to treat chronic oral cavity disorders in reptiles: two case reports

Bardi E¹, Vetere A², Aquaro V³, Lubian E^{1,4}, Lauzi S^{1,5}, Ravasio G^{1,5}, Zani DD^{1,5}, Manfredi M^{1,5}, Tecilla M¹, Roccabianca P¹, Romussi S¹

¹ Department of Veterinary Medicine, University of Milano, via Celoria 10, 20133 Milan, Italy

² Ambulatorio Veterinario, via Galvani 42, 20083 Gaggiano, Italy

³ Bosco SIC "Difesa Grande", Gravina di Puglia, Italy

⁴ Wildlife Rescue Centre LIPU "La Fagiana", via Valle, 20013 Pontevecchio di Magenta, Italy

⁵ Veterinary Teaching Hospital, University of Milan, via dell'Università 6, 26900 Lodi, Italy

Corresponding Author

Address correspondence to: Edoardo Bardi DVM, PhD Student, via Daniele Manin 37, 20121 Milano, Italy.

E-mail: edoardo.bardi@unimi.it Telephone: +39

3898298365

INTRODUCTION

Disorders of the oral cavity represent common conditions in pet reptiles.¹ Multiple predisposing factors including immunosuppression, chronic stressful conditions, inappropriate husbandry, disruption of normal oral tissue or systemic disease¹⁻⁴ may lead ultimately to infectious stomatitis. Treatment usually involves correction of environmental parameters, appropriate systemic and topical antimicrobial therapy and surgical debridement or resection of affected areas.^{1,2,5} Periodontal disease is another common oral condition, especially in acrodont lizards such as agamids and chameleons.⁶ The major cause of periodontal disease are considered inappropriate diets characterized by soft fruit or wax worms excess that facilitate bacterial colonization, plaque development and gingivitis. Treatment consists in calculus removal along with topical irrigation with antibacterial solutions.^{1,6}

Both conditions may progress to osteomyelitis with pathologic fractures and/or systemic infections,^{1,2,6,7} leading to spontaneous decease^{2,7} or to euthanasia.^{3,4,8}

The progressive reduction of antibiotic efficacy and the search for novel therapeutical approaches have raised interest in regenerative medicine compounds such as platelet-rich blood derivates. Platelet-Rich Plasma (PRP) is a biologically active product composed of platelets obtained by centrifugation of patient's whole blood and re-suspended in plasma characterized by elevated concentrations of growth factors and chemotactic molecules.⁹⁻¹⁵ PRP has been mostly applied to orthopedical, dermatological and ophthalmological conditions in horses and dogs and,¹⁶⁻¹⁹ have recently gained interest in exotic animal practice.²⁰⁻²² Our aim was to evaluate the efficacy of Thrombocyte-Leukocyte Rich Plasma (TLRP), a PRP compound, in chronic oral cavity disorders in

reptiles. We illustrate two cases of reptiles treated with a single injection of heterologous TLRP, specifically one ball python (*Python regius*) with chronic stomatitis, and one veiled chameleon (*Chamaeleo calypttratus*) with severe maxillary osteolysis secondary to chronic periodontal disease.

CASES

Case 1

A 4-year-old male ball python presented with facial swelling of one year duration but still regularly feeding on adult mice. The snake was housed at 30°C (86°F) in a rack system with another adult conspecific. Clinical examination revealed severe soft swelling of the right maxillary and periorbital region encompassing the right eye. Oral cavity examination revealed hyperemia and swelling of the right maxillary region with loss of the teeth of the secondary arcade, and moderate presence of mucus. An excisional biopsy was submitted for histopathology, with a diagnosis of moderate chronic multifocal granulomatous stomatitis with fibrosis (Fig. 1). *Klebsiella* spp. and *Pseudomonas aeruginosa* sensitive to the most common antibiotics were isolated from superficial and deep sterile swabs obtained during surgical biopsy procedure. A blood sample taken by cardiocentesis was characterized by 9% of immature erythrocytes, while other hematological and biochemical values were unremarkable. A head Computed Tomography (CT) scan revealed marked heterogenous swelling of the soft tissues of the right portion of the skull with minimal osteolysis of the post-frontal right orbital region (Fig. 2). Therapy consisted of surgical debridement and TLRP irrigation since, the granulomatous and fibrosing lesions were unlikely to respond to local or systemic antibiotics. Heterologous TLRP was obtained from a healthy conspecific according with a previously described protocol (Fig. 3).²⁰

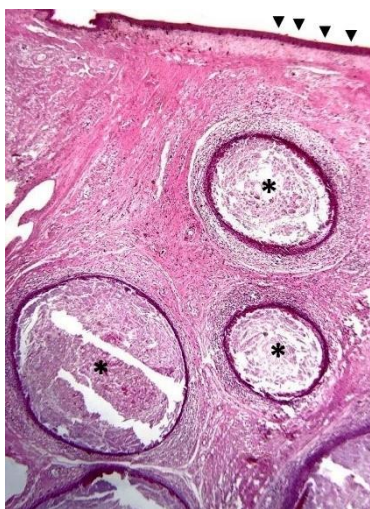


FIGURE 1 - Case 1: subcutaneous tissue and skin of a ball python (*Python regius*). Underlining the normal skin (arrowheads), the dermis is expanded by the presence of multiple granulomas, ranging from 1 mm up to 5 mm (asterisk). 1.6x – Hematoxylin and Eosin.

Debridement was accomplished under general anesthesia by an intraoral approach. Granulomas had substituted periorcular tissues and engulfed the eye thus, globe enucleation was also performed. A longitudinal incision was made between the primary and secondary maxillary arcades, tissues were bluntly dissected, and granulomas were removed with a mixed technique of sharp and blunt dissection (Fig. 4). Following debridement, the wound was irrigated with

0.5 mL of TLRP. The oral side was closed with appositional single 3.0 polydioxanone sutures,^a while the cutaneous side was closed with an everting single 3.0 coated polyglycolic sutures.^b Meloxicam^c 0.5 mg/kg SC was administered after surgery while, due to the antimicrobial properties of TLRP, antibiotic therapy was postponed.

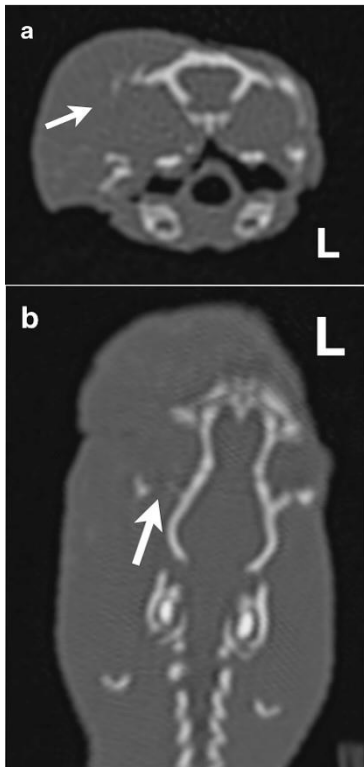

FIGURE 2 - Case 1: Transverse (a) and dorsal (b) Multiplanar Reconstruction (MPR) CT images of the head of a ball python (*Python regius*) in bone window, showing post frontal bone osteolysis (arrows).

The snake was hospitalized for 70 days and maintained between 27°C-30°C (80.6-86°F)^{23,24} with no additional therapies. On the tenth day, a small mouse was accepted, and dehiscence of the cutaneous and oral sutures occurred during swallowing, revealing normal granulation tissue in the wound bed (Fig. 5a). Margins of the cutaneous wound side were about 10 mm apart, while margins of the mucosal wound were approximately 15 mm distant. The following day the oral mucosa had spontaneously closed by secondary intention with complete re-epithelization (Fig. 5b). A thick scab covered the cutaneous wound side. CT scan was repeated after 30 days showing no significant bone changes. Forty-eight days after surgery, the cutaneous scab detached during ecdysis. Almost complete re-epithelization

was documented (Fig. 5c). At day 66, cutaneous wound margins were 6 mm apart, while the epithelization was complete without scale formation (Fig. 5d).

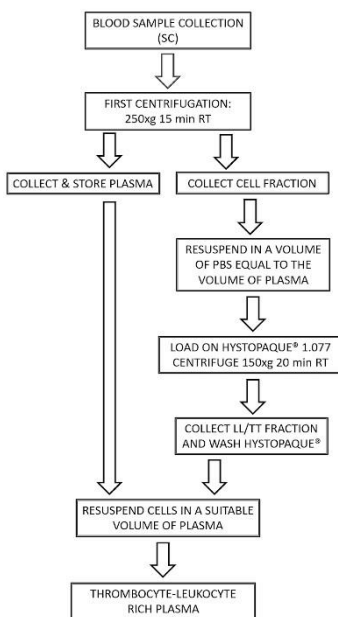


FIGURE 3 - Flowchart of the preparation of reptile TLRP as described by Di Ianni *et al.*²⁰ Blood was collected by cardiocentesis in the ball python (*Python regius*) (2 mL) and by venipuncture of the ventral coccygeal vein in the veiled chameleon (*Chamaeleo calypttratus*) (1.6 mL). After collection, blood was stored in sodium citrate (SC) test tubes. After a first centrifugation step, blood cells were fractionated on a Histopaque® 1.077 gradient and leukocytes/thrombocytes (LL/TT) collected to prepare the TLRP.

Case 2

A 2.5-year-old male veiled chameleon was presented for anorexia and adipisia. The reptile was housed in a glass terrarium with poor environmental enrichment, with a correct UVB light spot, but without any hot spot nor monitoring of temperature and humidity. The patient was fed mainly wax worms and crickets with no mineral or vitamin supplementation. Forced feeding was initiated 4 days before presentation. At clinical examination a weight of 152 g, a body condition score between 2 and 3 out of 5,²⁵ minimal dehydration (<2,5%) and right enophthalmos were observed. Severe right maxillary periodontitis, plaque accumulation, gingival swelling and necrotic debris characterized the oral cavity.

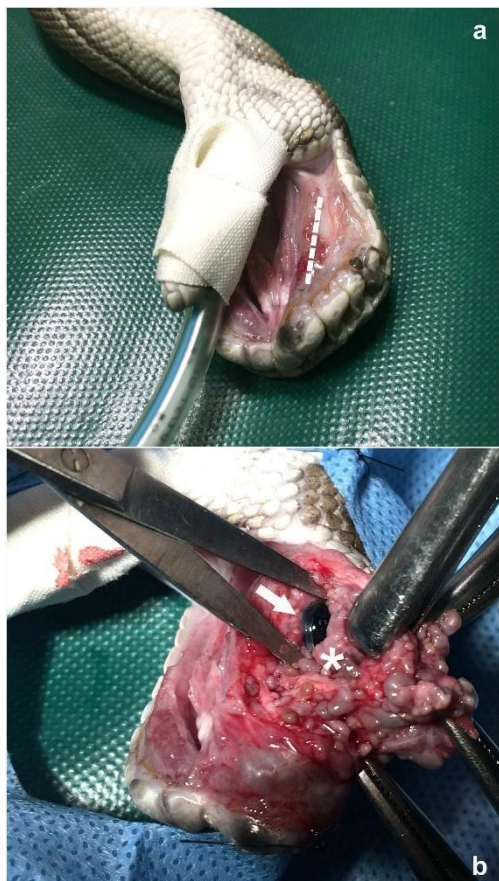
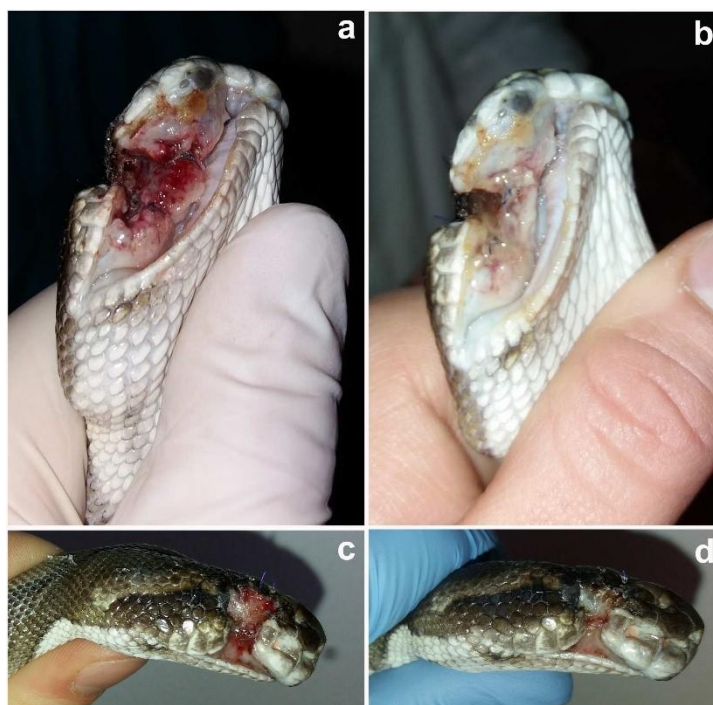

FIGURE 4- Case 1: surgical debridement of multiple subcutaneous granulomas in the right maxillary region of a ball python (*Python regius*) with intraoral approach. **a:** snake in dorsal recumbency, the lower jaw was pushed aside and taped to the orotracheal tube; a longitudinal incision was made between the primary and secondary maxillary arcades (dotted line). **b:** tissues were bluntly dissected to reach the lesion. Granulomas had substituted periocular tissues (asterisk) and engulfed the eye (arrow). Granulomas were removed with a mixed technique of sharp and blunt dissection, and globe enucleation was performed. Before closing, surgical wound was irrigated with TLRP.

Necrosis extended to vomer and palatine bones with oral asymmetry (Fig. 6). A mucosal swab was taken for microbiological examination including sensitivity tests, with isolation of *Proteus* spp. and *Aeromonas* spp. Therapy consisted of metronidazole^d 20 mg/kg *per os* q48h,²⁶ marbofloxacin^e (later confirmed by sensitivity test) 10 mg/kg SC q48h,²⁷ local detersion with diluted chlorhexidine^f q12h² and oral rehydration. After ten days, there was no clinical improvement. A complete blood work and a CT scan were performed. Marked leukocytosis with heterophilia and lymphocytosis was observed, while

most of the other values were within normal ranges (Table 1).

FIGURE 5 - Case 1: post-surgical follow-up in a ball python (*Python regius*) after surgical debridement of multiple subcutaneous granulomas. **a:** day 10, while swallowing a prey, sutures dehiscence occurred leaving the wound open, revealing bright red granulation tissue and absence of pathologic discharge. **b:** day 12, complete closure by secondary intent of the mucosal side of the surgical wound. **c:** day 48, loss of the cutaneous scab due ecdysis. Re-epithelization is almost complete. **d:** day 66, complete re-epithelization of the cutaneous side of the surgical wound.



Since reference intervals reported in literature regarding uricemia and phosphatemia are discordant,²⁸⁻³⁰ it was resorted to integrate therapy with allopurinol^g 20 mg/kg *per os* q24h³¹ and aluminium hydroxide^h 100 mg/kg *per os* q24h.³² CT scan showed a oro-orbital fistula with massive osteolysis of the right portion of the rostral skull, involving the rostro-ventral and rostro-dorsal

portion of the frontal bone, the caudal portion of the jugal bone and ventral portion of the maxillary bone (Fig. 7).

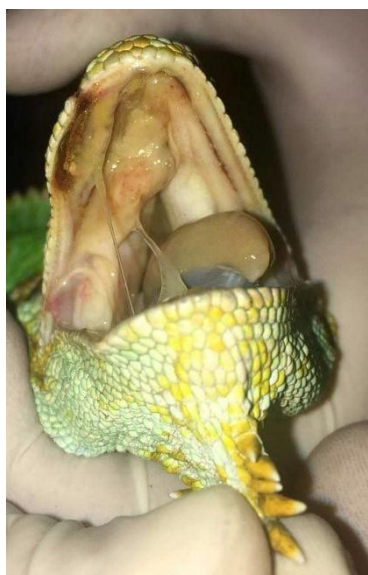

FIGURE 6 - Case 2: veiled chameleon (*Chamaeleo calypttratus*) with severe right maxillary periodontitis, plaque, gingival swelling and necrotic fibrin membranes; oral asymmetry due to necrosis and swelling of vomer and palatine bone.

After one month, no improvement was noted, and antimicrobial therapy was interrupted. To preserve anatomical integrity and chewing physiology surgery was not feasible. Heterologous TLRP (0.2 mL) was obtained from a healthy conspecific as previously described and injected with a 26G syringe directly into the necrotic bone to promote bone healing. The patient was dismissed with indication of daily oral cavity detersion and allopurinol therapy.

Table 2 –Case 2: CBC results and altered values in blood chemistry of a veiled chameleon (*Chamaeleo calypttratus*). Altered values are reported in bold.

Analyte	Value	Unit of measure	Reference values*
PCV	26	%	12 – 37
RBC	0.68	10 ⁶ /μL	-
WBC	34.4	10 ³ /μL	1.2 – 21.0
HET	19.6	10 ³ /μL	0.5 – 8.32
LYM	13.41	10 ³ /μL	0.07 – 10.8
MON	1.37	10 ³ /μL	-
EOS	0	10 ³ /μL	-
BAS	0	10 ³ /μL	-
Uric acid (UA)	8	mg/dL	0 – 21.9
Phosphate (PO ₄)	3.5	mmol/L	4.4 – 16.1
Sodium (Na ⁺)	125	mmol/L	132 - 169

*Klaphake *et al.*, 2018

Seven days after injection, the owner reported clinical improvement, weight gain (171g) and reprise of spontaneous drinking. At clinical examination reduction of soft tissue swelling, of necrotic discharge and improved mobility of the right eye were documented (Fig. 8a). At day 26, there was a marked improvement of clinical conditions, with considerable reduction of the oral mucosal swelling and necrosis, resolution of right vomer and palatine bone asymmetry (Fig. 8b). Enopthalmos was still present but the eye was open and mobile. The same day a control CT scan showed no bone lysis progression. Complete return to spontaneous feeding was achieved 27 days after TLRP injection. Uric acid and phosphate returned to acceptable levels after 60 days

of allopurinol, that was suspended. Seventy-seven days after treatment, a third CT scan was performed with the same results of the previous exam.

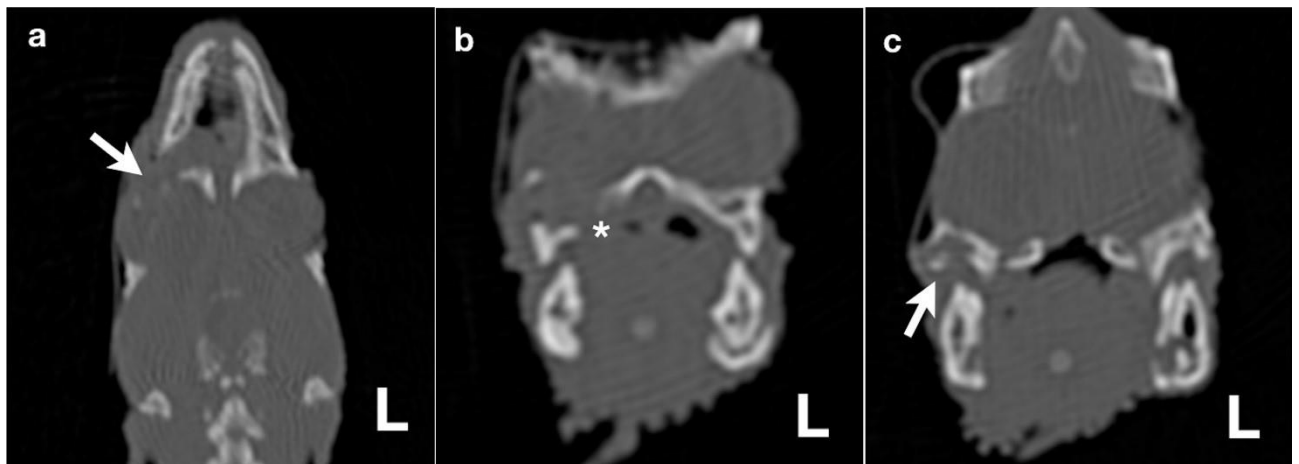


FIGURE 7 - Case 2: ventral (a) and transverse (b, c) MPR CT images of the head of a veiled chameleon (*Chamaeleo calypttratus*) in bone window, showing maxillary bone osteolysis (arrows) and oro-orbital fistula (asterisk).

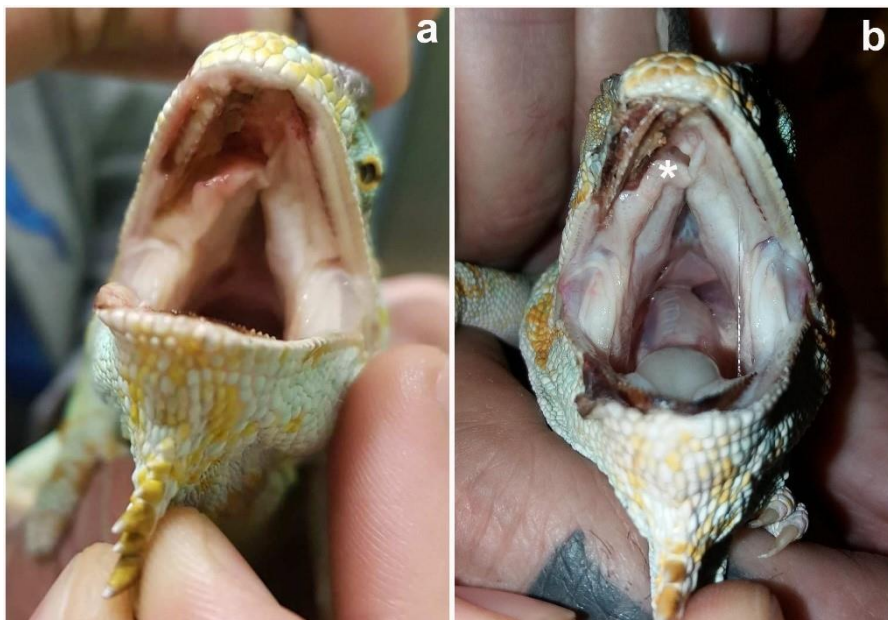


FIGURE 8 - Case 2: Follow-up after intralesional TLRP injection in a veiled chameleon (*Chamaeleo calypttratus*). **a**: day 7, reduction of soft tissue swelling and necrotic discharge, along with an improved mobility of the right eye and great improvement of the clinical conditions. **b**: day 26, marked improvement of clinical conditions, considerable reduction of the oral mucosa swelling and necrosis; swelling and asymmetry of right vomer and palatine bone completely reduced (asterisk).

DISCUSSION

PRP and other platelet-concentrates have been extensively applied in human ophthalmology, orthopedics, dermatology and dentistry regenerative medicine. Despite the extensive scientific literature, their efficacy is still under debate. Controversies lie on the large numbers of protocols available not always comparable, the lack of a validated classification system and the lack of standardized products with great variability between single preparations in platelet, leukocyte and growth factor contents.^{13, 33-35} The aim of this work was to assess the potential role of platelet-concentrates, on the basis of their regenerative and antimicrobial properties, in treating reptilian oral disorders and halting chronic bone lysis. TLRP was obtained following a previous protocol²⁰ with thrombocyte-leukocyte counts paralleling those previously documented.²⁰ TLRP was preferred to simple PRP since, platelets and leukocytes release growth factors and chemotactic molecules including

Interleukin-6 and -4 (IL-6, IL-4), Tumor Necrosis Factor- α (TNF- α), Transforming Growth Factor- β (TGF- β), Insulin-like Growth Factor 1 (IGF-1), basic-Fibroblast Growth Factor (b-FGF), Vascular Endothelial Growth Factor (VEGF) or Platelet-derived Growth Factor (PDGF)^{9,12,36} able to stimulate proliferation of mesenchymal cells including fibroblasts, osteoblasts and endothelial cells. Although scientific literature refers mostly to mammal species, recent publications confirm that these molecules play similar roles in reptile wound healing. Evidence derives from studies regarding growth factors under physiological conditions such as IGF-1 being widely expressed in reptile blood and tissues,³⁷⁻⁴⁰ FGF playing a major role in crocodile teeth replacement,⁴¹ crocodile oil containing TGF- β at concentrations proven to enhance wound healing and reduce scar formation.⁴² Under pathological conditions, tissue IL-6 increases during inflammation in turtles,⁴³ PDGF is highly expressed in lizards spinal cord after tail amputation,⁴⁴ and VEGF contributes to geckos' wound healing and tail regrowth.^{45,46} Since activated platelets release biological factors that have been proven to promote bone regeneration by osteo-competent cells,⁴⁷ our main aim was to stop bone lysis and reabsorption and induce healing and new bone formation in both patients. Noteworthy, platelet concentrates have been observed to stimulate hard tissue healing and regeneration both *in vitro*¹⁴ and *in vivo*, for example after oro-maxillary surgery^{13,48} or orthopedic procedures in human patients.^{18,19,49,50} Furthermore, platelet concentrates have been reported to have antimicrobial properties both *in vitro* and *in vivo*⁴⁹⁻⁵¹ even if, to date, their mechanism of action remains poorly understood. Theories include antimicrobial properties attributed to platelet α -granules components such as complement and complement-binding proteins.⁵¹ Likely, a major role is also played by prestored antimicrobial peptides and enzymes contained in leukocyte granules.³⁶

In the ball python, wound healing was not significantly accelerated by TLRP administration²³ however, TLRP antimicrobial properties were thought to prevent secondary infections during the clinical monitoring, making it possible to avoid post-surgical antibiotic administration.

In the chameleon, one month of antibiotic therapy was ineffective for oral cavity infection clearing and, surgery was considered too invasive and demolitive. Strikingly, following a single TLRP injection, osteolysis stopped with a gradual reduction of oral inflammation. More so, *restitutio ad functionem* was achieved in approximately one month following TLRP injection with no additional therapies. In both cases, control CT scans showed no progression of bone or soft tissue lesions pointing to the likely efficacy of TLRP. TLRP should be considered a safe and possibly reliable tool to stop osteomyelitis progression even without surgical removal of dead bone. Unfortunately, new-bone formation was not observed in either of these cases. Probably, one administration of TLRP may not enable new bone deposition in the observed period of time. Additional injections were not administered due to the lack of scientific data regarding multiple applications of TLRP in reptiles and especially due to the fact that both patients were reasonably improving without further therapies. This approach was

valuable to demonstrate the possible efficacy of the treatment without a secondary role of tissue injury (trauma) associated to multiple injections providing clues for a direct correlation of TLRP in tissue repair.

CONCLUSIONS

This work should be considered a preliminary report assessing the possible role of a single TLRP administration in bone and wound healing in two reptiles. Platelet concentrates could represent an engaging frontier in reptile regenerative medicine since, they are relatively economic, easy to obtain with essential equipment that is easily available in most facilities and can be frozen and stored for heterologous use. In our experience, clinical outcome suggested that TLRP therapy is safe and may contribute to tissue healing by means of its antimicrobial and regenerative properties, even in non-responding chronic lesions previously approached with traditional therapies, as in the second case described herewith. Further studies will be necessary to assess TLRP mechanism of action in reptiles and to determine more efficient protocols, for example by combination with other regenerative techniques or by multiple administrations, as reported in human and mammal medicine.^{19,52}

SOURCES AND MANUFACTURERS

- a. PDS II®, Ethicon, Johnson & Johnson SpA, Pomezia, Italy
- b. Assufile®, Assut Europe SpA, Magliano dei Marsi, Italy
- c. Metacam® 5 mg/mL, Boehringer Ingelheim, Milano, Italy
- d. Flagyl® 250 mg, Zambon Pharma, Bresso, Italy
- e. Marbocyl® FD 10 mg/mL, Vetoquinol, Bertinoro, Italy
- f. Stomodine® gel, ICF srl, Palazzo Pignano, Italy
- g. Allopurinolo, Teva Italia srl, Milano, Italy
- h. Maalox®, Sanofi spa, Milano, Italy

REFERENCES

1. Mehler SJ, Bennett RA: Upper Alimentary Tract Disease, in Mader DR (ed.): Reptile Medicine and Surgery, 2nd edition. St. Louis, MO, Saunders Elsevier, pp 924-930, 2006.
2. Hedley J: Anatomy and disorders of the oral cavity of reptiles and amphibians. Vet Clin North Am Exot Anim Pract 19(3):689-706, 2016.
3. Martínez J, Segura P, García D, Aduriz G, Ibabe JC, Peris B, Corpa JM: Septicaemia secondary to infection by *Corynebacterium macginleyi* in an Indian python (*Python molurus*). Vet J 172(2):382-385, 2006.
4. Czirják GA, Köbölkuti LB, Tenk M, Szakács A, Kelemen A, Spînu M: Hemorrhagic stomatitis in a natural hybrid of *Vipera ammodytes* × *Vipera berus* due to inappropriate substrate in terrarium. J Vet Med Sci 77(6):701-703, 2015.
5. Latney LV, McDermott C, Scott G, Soltero-Rivera MM, Beguesse K, Sánchez MD, Lewis JR: Surgical management of maxillary and premaxillary osteomyelitis in a reticulated python (*Python reticulatus*). J Am Vet Med Assoc 248:1027–1033, 2016.
6. Mans C: Clinical update on diagnosis and management of disorders of the digestive system of reptiles. J Exot Pet Med 22:141-162, 2013.

7. Orozova P, Sirakov I, Petkov I, Crumlish M, Austin B: Recovery of *Aeromonas hydrophila* associated with bacteraemia in captive snakes. *FEMS Microbiol Lett* 334(1):22-2, 2012.
8. Clancy MM, Newton AL, Skyes JM: Management of osteomyelitis caused by *Salmonella enterica* subsp. *houtenae* in a Taylor's cantil (*Agkistrodon bilineatus taylori*) using amikacin delivered via osmotic pump. *J Zoo Wildl Med* 47(2):691-694, 2015.
9. Bielecki T, Dohan Ehrenfest DM: Platelet-Rich Plasma (PRP) and Platelet-Rich Fibrin (PRF): Surgical Adjuvants, Preparations for *In Situ* Regenerative Medicine and Tools for Tissue Engineering. *Curr Pharm Biotechnol* 13:1121-1130, 2012.
10. Gurtner GC, Werner S, Barrandon Y, Longaker MT: Wound repair and regeneration. *Nature* 453:314321, 2008.
11. Kiwanuka E, Junker J, Eriksson E: Harnessing growth factors to influence wound healing. *Clin Plastic Surg* 39:239–248, 2012.
12. Dohan DM, Choukroun J, Diss A, Dohan SL, Dohan AJJ, Mouhyi J, Gogly B: Platelet-rich fibrin (PRF): A second-generation platelet concentrate. Part III: Leucocyte activation: A new feature for platelet concentrates?. *Oral Surg Oral Med Oral Pathol Oral Radiol Endod* 101:51-55, 2006.
13. Anitua A, Alkhraisat MH, Orive G: Perspectives and challenges in regenerative medicine using plasma rich in growth factors. *J Control Release* 157(1):29–38, 2012.
14. Lucarelli E, Beccheroni A, Donati D, Sangiorgi S, Cenacchi A, Del Vento AM, Meotti C, Zambon Bertoja A, Giardino R, Fornasari PM, Mercuri M, Picci P: Platelet-derived growth factors enhance proliferation of human stromal stem cells. *Biomaterials* 24(18):3095-3100, 2003.
15. Dohan Ehrenfest DM, Rasmusson L, Albrektsson T: Classification of platelet concentrates: from pure platelet-rich plasma (P-PRP) to leukocyte- and platelet-rich fibrin (L-PRF). *Trends Biotechnol* 27(3):158-167, 2009.
16. Bosch G, Van Schie HTM, De Groot MW, Cadby JA, van de Lest CHA, Barneveld A, van Weeren PR: Effects of platelet-rich plasma on the quality of repair of mechanically induced core lesions in equine superficial digital flexor tendons: A placebo-controlled experimental study. *J Orthop Res* 28(2):211217, 2010.
17. Dunkel B, Bolt DM, Smith RK, Cunningham FM: Stimulus-dependent release of tissue-regenerating factors by equine platelets. *Equine Vet J* 44(3):346-354, 2012.
18. Parra E, Vergara A, Silva RF: Autologous Platelet Concentrates as Treatment for Avascular Necrosis of Femoral Head in a Dog. *Top Companion Anim Med* 32:31-35, 2017.
19. Nnaji T, Kene R, Chah K, Ero EU: Comparative evaluation of the effects of batroxobin/calcium gluconate-activated platelet-rich plasma and calcium chloride-activated platelet-rich plasma on tibial fractures of Nigerian local dogs. *Comp Clin Path* 27:181-187, 2018.
20. Di Ianni F, Merli E, Burtini F, Conti V, Pelizzone I, Di Lecce R, Parmigiani E, Squassino GP, Del Bue M, Lucarelli E, Ramoni R, Grolli S: Preparation and Application of an Innovative Thrombocyte/Leukocyte-Enriched Plasma to Promote Tissue Repair in Chelonians. *PLoSOne* doi:10.1371/journal.pone.0122595, 2015.
21. Pelizzone I, Di Ianni F: Use of Platelet Concentrate in a osteomyelitis in a *Boa constrictor imperator*. *Proceedings of 3rd International Conference on Avian, herpetological and Exotic mammal medicine (ICARE), Venice, March 25th-29th 2017, pp 412-413, 2017.*
22. Vetere A, Lubian E: Approccio combinato di PRP (platelet rich plasma) modificato e laser terapia come trattamento di lesioni di varia natura negli animali non convenzionali. *Proceedings of 3rd SIVAE International Congress, Rimini, May 26th-28th 2017, p. 408, 2017.*

23. Smith DA, Barker IK, Allen OB: The Effect of Ambient Temperature and Type of Wound on Healing of Cutaneous Wounds in the Common Garter Snake (*Thamnophis sirtalis*). *Can J Vet Res* 52:120-128, 1988.
24. Hodshon RT, Sura PA, Schumacher JP, Odoi A, Steeil JC, Newkirk KM: Comparison of first-intention healing of carbon dioxide laser, 4.0-MHz radiosurgery, and scalpel incisions in ball pythons (*Python regius*). *Am J Vet Res* 74(3):499-508, 2013.
25. Deming C, Greiner E, Uhl EW: Prevalence of *Cryptosporidium* infection and characteristics of oocyst shedding in a breeding colony of leopard geckos (*Eublepharis macularius*). *J Zoo Wildl Med* 39(4):600607, 2008
26. Kolmstetter C: Pharmacokinetics of metronidazole in the green iguana, *Iguana iguana*. *Bull Assoc Rept Amph Vet*, 1998.
27. Coke RL, Isaza R, Koch DE, Pellerin MA, Hunter RP: Preliminary single-dose pharmacokinetics of marbofloxacin in ball pythons (*Python regius*). *J Zoo Wildl Med* 37:6-10, 2006
28. Kölle P: Klinische Labordiagnostik bei Reptilien, in Kraft W, Dürr UM (eds.): *Klinische Labordiagnostik in der Tiermedizin*, 7th edition. Stuttgart, DE, Schattauer GmbH, pp 822-836, 2014.
29. Klaphlake E, Gibbons PM, Sladky KK, Carpenter JW: Reptiles, in Carpenter JW (ed.): *Exotic Animal Formulary*, 5th edition. St Louis, MO, Elsevier Inc., pp. 81-166, 2018.
30. Cuadrado M, Díaz-Paniagua C, Quevedo MA, Aguilar JM, Molina Prescott I: Hematology and clinical chemistry in dystocic and healthy post-reproductive female chameleons. *J Wild Dis* 38(2):395-401, 2002.
31. Hernandez-Divers SJ, Martinez-Jimenez D, Bush S, Latimer KS, Zwart P, Kroeze EJ: Effects of allopurinol on plasma uric acid levels in normouricaemic and hyperuricaemic green iguanas (*Iguana iguana*). *Vet Rec* 162(4):112-115, 2008.
32. Divers SJ: Reptile Urology. *Proceedings of 3rd International Conference on Avian, herpetological and Exotic mammal medicine (ICARE)*, Venice, March 25th-29th 2017, pp 125-142, 2017.
33. Zanon G, Combi F, Combi A, Perticarini L, Sammarchi L, Benazzo F: Platelet-rich plasma in the treatment of acute hamstring injuries in professional football players. *Joints* 4(1):17-23, 2016.
34. Navani AH: Platelet Rich Plasma in Musculoskeletal Pathology: A Necessary Rescue or a Lost Cause? *Pain Physician*. 20(3):345-356, 2017.
35. Scully D, Naseem KM, Matsakas A: Platelet Biology in Regenerative Medicine of Skeletal Muscle. *Acta Physiol* doi: 10.1111/apha.13071, 2018
36. Bielecki T, Dohan Ehrenfest DM, Everts PA, Wiczowski A: The Role of Leukocytes from L-PRP/L-PRF in Wound Healing and Immune Defense: New Perspectives. *Curr Pharm Biotechnol* 13:1153-1162, 2012.
37. Crain DA, Gross TS, Cox MC, Guillette LJ: Insuline-like growth factor-I in plasma of two reptiles: assay development and validation. *Gen Comp Endocrinol* 98:26-34, 1995.
38. Duncan CA, Jetzt AE, Cohick WS, John-Alder HB: Nutritional modulation of IGF-1 in relation to growth and body condition in *Sceloporus* lizards. *Gen Comp Endocrinol* 216:116-124, 2015.
39. Sparkman AM, Byars D, Ford NB, Bronikowski AM: The role of insulin-like growth factor-1 (IGF-1) in growth and reproduction in female brown house snakes (*Lamprophis fuliginosus*). *Gen Comp Endocrinol* 168:408-414, 2010.

40. Zhu X, Zhang S, Zhao S, Zhang R, Zhou Y, Wu X. Insulin-like growth factor I (IGF-I) in Chinese alligator, *Alligator sinensis*: Molecular characterization, tissue distribution and mRNA expression changes during the active and hibernating periods. *Gen Comp Endocrinol* 242: 74-82, 2017.
41. Tsai S, Abdelhamid A, Khan MK, Elkarargy A, Widelitz RB, Choung CM, Wu P: The Molecular Circuit Regulating Tooth Development in Crocodylians. *J Dent Res* 95(13):1501-1510, 2016.
42. Li HL, Chen LP, Hu YH, Qin Y, Liang G, Xiong YX, Chen QX: Crocodile Oil Enhances Cutaneous Burn Wound Healing and Reduces Scar Formation in Rats. *Acad Emerg Med* 19(3):265-73, 2012.
43. Zhang Z, Chen B, Youan L, Niu C: Acute cold stress improved the transcription of pro-inflammatory cytokines of Chinese soft-shelled turtle against *Aeromonas hydrophila*. *Dev Comp Immunol* 49:127137, 2015.
44. Liu Y, Fan Z, Zhou Y, Liu M, Ding F, Gu X: The Molecular Cloning of Platelet-Derived Growth Factor-C (PDGF-C) Gene of *Gekko japonicus* and Its Expression Change in the Spinal Cord After Tail Amputation. *Cell Mol Neurobiol* 29:263–271, 2009.
45. Peacock HM, Gilbert EAB, Vickaryous MK: Scar-free cutaneous wound healing in the leopard gecko, *Eublepharis macularius*. *J Anat* 227:596-610, 2015.
46. Payne SL, Peacock HM, Vickaryous MK: Blood Vessel Formation During Tail Regeneration in the Leopard Gecko (*Eublepharis macularius*): The Blastema Is Not Avascular. *J Morphol* 278:380-389, 2017.
47. Intini G: The use of platelet-rich plasma in bone reconstruction therapy. *Biomaterials* 30(28):49564966, 2009.
48. Shafieian R, Matin MM, Rahpeyma A, Fazel A, Sedigh HS, Sadr-Nabavi A, Hassanzadeh H, Ebrahimzadeh-Bideskan A: The effect of platelet-rich plasma on human mesenchymal stem cell-induced bone regeneration of canine alveolar defects with calcium phosphate-based scaffolds. *Iran J Basic Med Sci* 20(10):1131-1140, 2017.
49. Yuan T, Zhang C, Zeng B: Treatment of chronic femoral osteomyelitis with platelet-rich plasma (PRP): A case report. *Transfus Apher Sci* 38(2):167-173, 2008.
50. Jia WT, Zhang CQ, Wang JQ, Feng Y, Ai ZS: The prophylactic effects of platelet-leucocyte gel in osteomyelitis: an experimental study in a rabbit model. *J Bone Joint Surg Br* 92(2):304-310, 2010.
51. Drago L, Bortolin M, Vassena C, Romanò CL, Taschieri S, Del Fabbro M: Plasma components and platelet activation are essential for the antimicrobial properties of autologous Platelet-Rich Plasma: an *in vitro* study. *PLoS One* 9(9): 2-6. doi:10.1371/journal.pone.0107813, 2014.
52. Prabhu R, Vijayakumar C, Bosco CA, Balagurunathan K, Kalaiarasi R, Venkatesan K, Erabati SR, Swetha T: Efficacy of Homologous, Platelet-rich Plasma Dressing in Chronic Non-healing Ulcers: An Observational Study. *Cureus* 10(2): e2145. doi: 10.7759/cureus.2145, 2018

First isolation of *Trichophyton erinacei* from a European hedgehog (*Erinaceus europaeus*) in Italy

Rosita Semenza Esposito, Med Vet^{1,2,3}, Gabriele Meroni PhD⁴, Emanuele Lubian Med^{2,3,5}, Piera Anna Martino DBS PhD⁶

¹Ambulatorio veterinario dottori Ferlini e Millefanti via Galvani 42 Gaggiano.

²MypetClinic via Daniele Ranzoni 10, Milano.

³CRFS LIPU “La Fagiana” di Pontevecchio di Magenta.

⁴Dipartimento di Scienze Biomediche per la Salute, Università degli Studi di Milano.

⁵Università degli Studi di Messina.

⁶ Dipartimento di Medicina Veterinaria, Università degli Studi di Milano.

* Corresponding Author (rosita.esposito91@gmail.com)

Received: 27/04/2020 - Accepted: 12/10/2020

INTRODUCTION

Diseases similar to human ringworm infection may be detected in both domestic and wild mammals and in most cases these are considered to have a zoonotic potential. Among wild animals, the European hedgehog (*Erinaceus europaeus*) can play an important role as a potential reservoir of infection (Fig. 1).

T. erinacei is a zoophilous dermatophyte commonly isolated from hedgehogs (considered natural reservoirs) and is mainly widespread in New Zealand and Europe.¹ While previously taxonomically classified as *T. mentagrophytes* var. *erinacei*, recent phylogenetic studies have reclassified it as a new species of the genus *Trichophyton*.^{2,3} Macroscopically, colonies plated on Sabouraud Dextrose Agar (SDA) exhibit rapid growth, are whitish, flat and have a powdery (sometimes downy) appearance.³ At microscopy, the pathogen's morphology is characterised by the occasional presence of macroconidia and by numerous clavate microconidia on the sides of the hyphae (Figs. 2-3-4).

New Zealand researchers Smith and Marples were the first to talk about *Trichophyton mentagrophytes* var. *erinacei* in a study published in 1964 and aimed at finding dermatophytes in European hedgehogs. Of the 114 subjects studied, 44.7% were carriers of *T. mentagrophytes* var. *erinacei*; in addition, the microscopic examination of skin scrapings of 40 animals allowed the detection of *Caparinia tripilis* (a common mite of *Erinaceus europaeus* and considered a possible vector of the fungus).

In the wild, the incidence of dermatophytosis (ringworm) in European hedgehogs has been assessed in various studies conducted in different countries: in New Zealand it is 44.7%, in France 9.5% while in Great Britain

the percentage varies from 1.35% to 20-25%. An additional French study, conducted by Audonneau, reports an incidence of infection in European hedgehogs in the wild and in captive animals of 13% and 21%, respectively.⁵ These results are in contrast with a 2012 study conducted in Spain (Catalonia) by Molina-López (2012): none of the 91 subjects included in the study presented signs of dermatophytosis and neither *T. erinacei* nor, more generally, dermatophytes were isolated in any of them. In this study, the genera most commonly found were *Cladosporium* (79.1%), *Penicillium* (74.7%), *Alternaria* (64.8%) and *Rhizopus* (63.7%); these saprophytic species are frequently found in the environment (in soil or plants) and their presence can be considered as an indicator of transitory contamination of the skin and of its adnexa. According to the authors of the study, the high prevalence of contaminants may have interfered with the growth of other pathogen species such as dermatophytes. The absence of *T. mentagrophytes* was attributed to the immediate sampling of the animals upon arrival at the rescue centre; in view of this, the hedgehogs wouldn't have had the time to develop immunodepression from the stress associated with capture and, consequently, to develop subclinical infections.⁶ The failure in isolating *T. erinacei* is also in agreement with a study carried out at the University of Pisa, in which mycological investigations on 44 hedgehogs (both alive and in corpses found on the sides of roads)⁷ did not allow the isolation of the dermatophyte in question.

MATERIALS AND METHODS

Sampling

The sampling took place in the months between September 2017 and June 2018 at the CRFS LIPU (Wildlife Rescue Centre) of Pontevecchio di Magenta (MI), Italy.

Of the 30 hedgehogs sampled, 5 (which were in extremely critical conditions) came from Veterinary Clinics that provided initial treatment before transfer to the CRFS, in accordance with the current law in force in the Lombardy Region concerning the care of wild animals (L. 157/92); one hedgehog was sampled in a private garden. Subjects that arrived dead or had been dead for more than 24 hours were excluded from the study.

At the time of admission at the CRFS identification and relevant data were collected for each hedgehog, such as the CRFS code, weight, sex, date and place of retrieval, date of admission and sampling, cause of admission, any treatments performed and eventual success at reintroduction.

The animals were also divided into three categories according to their body weight: suckling hoglets (up to 150g), young animals (up to 400g) and adults (over 400g). To perform the skin swabs on the back of the animals after having worn appropriate personal protective equipment the tip of the swab was passed between the spines until reaching the skin and then rotated for a few seconds.

Each swab was then marked with the date of collection and the identification code (Figure 5).

After collection, the samples were kept in a refrigerator until delivery, within 48 hours, to the Laboratory of Bacteriology of the Department of Veterinary Medicine (DiMEVET) of the University of Milan, where they were subsequently analysed.

Fungal isolation and identification

The samples were plated on Sabouraud Dextrose Agar and the plates incubated at 25 °C in aerobiosis for 5 days. For the identification and differentiation of the fungal species a macroscopic evaluation of the front and back of the plates was performed, assisted by microscopic analysis using lactophenol cotton blue staining, which revealed hyphae, conidiophores, macroaleuriospores (macronidia) and microaleuriospores (micronidia).

The final identification of the species was made by means of a molecular method. Two pairs of species-specific primers for *T. erinacei* (strain CBS 511.73) were designed to amplify the ITS1 and ITS2 sequences (accession number in GenBank: EF078476 and EF078481, respectively). The primers were constructed with Primer-BLAST (<https://www.ncbi.nlm.nih.gov/tools/primerblast/index.cgi>) and synthesised by Eurofins Genomics (Germany). The amplification reaction was performed using the oligonucleotides ITS1-Fw (5'-CATCAGGGT-GCAGATGT-3') and ITS1-Rv (5'TGCTTGC-TAACGCTCAGACT-3') for the amplification of ITS1, while ITS2-Fw (5'CCGGCTTGTGATGGACG-3') and ITS2-Rv (5'AGAGAGATTTGGGAAGGC3') for the amplification of ITS2. The expected size of the two fragments was 192 and 157 base pairs, respectively. Amplification products were analysed by agarose gel electrophoresis (2% w/v), stained with Atlas ClearSight DNA Stain (Bioatlas, Tartu, Estonia) in TBE buffer (Tris-Borate-EDTA) 1X solution. A 100 bp ladder (ThermoFisher, Italy) was used as a weight marker to verify that the amplification products were of the expected size. After purification of the amplicons with the Wizard® SV Gel and PCR Clean-Up System extraction kit (Promega, Italy), these were sequenced (Macrogen Europe B.V., Amsterdam, the Netherlands). Species identification was performed by comparing the sequences obtained with the reference sequences (LN614531.1, IFM 51378) available in the GenBank database, using the BLAST algorithm (<https://blast.ncbi.nlm.nih.gov/BLAST>) and the online mycological identification tool (<http://its.mycology-lab.org/>).

Analysis of the skin bacterial flora (data not included in this study) was also performed in parallel with the search of the fungal flora.

RESULTS AND DISCUSSION

In the study, the fungi that were more commonly isolated belonged to saprophytic species frequently found in the environment (e.g. *Alternaria* spp. and *Mucor* spp.). *Trichophyton erinacei* was isolated from only one subject, which also had a methicillin-resistant strain of *Staphylococcus aureus* (MRSA). This was a healthy male adult hedgehog from a private garden in Vigevano (PV), which was brought to the CRFS as it was considered at risk because of the presence of the owner's dog. At physical examination, no signs of mycosis were detected but the presence of ectoparasites (ticks) was reported.

CONCLUSIONS

The risk of human *T. erinacei* infection is quite rare and is secondary to direct contact with hedgehogs. Other possible sources of infection are soil (spores can survive up to a year in hedgehog nests), infected persons and dogs that have come in contact with wild hedgehogs.^{8,1,3}

In the literature, only a few cases of tinea corporis, tinea capitis, tinea manuum and tinea faciei caused by *T. erinacei* have been reported, and all were due to direct contact with infected hedgehogs. The number of cases increases especially among owners of domestic hedgehogs (in particular for those belonging to the species *Atelerix albiventris*). Among these, one case involved a 21-year-old Chilean patient who presented a pruritic squamous erythema on her nose two months after being bitten by her African hedgehog, which had never shown signs of skin lesions and/or loss of spines.⁹ Similarly, another case reported in Korea involved a 15-year-old girl who presented with pustules and squamous erythema on the fingers of her left hand. Also, in this case there had been direct contact with her own pet African hedgehog, which - although showing a slight scaling of the skin - had no visible signs of alopecia or loss of spines.¹⁰ Only in one case, a 26-year-old woman returning from a holiday in Thailand, the reported cause of infection was contact with an elephant she had ridden while visiting a national park. The woman denied contact with other animals, particularly hedgehogs, and denied owning pets (including dogs, which can develop this type of infection and are a potential source of infection for their owners).¹¹

The recent popularity of the African hedgehog (*Atelerix albiventris*) as a domestic pet has led many authors to investigate the zoonotic risk of this species, with a particular focus on dermatophytosis. In a study conducted in Spain, by Abarca (2016), 20 domestic hedgehogs (19 *Atelerix albiventris* and 1 *Hemiechinus auritus*) with skin lesions attributable to dermatophytosis were examined. The authors found a 50% prevalence of *T. erinacei*. A similar study was conducted by D'Ovidio (2015) in Southern Italy. The examination of unconventional species (rabbits, rats, chinchillas, ferrets and African hedgehogs) showed a high prevalence of *T. mentagrophytes* (53.1%), but in no hedgehog was *T. erinacei* found.^{12,5}

The zoonotic risk also extends to domestic animals, especially hunting dogs, which more frequently come into direct and indirect contact with wildlife. In these subjects, *T. erinacei* causes suppurative inflammation with squamous, focal or multifocal, roundish and alopecic skin lesions.¹³

The isolation of this zoonotic agent in the study represents the first reported detection in European hedgehogs in Italy; based on the review of the available literature no previous studies have reported the presence of this fungus in *E. europaeus* so the prevalence of the dermatophyte is consequently rather low (3.33%).

In any case, given the diffusion, especially in recent years, of the African hedgehog (*Atelerix albiventris*) as a pet, it would be interesting to expand the search for *T. erinacei* also in this species as based on the analysis of the existing literature this species appears to be more predisposed to developing dermatophytosis.^{14,5} In this regard, studies carried out in Kenya and in the Ivory Coast on autochthonous specimens of *Atelerix albiventris* reported positivity rates of 22.2% and 37.5%, respectively.⁵ In addition, the possible relationship between the dermatophyte and the presence of ectoparasites (particularly mites) should also be assessed. As reported by

Smith and Marples, ectoparasites could play a decisive role in the transmission and spread of *T. erinacei* among the various subjects.⁴

ACKNOWLEDGEMENTS

Sincere thanks to the CRFS LIPU «La Fagiana» of Pontevecchio di Magenta for their availability and cooperation in the collection of the samples.

Prima segnalazione di isolamento di *Trichophyton erinacei* in un riccio europeo (*Erinaceus europaeus*) in Italia

SUMMARY

Introduzione: *Trichophyton erinacei* è un dermatofita zoonosico agente eziologico di dermatofitosi negli animali e nell'uomo. Il riccio europeo (*Erinaceus europaeus*) è considerato un'importante fonte di infezione per l'uomo e per gli animali domestici, in particolare per i cani da caccia che più frequentemente possono venire a diretto contatto. Sebbene la letteratura riporti questo dermatofita nel riccio europeo con una prevalenza del 25-50%, ad oggi in Italia non è stato segnalato nessun isolamento. Questo studio si propone di valutare la flora microbica cutanea di 30 ricci europei campionati presso il CRFS LIPU di Pontevecchio di Magenta (MI).

Materiali e metodi: I tamponi cutanei sono stati seminati entro 24-48 ore su Sabouraud Dextrose Agar per la ricerca di miceti, e su agar-sangue per la ricerca di batteri (dati non riportati).

Risultati: *Trichophyton erinacei* è stato isolato da un solo riccio, che non presentava un quadro clinico riconducibile a micosi. Discussione: Considerando che il riccio è un animale sinantropo, questo segnalamento conferma il ruolo di portatore sano del riccio, sottolineando il rischio di infezione per l'uomo e per gli animali domestici.

BIBLIOGRAFIA

1. Mary P. English, P. Morris. *Trichophyton mentagrophytes* var. *erinacei* in hedge- hog nests. *Sabouraudia* 7(2):118-21, 1969.
2. Y. Gräser, A.F.A. Kuijpers, W. Presber et al. Molecular taxonomy of *Trichophyton mentagrophytes* and *T. tonsurans*. *Medical Mycology* 37, 315-330, 1999.
3. R. A. Quaife. Human infection due to the hedgehog fungus, *Trichophyton mentagrophytes* var. *erinacei*. *Journal of Clinical Pathology* 19, 177, 1966.
4. Smith J.M.B., Marples M.J. *Trichophyton mentagrophytes* var. *erinacei*. *Sabouraudia* 3 (1), 1-8, 1964.
5. Abarca M.L., Castella´ G., Martorell J. et al. *Trichophyton erinacei* in pet hedge- hogs in Spain: Occurrence and revision of its taxonomic status. *International Society for Human and Animal Mycology* 55 (2), 164-172, 2016.
6. Molina-López R.A., Adelantado C., Arosemena E.L. et al. Integument Mycobiota of Wild European Hedgehogs (*Erinaceus europaeus*) from Catalonia, Spain. *ISRN Microbiology* 1-6, 2012.

7. Pallesi R. "Isolamento e tipizzazione di miceti cheratinofili da cani da seguito e da specie selvatiche cacciate". Tesi di laurea in Medicina Veterinaria, Dipartimento di Scienze Veterinarie. Università di Pisa, 2014.
8. Drira, S. Neji, I. Hadrich et al. Tinea manum due to *Trichophyton erinacei* from Tunisia. *Journal de Mycologie Médicale* 25, 200-203, 2015.
9. Concha M., Nicklas C., Balcells E. et al. The first case of tinea faciei caused by *Trichophyton mentagrophytes* var. *erinacei* isolated in Chile. *International Journal of Dermatology* 51 (3), 283-285, 2012.
10. Rhee D.Y., Kim M.S., Chang S.E. et. al. A case of tinea manum caused by *Trichophyton mentagrophytes* var. *erinacei*: the first isolation in Korea. *Mycoses*, 52 (3), 287-290, 2009.
11. Borges-Costa J., Martins M.L. *Trichophyton erinacei* skin infection after recreational exposure to an elephant in Southeast Asia. *Pathogens and Global Health* 108 (1), 58-59, 2014.
12. D. d'Ovidio, D. Santoro. Survey of Zoonotic Dermatoses in Client- Owned Exotic Pet Mammals in Southern Italy. *Zoonoses and Public Health* 62, 100-104, 2015.
13. Kurtdede A., Haydardedeoglu A.E., Alihosseini H. et al. Dermatophytosis caused by *Trichophyton mentagrophytes* var. *erinacei* in a dog: a case report. *Veterinari Medicina* 59 (7), 349-351, 2014.
14. Christian Kromer, Pietro Nenoff, Silke Uhrlaß et al. *Trichophyton erinacei* transmitted to a Pregnant Woman From Her Pet Hedgehogs. *JAMA Dermatology* 154(8), 967-968, 2018.

Molecular Survey on *Toxoplasma gondii* and *Neospora caninum* Infection in Wild Birds of Prey Admitted to Recovery Centers in Northern Italy

Alessia Libera Gazzonis¹, Luca Villa¹, Emanuele Lubian^{1,2}, Sara Ressegotti¹, Guido Grilli¹, Stefano Raimondi³, Sergio Aurelio Zanzani¹ and Maria Teresa Manfredi¹

1 Department of Veterinary Medicine, Università degli Studi di Milano, 26900 Lodi, Italy; luca.villa@unimi.it (L.V.); emanuele.lubian@hotmail.com (E.L.); sara.ressegotti@studenti.unimi.it (S.R.); guido.grilli@unimi.it (G.G.); sergio.zanzani@unimi.it (S.A.Z.); mariateresa.manfredi@unimi.it (M.T.M.)

2 CRFS LIPU “La Fagiana”, 20013 Pontevecchio di Magenta, Italy

3 Associazione CRAS di Vanzago, 20010 Vanzago, Italy; boscovanzago@wwf.it

* Correspondence: alessia.gazzonis@unimi.it; Tel.: +39-02-503-34139

Abstract: *Toxoplasma gondii* and *Neospora caninum* (Apicomplexa, Sarcocystidae) are protozoan parasites infecting a wide range of intermediate hosts worldwide, including birds. Raptors acquire the infections through the ingestion of both infected preys and oocysts in the environment suggesting they might be used as indicators of the spread of these pathogens. Here, we report an epidemiological survey with the aim of determining the prevalence of *T. gondii* and *N. caninum* infections in wild birds of prey, hospitalized in two Wildlife Recovery Centres (WRCs) in Northern Italy. Genomic DNA extracted from brain tissue samples was submitted to Real Time PCR targeting *T. gondii* B1 and *N. caninum* Nc5 genes. *T. gondii* genotyping was then performed by multilocus sequence typing (MLST) analysis, targeting three polymorphic genes (GRA6, BTUB, and altSAG2). *T. gondii* DNA was found in 35 (62.5%) out of 56 examined samples; concerning genotyping, it was possible to amplify at least one gene for 26 animals, and obtained sequences belonged to Type II. *N. caninum* DNA was only detected in two (3.6%) common kestrels (*Falco tinnunculus*), adding a new species to the list of suitable intermediate hosts for this pathogen. Data obtained in the present study thus confirmed the spread of both *T. gondii* and *N. caninum* in wild bird of prey, endorsing the role of WRCs in the epidemiological surveillance of wildlife.

Citation: Gazzonis, A.L.; Villa, L.; Lubian, E.; Ressegotti, S.; Grilli, G.; Raimondi, S.; Zanzani, S.A.; Manfredi,

M.T. Molecular Survey on *Toxoplasma gondii* and *Neospora caninum* Infection in Wild Birds of Prey Admitted to Recovery Centers in Northern Italy.

Microorganisms **2021**, *9*, 736. <https://doi.org/10.3390/microorganisms9040736>

Academic Editor: Paolo Calistri Received: 10 February 2021

Accepted: 29 March 2021

Published: 1 April 2021

Keywords: protozoa; genotype; toxoplasmosis; neosporosis; raptor; Wildlife Recovery Centre

1. Introduction

Toxoplasma gondii and *Neospora caninum* are two closely-related parasites belonging to the family Sarcocystidae (Apicomplexa). They have a worldwide distribution and are considered to be major abortigenic pathogens of domestic ruminants. *T. gondii*, which has the cat as a definite host, is able to infect a wide range

of mammals and birds as intermediate hosts. *N. caninum*, although capable of infecting numerous species of mammals and birds, has bovine as its main intermediate host. Definitive hosts, such as dogs and wild canids, can become infected by ingesting the placentas or fetal cravings of infected intermediate hosts [1,2].

For both parasites, a sylvatic cycle is described as interfacing with the domestic cycle, which is often considered to be the primary cause of infection in livestock farms [3]. In fact, both pathogens were demonstrated by serological, histological, or molecular studies in several wildlife species comprising birds, as recently reviewed [4,5]. Among the avian species, birds of prey are of particular interest because, acquiring the infections mainly through the ingestion of infected preys (other birds, or small mammals), they can be used as sentinel species of environmental contamination with these parasites [4].

In raptors, various seroepidemiological and molecular studies reported *T. gondii* infection with different prevalence values, depending on the host species, the geographical area of origin, and the diagnostic technique used [6–10]. Raptors are considered resistant to clinical infection. However, clinical toxoplasmosis was described in a Canadian barred owl (*Strix varia*) that died following a collision with a car, in which severe hepatitis was found at autopsy [11]. Clinical toxoplasmosis was also observed in a bald eagle (*Haliaeetus leucocephalus*) found in a situation of distress and weakness that died of severe myocarditis [12]. Recently, another case of acute fatal toxoplasmosis was described in a juvenile bald eagle with concomitant severe emaciation and poxviral dermatitis [13].

N. caninum infection was reported in birds [5]; particularly, considering raptors, *N. caninum* DNA so far was detected, to the best of our knowledge, only in the brain tissue of a naturally infected common buzzard in Spain [9].

Investigating the prevalence of *T. gondii* and *N. caninum* in wildlife is necessary to understand the life cycle of the parasite, the dynamics of transmission, and the risk to public health [14]. Therefore, a molecular epidemiological survey was planned with the aim of determining the prevalence of *T. gondii* and *N. caninum* infections in wild birds of prey admitted to the Wildlife Recovery Centers (WRCs) located in the Lombardy region (Northern Italy). The study area is of particular interest as it is highly populated; there are also numerous farms dedicated to the breeding of both cattle and small ruminants. The sampled birds of prey, living in an area under such strong human and zootechnical pressure, are therefore perfectly placed at the interface between the domestic and sylvatic cycle of both *T. gondii* and *N. caninum*.

2. Materials and Methods

2.1. Study Population and Sample Collection

Sampling was performed between April 2018 and February 2019 in two WRCs in the Lombardy region (Northern Italy). WCR1 is located within the WWF (World Wildlife Fund) Natural Oasis of Vanzago (45°31'14.16'' N 8°58'29.74'' E) about 20 km from the metropolitan city of Milan. The number of animals hospitalized is constantly increasing, with about 500 raptors hospitalized in 2018. The LIPU (Lega Italiana Protezione Uccelli) “La Fagiana” WCR2 is located in the “La Fagiana” nature reserve of the Ticino Park (Pontevicchio di Magenta, Milan); although the number of hospitalizations per year is lower than that of WCR1 (about 300 birds of prey in 2018), Ticino Park represents an ideal environment for the release of rehabilitated specimens (45°26'13.2'' N 8°50'18.6'' E).

A total of 56 birds of prey (29 animals from WCR1 and 27 from WCR2), hospitalized and then died or euthanized, were recruited for the study. All animals included in the study died (by euthanasia or natural death) within the first days of hospitalization. During this period, the animals were kept in boxes inside the WRC infirmary, where access to other birds was not possible. Furthermore, all hospitalized raptors were fed defrosted food (chicks or mice), potentially containing non-infectious parasitic cysts. The short-stay time, the impossibility of access for prey animals, and the defrost diet thus ensured that the animals included in the study did not acquire *T. gondii* or *N. caninum* infection during their stay at the WRC. Brain samples were collected at the laboratories of the Department

of Veterinary Medicine, Università degli Studi di Milano, during necropsy of wild birds performed within the West Nile Virus and the avian influenza virus epidemiological

surveillance system conducted by the Local Health Authority. The brain was extracted after opening the skull; an aliquot of tissue (about 0.5–1 gr) was taken for the present study, mechanically homogenized with a sterile spatula, and placed in a single tube marked with a progressive identification number. Samples were stored at 20 °C until analysis.

Eleven species belonging to the Families Accipitridae (5), Falconidae (3), and Strigidae (3) were represented. All species included in the study are listed on the IUCN Red List of Threatened Species as “least concern” (<https://www.iucnredlist.org/>, accessed on 7 December 2019); only black kite (*Milvus migrans*) is listed as “near threatened” in the Italian Red List (<http://www.iucn.it/liste-rosse-italiane.php>, accessed on 10 February 2021).

Individual data concerning age was recorded or estimated on the basis of the size, weight, and plumage features, according to the species, classifying the animals as young or adult [15,16]. The reason for admission to the WRCs was also recorded. For each species, the dietary habits (mainly mammals, mainly birds, or generalist species) and the main migratory behavior (migrant or sedentary species) were registered [15,16].

2.3 Molecular Analysis

Tissue samples were processed for DNA extraction using a commercial kit (Nucleospin tissue, Macherey-Nagel GmbH and Co. KG, Düren, Germany), following manufacturer’s instruction. Extracted DNA was stored at 20 °C until analyzed.

For the detection of *T. gondii* DNA, samples were subjected to a real-time PCR (B1 real-time PCR), targeting a region of about 129 bp within the 35-fold repetitive B1 gene (AF179871) [17], as described by Gazzonis et al. [18], with slight modifications. For the detection of *N. caninum* DNA, a real-time PCR (Nc5 real-time PCR) targeting the Nc5 region was performed [19].

Both real-time PCRs were performed in a final volume of 20 µL, containing the PowerUp™ SYBR® Green Master Mix (Thermo Fisher Scientific, Life Technologies, Monza, Italy) 2 , 0.5 µM of each primer [ToxB41f (5j-TCGAAGCTGAGATGCTCAAAGTC-3j) and ToxB169r (5j-AATCCACGTCTGGGAAGAACTC-3j) for *T. gondii*, NeoF (5j-ACTGGAGGCA CGCTGAACAC-3j), and NeoR (5j- AACAATGCTTCGCAAGAGGAA-3j) for *N. caninum*],

and 5 µL of DNA samples (approximately 250–500 ng of genomic DNA). Amplification and melting analysis were performed in a QuantStudio™ 3 Real-Time PCR System with a QuantStudio™ 3 software system (Applied Biosystems™ LSA28137), with the following cycling profile: incubation at 50 °C for 2 min, denaturation at 95 °C for 2 min, amplification for 40 cycles at 95 °C for 15 s, and 60 °C for 60 s, and a final step of melting analysis. Positive and negative controls (no template DNA) were included in each run; positive controls consisted of genomic DNA of *T. gondii* and *N. caninum*, previously amplified and identified by sequencing, extracted from the tissue samples of a coypu (lungs) [20] and a bovine fetus (pooled organs) [21], respectively. The melting program, consisting of temperature increases from 60 °C to 95 °C at intervals of 0.15 °C/s, was performed at the end of each cycle. Each sample was analyzed in duplicates, and the mean cycle threshold (Ct) and melting temperature (Tm) values were recorded. A sample was defined as positive when there was (i) a detectable amplification curve, (ii) a Ct value below 35, and (iii) a Tm value of 0.5 °C vs. Tm value of positive control was recorded.

For *T. gondii* genotyping purposes, samples scoring positive to B1 real-time PCR were submitted to Multilocus sequence typing (MLST) analysis, targeting selected polymorphic genes (GRA6, BTUB, and altSAG2), following the nested PCR protocol described [22], with slight modifications. Unlike the described protocol, providing a multilocus PCR, the selected markers were each amplified in a different reaction to maximize the sensitivity. Each sample was analyzed in triplicate, using the thermic protocol described. Concerning the external reactions, mixtures contained 1 DreamTaq Green buffer (ThermoScientific, Life Technologies, Monza, Italy), 200 µM of each dNTP, 0.15 µM of each primer, 1U of DreamTaq Green DNA polymerase (ThermoScientific, Life Technologies, Monza, Italy), and 4 µL of DNA samples (approximately 250–500 ng of genomic DNA) in a final volume of 20 µL. The mixture of nested reactions contained 1 DreamTaq Green buffer (ThermoScientific, Life Technologies, Monza, Italy), 200 µM of each dNTP, 0.3 µM of each primer,

1U of DreamTaq Green DNA polymerase (ThermoScientific, Life Technologies, Monza, Italy), and 1 μ L of PCR products, in a final volume of 20 μ L. PCR products were run on 1.5% agarose gel containing 0.05% ethidium bromide in TBE buffer electrophoresis; bands were visualized under UV light on a transilluminator. Bands of expected size were excised from agarose gel, purified with a commercial kit (NucleoSpin® Gel and PCR Clean-up kit, Macherey- Nagel GmbH and Co. KG, Düren, Germany), and sent for bidirectional sequencing to a commercial service (Eurofins MWG Operon, Ebersberg, Germany). Electropherograms were checked, and consensus sequences were manually assembled.

Sequences were compared to nucleotide sequences available in the GenBank using BLASTn (<https://blast.ncbi.nlm.nih.gov/>, accessed on 6 October 2020) and then aligned with sequences available in GenBank using the Mega6 software [23]. The sequences of the GRA6 locus were aligned with Type I—RH (JN649063.1), Type II—ME49(AF239285.1), and Type III—NED, CTG, C56 (AF239286.1, JX044207.1, DQ512729.1). The sequences of the BTUB locus were aligned with Type I—RH and GT1 (JX045508.1, JX045509.1), Type II—Beverly (AF249702.1), and Type III—CTG and C56 (JX045537.1, AF249703.1). The sequences of the altSAG2 locus were aligned with Type I—RH (JX045478.1), Type II— Beverly (AF249697.1), and Type III C56 and NED (AF249698.1, AF357579.1).

In addition, Nc5 real-time PCR positive amplicons were purified and sequenced, as described above. Obtained sequences, once cleaned up, were compared with the homologous nucleotide sequences available in GenBank databases, using the BLASTn for identity confirmation.

2.2. Statistical Analysis

The prevalence of *T. gondii* and *N. caninum* infection in the different species and taxonomic families of birds of prey included in the study and for the considered variables (age, WRC, reason for admission to the WRC, dietary habits, main migratory behavior) was calculated [24]. Chi-square test was used to verify the possible association between *T. gondii* infection and the following variables: taxonomic family; age (young, adult); WRC; reason for admission to the WRC (debilitation, trauma, other causes); dietary habits (mainly mammals, mainly birds, generalist species); and main migratory behavior (migratory, sedentary). The level of significance for independent variables was set to 0.05. Statistical analysis was performed by SPSS (version 19.0; SPSS, Chicago, IL, USA).

3. Results

T. gondii DNA was found in thirty-five (62.5%) samples examined by B1 real-time PCR. Positive control showed Ct and Tm values of 20.314 and 77.973, respectively; Ct and Tm values of positive samples ranged from 26.199 to 34.039, and from 77.795 to 78.480, respectively.

With regards to *N. caninum*, parasitic DNA was found in the brain of two birds (3.6%), out of the 56 examined. Positive control showed Ct and Tm values of 27.720 and 78.749, respectively. Positive samples showed Ct values of 32.736 and 34.180, and Tm values of

78.597 and 79.211. Sequencing of Nc5 real-time PCR amplicons produced two identical 76 bp sequences. BLASTn analysis confirmed *N. caninum* identity, showing that the obtained sequences had a 99–100% homology with *N. caninum* sequences deposited in GenBank (FJ464412, X84238).

The genotype determination was subsequently carried out by MLST analysis on the 35 samples that tested positive at the *T. gondii* B1 real-time PCR, by amplifying and sequencing regions of three target genes (GRA6, BTUB, and altSAG2). The amplification was possible only for part of the samples. In particular, for nine animals, it was not possible to obtain amplification for any target genes. Concerning the GRA6 gene, amplicons were obtained for eighteen raptors; high quality sequences were produced for only five samples. Further, only five samples were amplified at the BTUB target region, and four were successfully sequenced. The GRA6 and BTUB sequence alignment of the samples showed complete (100%) sequence homology with the clonal type II reference sequence included (Beverly for GRA6, and ME49 for BTUB) (Supplementary Tables S1 and S2). For both genes, any intraspecific nucleotide variation was not detected between the sequences examined (100% identity). Finally, concerning altSAG2 gene, 13 amplicons were obtained; all but

one sample was successfully sequenced and the alignment of the sequences showed a homology with type II (ME49), but two single-nucleotide polymorphisms (SNPs) were identified. In all obtained sequences, double peaks (A/G) were detected at position 39 and 162 (Supplementary Table S3). The obtained sequence was submitted to the GenBank database under accession number MW590807.

The prevalence values of *T. gondii* and *N. caninum* were then calculated according to the considered individual and species-specific variables. Concerning *T. gondii*, the taxonomic family of Strigidae showed the highest prevalence of infection (68.8%), compared to Falconidae (63.2%) and Accipitridae (57.1%). Parasitic DNA was detected in both young (7/12, 58.3%) and adult animals (28/44, 63.6%). Positive raptors were hospitalized in both WRC1 and WRC2 (51.7% and 74.1%, respectively, out of the examined animals). The reasons for the admission to the WRC were then considered: *T. gondii* DNA was more frequently found in animals admitted for debilitation (4/5, 80%) than in those hospitalized for trauma (25/41, 61%) or for other causes (6/10, 60%). Finally, the dietary habits and the main migratory behavior were considered for each species included in the study. Raptor species that feed mainly on mammals were more frequently positive in *T. gondii* B1 real-time PCR (25/36, 69.4%) than those that feed mainly on birds (5/11, 45.4%) or compared to generalist species (5/9, 55.6%). Sedentary species showed higher prevalence of *T. gondii* infection than migratory species (25/37, 67.6%, and 19/19, 52.6%, respectively). Table 1 shows the biological characteristics considered (dietary habits and main migratory behavior) for each species included in the sampling, and the corresponding positivity values to B1 real-time PCR.

Table 1. List of the species of raptors included in the sampling. The dietary habits and migratory behavior, and the corresponding positivity values to *Toxoplasma gondii* B1 real-time PCR is given for each species.

Family	Common Name (Species)	<i>T. gondii</i> B1 Real-Time PCR Positive/Examined (%)	Dietary Habits	Main Migratory Behavior
Accipitridae	northern goshawk (<i>Accipiter gentilis</i>)	0/1 (0%)	mainly birds	sedentary
	Eurasian sparrowhawk (<i>Accipiter nisus</i>)	3/7 (42.9%)	mainly birds	sedentary
	Eurasian buzzard (<i>Buteo buteo</i>)	9/10 (90%)	mainly mammals	sedentary
	black kite (<i>Milvus migrans</i>)	0/2 (0%)	generalist species	migratory
	European honey buzzard (<i>Pernis apivorus</i>)	0/1 (0%)	generalist species	migratory
		12/21 (57.1%)		
Falconidae	peregrine falcon (<i>Falco peregrinus</i>)	1/1 (100%)	mainly birds	sedentary
	Eurasian hobby (<i>Falco subbuteo</i>)	1/2 (50%)	mainly birds	migratory
	common kestrel (<i>Falco tinnunculus</i>)	10/16 (62.5%)	mainly mammals	migratory
		12/19 (63.2%)		
Strigidae	northern long-eared owl (<i>Asio otus</i>)	4/5 (80%)	mainly mammals	sedentary
	little owl (<i>Athene noctua</i>)	6/7 (85.7%)	generalist species	sedentary
	tawny owl (<i>Strix aluco</i>)	1/4 (25%)	mainly mammals	sedentary
		11/16 (68.7%)		

N. caninum infection was recorded in a young and in an adult common kestrel (*Falco tinnuculus*), both hospitalized for traumatic causes. The adult common kestrel (RAP56) was also co-infected by *T. gondii*.

Statistical analysis by Chi-Square test did not show any differences in the prevalence values of *T. gondii* infection among the considered categories (taxonomic family, age, WRC, reason for admission to the WRC, dietary habits, and main migratory behavior) (Table 2).

Since only two animals tested positive on molecular analysis, it was not possible to establish an association of *N. caninum* infection with the considered risk factors.

For each animal included in the study, individual data and results of molecular analysis are detailed in Supplementary Table S

Table 2. Variables associated to *Toxoplasma gondii* infection in raptors from two Wildlife Recovery Centers (WRC) in Northern Italy.

Variable	Category	<i>T. gondii</i> B1 Real-Time PCR Positive/Examined (%)	<i>p</i> -Value ^a
Taxonomic family	Accipitridae	12/21 (57.1%)	0.768
	Falconidae	12/19 (63.2%)	
	Strigidae	11/16 (68.8%)	
Age	young	7/12 (58.3%)	0.737
	adult	28/44 (63.6%)	
WRC	WRC1	15/29 (51.7%)	0.084
	WRC2	20/27 (74.1%)	
Reason for admission to the WRC	debilitation	4/5 (80%)	0.697
	trauma	25/41 (61%)	
	other causes	6/10 (60%)	
Dietary habits	mainly mammals	25/36 (69.4%)	0.318
	mainly bird	5/11 (45.5%)	
	generalist species	5/9 (55.6%)	
Migratory behavior	migratory	10/19 (52.6%)	0.274
	sedentary	25/37 (67.6%)	

^a Pearson's Chi-Square test.

4. Discussion

The results obtained in the present study demonstrated the presence of *T. gondii* and *N. caninum* in wild birds of prey admitted to WRCs, with the detection of the DNA of the two pathogens in 62.5% and 3.6% of the analyzed brain tissue samples, respectively. Due to the difficulties in carrying out this study in nature, WRC were chosen to carry out the sampling, as in other studies [6–8,25]. The possible bias related to the health status at the time of admission to the WRC was investigated and discussed below.

In the present study, a high prevalence of *T. gondii* infection was recorded, particularly in the species belonging to the Strigidae family (68.8%), followed by those belonging to the Falconidae (63.2%) and Accipitridae (57.1%) families. The prevalence was even higher considering the single host species, such as the Eurasian buzzard and the little owl (90% and 85.7%, respectively); possibly, ecology-related variables explain the inter-specific differences. However, the statistical analysis did not show significant associations between the prevalence data obtained and the considered variables, demonstrating the wide spread of the infection among the study population.

In the literature, several studies investigated the presence of this parasite in raptors, either through serological investigations or by using molecular techniques. Previous seroepidemiological studies conducted in Europe showed heterogeneous seroprevalence values: 29.8% in Spain, 36% in France, and 54% in Portugal of the raptors included in the sampling showed specific anti-*T. gondii* antibodies [7,8,25]. These differences might be due both to the lack of standardization of the serological techniques used in terms of tests and cut-off [4], but also due to the diverse host species included in the studies. Considering the Italian scenario, a recent seroepidemiological study conducted in the same study area of the present study found a *T. gondii* seroprevalence of 13.2% among wild birds of prey admitted to a WRC [6]. In addition, a similar seroprevalence value (26.1%) was recorded among the 238 kestrels captured-and-released at an airport site in the Emilia Romagna region (Northern Italy) [26]. A mismatch between the serological result reported by these two studies and the data obtained from the present molecular epidemiology study is therefore highlighted. In wild birds of prey, however, seroprevalence does not always correspond to positivity to the PCR on the brain [10], demonstrating that the association between seropositivity and the presence of *T. gondii* DNA in the tissues of these species is yet to be investigated. As evidence of the possible lifelong non-persistence of immunity, in the present study, no difference in the prevalence values was recorded between young and adult animals, as already reported in other wild species [27].

Considering molecular epidemiology, differences were reported among the available studies. Darwich et al. [9], by means of a nested PCR targeting the 529 bp repetitive fragment, found *T. gondii* DNA in the brain of only two positive raptors among the 136 examined in Spain. Nardoni et al. [10], using a nested PCR targeting the B1 gene, found

T. gondii DNA in the brain and heart samples belonging to two positive *Falco tinnunculus*, among 15 raptors examined in Central Italy. A higher prevalence value was recorded by a recent study conducted in Turkey: *T. gondii* DNA was detected by Real Time PCR targeting the 529 bp repetitive fragment in the brain and heart samples of 92.3% out of 43 examined raptors [28]. These differences in prevalence values might be explained both by the sensitivity of the different molecular techniques, and the target genes use. In the present study, a Real Time PCR, generally having a higher sensitivity compared to end-point PCR, was used as screening and for targeting the B1 gene, which is present in multiple copies within the *T. gondii* genome, and is among the most widely used genes in molecular screening [22]. On the contrary, the PCR conducted in the genes used for genotyping, present in a single copy of the *T. gondii* genome, might be less sensitive. As in the present study, this often results in fewer genotyped samples than those tested positive in the screening PCR [28,29]. Furthermore, the molecular epidemiology studies conducted on avian species usually include various species of wild raptors, which, due to their different ethological behaviors, could be exposed to a different degree of risk of acquiring *T. gondii* infection. In fact, strict carnivorous or scavenger species are more at risk than generalist species [8]. Although there is a slightly higher prevalence of infection in species that normally feed on micro-mammals compared to species that prey on other birds or generalist species, since the difference is not statistically significant, the results obtained do not suggest that the dietary habits represents a risk factor for *T. gondii* infection for birds of prey. Generally, raptors as apex predators might be considered indicators of the spread of infection in the environment and in other animal species that share the same habitats and trophic chains.

Indeed, the presence of *T. gondii* in the study area was previously extensively reported with the detection of specific antibodies or parasitic DNA in different domestic [30–32] and wild host species [20,27], demonstrating the presence of both a domestic and a sylvatic cycle in this area. The animals admitted to the WCR are usually individuals living near urban centers; for this reason, they are more frequently subject to anthropogenic trauma (e.g., impact with windows and cars), and more easily identifiable and referable to WRCs. All birds included in the study were admitted to WCRs, but then died or were euthanized as a result of various pathologies. Interestingly, even if this data were not statistically significant, a higher prevalence of *T. gondii* was detected in birds of prey admitted to a WCR due to their debilitation than in those hospitalized for other causes, suggesting an involvement of *T. gondii* in the deterioration of the general conditions of the animals up to the fatal outcome. Although few cases of clinical toxoplasmosis are reported in raptor species [11–13], this finding could suggest to veterinarians operating in WCRs to include toxoplasmosis in the differential diagnosis, especially in the case of debilitated birds of prey.

Given the high environmental contamination by *T. gondii* oocysts in densely populated areas [33], the finding of the infection in sedentary raptor species might be indicative of the prevalence of the parasite in the area where they live. On the contrary, long-range migratory species, could be used as indicators of *T. gondii* genetic variability on their migration route or in the country of destination, as they could acquire the infection during their migration. Consequently, an expected result could be a certain degree of difference between sedentary and migratory species, also with regard to the involved *T. gondii* genotypes. Karakavuk et al. [28] genotyped by microsatellite analysis a total of 14 strains, belonging to Type II (8 isolates), Type III (3 isolates), or atypical Types (3 isolates) in Turkey, a strategic area for the passage of migratory avian species. Indeed, a wide genetic variability is possible in

the sylvatic cycle, especially in migratory species. On the contrary, all isolates successfully sequenced in the present study showed homology of sequence with Type II. On the other hand, Type II is the genotype most frequently found in Europe, both in domestic animals and in synanthropic or wild animals, including wild

birds [34,35]. Interestingly, two SNPs were identified within the altSAG2 gene, which could represent an adaptation of the parasite to the raptor host species. However, further studies including more *T. gondii* isolates from raptors are needed to confirm this genetic trait of the parasite infecting raptors.

N. caninum in brain tissue of wild birds of prey was also investigated in this study. The presence of birds in farms as risk factors for neosporosis in cattle [36,37] suggests the involvement of avian species in the *N. caninum* cycle, even if the underlying biological mechanism and the epidemiological role of these species is still not fully elucidated.

Indeed, there are only few reports of natural *N. caninum* infections in domestic and wild birds, demonstrated both with the presence of specific antibodies and with the detection of the DNA of the parasite in the tissues of the hosts, as recently reviewed [5]. Considering in particular the birds of prey, attempts of experimental *N. caninum* infection have failed [38], while to the best of our knowledge the parasite DNA was previously demonstrated only in the brain tissue of a naturally infected buzzard [9]. In our study,

N. caninum DNA was found in the brain of two common kestrels, one young and one adult animal, the second was also co-infected with *T. gondii*. These data, therefore, add a new species among the naturally intermediate hosts that can therefore acquire *N. caninum* infection. It is plausible that the two kestrels, preying mainly on micro-mammals, acquired the infection by ingesting infected small rodents. Micro-mammal species, such as house mice (*Mus musculus*) and field mice (*Apodemus sylvaticus*), are in fact among the suitable intermediate host species of both *T. gondii* and *N. caninum* [39,40], potentially representing the link between the sylvatic cycle, to which the birds of prey belong, and the domestic cycle involving dogs and cattle.

It is noteworthy to consider that in the study area, *N. caninum* is highly prevalent both in dairy cattle farms where it is recognized as an important cause of abortion [21], and in small ruminants [41]. Recent studies conducted on aborted bovine fetuses identified local

N. caninum subpopulations in Northern Italian regions [42], and a significant association between the geographic distance of the farms and the genetic distance determined by multilocus-microsatellite genotyping was evidenced [21]. Therefore, multilocus microsatellite genotyping of *N. caninum* from other intermediate hosts, including wild birds, could be indicative of the spatial distribution and mutual connections between the parasite isolates from different species.

5. Conclusions

In conclusion, data obtained in the present study confirmed raptors as natural hosts of *T. gondii* and endorsed *F. tinnunculus* as a suitable intermediate host species for *N. caninum*, confirming the potential role of these animals in the sylvatic and potentially also in the domestic life cycle of these pathogens. Further studies of molecular epidemiology, as well as the isolation of pathogens, are necessary for understanding the actual role of birds of prey in the sylvatic cycle and, generally, in the epidemiology of *T. gondii* and *N. caninum*. Many species of birds of prey, such as kestrels, buzzards, nocturnal birds of prey, share large portions of their habitat with humans, and are showing an increasing trend towards urbanization in response to the expansion of the territory occupied by humans. Their position at the top of trophic chains, and their stable presence in urbanized areas, makes them ideal sentinel species for the circulation of *T. gondii*, a zoonotic parasite, and of *N. caninum*, impacting livestock production. The fundamental role of WRCs in the epidemiological surveillance of wildlife is therefore confirmed.

Supplementary Materials: The following are available online at <https://www.mdpi.com/article/10.3390/microorganisms9040736/s1>. Table S1: Alignment of GRA6, Table S2: Alignment of BTUB, Table S3: Alignment of altSAG2, and Table S4: Individual data and results of molecular analysis.

Author Contributions: Conceptualization, A.L.G.; methodology, A.L.G.; investigation, A.L.G., L.V. and S.R. (Sara Ressegotti); resources, E.L., G.G., S.R. (Stefano Raimondi); writing—original draft preparation, A.L.G.; writing—review and editing, A.L.G., L.V., S.A.Z., G.G., and M.T.M. All authors have read and agreed to the published version of the manuscript.

Funding: This research received no external funding.

Institutional Review Board Statement: The study was conducted according to the guidelines of the Declaration of Helsinki, and approved by the Institutional Animal Care and Use Committee of Università degli Studi di Milano (“Organismo Preposto al Benessere degli Animali,” Prot. no. OPBA_34_2017).

Informed Consent Statement: Not applicable.

Data Availability Statement: Data supporting the conclusions of this article are included within the article and its Supplementary Materials.

Conflicts of Interest: The authors declare no conflict of interest.

References

1. Dubey, J.P.; Hemphill, A.; Calero-Bernal, R.; Schares, G. *Neosporosis in Animals*; Apple Academic Press: Waretown, NJ, USA, 2017; p. 548.
2. Dubey, J.P. *Toxoplasmosis of Animals and Humans*; Apple Academic Press: Waretown, NJ, USA, 2016; p. 313.
3. Donahoe, S.L.; Lindsay, S.A.; Krockenberger, M.; Phalen, D.; Šlapeta, J. A review of neosporosis and pathologic findings of *Neospora caninum* infection in wildlife. *Int. J. Parasitol. Parasites Wildl.* **2015**, *4*, 216–238.
4. Dubey, J.P.; Murata, F.H.A.; Cerqueira-Cézar, C.K.; Kwok, O.C.H.; Su, C. Epidemiologic significance of *Toxoplasma gondii* infections in turkeys, ducks, ratites and other wild birds: 2009–2020. *Parasitology* **2021**, *148*, 1–30.
5. De Barros, L.D.; Miura, A.C.; Minutti, A.F.; Vidotto, O.; Garcia, J.L. *Neospora caninum* in birds: A review. *Parasitol. Int.* **2018**, *67*, 397–402.
6. Gazzonis, A.L.; Zanzani, S.A.; Santoro, A.; Veronesi, F.; Olivieri, E.; Villa, L.; Lubian, E.; Lovati, S.; Bottura, F.; Epis, S.; et al. *Toxoplasma gondii* infection in raptors from Italy: Seroepidemiology and risk factors analysis. *Comp. Immunol. Microbiol. Infect. Dis.* **2018**, *60*, 42–45.
7. Aubert, D.; Terrier, M.-E.; Dumètre, A.; Barrat, J.; Villena, I. Prevalence of *Toxoplasma gondii* in Raptors from France. *J. Wildl. Dis.* **2008**, *44*, 172–173.
8. Cabezón, O.; García-Bocanegra, I.; Molina-López, R.; Marco, I.; Blanco, J.M.; Höfle, U.; Margalida, A.; Bach-Raich, E.; Darwich, L.; Echeverría, I.; et al. Seropositivity and Risk Factors Associated with *Toxoplasma gondii* Infection in Wild Birds from Spain. *PLoS ONE* **2011**, *6*, e29549.
9. Darwich, L.; Cabezón, O.; Echeverría, I.; Pabón, M.; Marco, I.; Molina-López, R.; Alarcia-Alejos, O.; López-Gatius, F.; Lavín, S.; Almería, S. Presence of *Toxoplasma gondii* and *Neospora caninum* DNA in the brain of wild birds. *Veter Parasitol.* **2012**, *183*, 377–381.
10. Nardoni, S.; Rocchigiani, G.; Varvaro, I.; Altomonte, I.; Ceccherelli, R.; Mancianti, F. Serological and molecular investigation on *Toxoplasma gondii* infection in wild birds. *Pathogens* **2019**, *8*, 58.
11. Mikaelian, I.; Dubey, J.P.; Martineau, D. Severe Hepatitis Resulting from Toxoplasmosis in a Barred Owl (*Strix varia*) from Quebec, Canada. *Avian Dis.* **1997**, *41*, 738–740.
12. Szabo, K.A.; Mense, M.G.; Lipscomb, T.P.; Felix, K.J.; Dubey, J.P. Fatal Toxoplasmosis in a Bald Eagle (*Haliaeetus leucocephalus*). *J. Parasitol.* **2004**, *90*, 907–908.
13. Bourque, L.; Greenwood, S.J.; Jones, M.E.B. Acute toxoplasmosis and pox-viral dermatitis in a juvenile bald eagle (*Haliaeetus leucocephalus*) in New Brunswick, Canada. *Can. Vet. J.* **2020**, *61*, 880–884.
14. Gerhold, R.W.; Saraf, P.; Chapman, A.; Zou, X.; Hickling, G.; Stiver, W.H.; Houston, A.; Souza, M.; Su, C. *Toxoplasma gondii* seroprevalence and genotype diversity in select wildlife species from the southeastern United States. *Parasites Vectors* **2017**, *10*, 508.
15. Bildstein, K.L. *Migrating Raptors of the World: Their Ecology and Conservation*; Cornell University Press: Ithaca, NY, USA, 2006; p. 336.

16. Svensson, L.; Mullarney, K.; Zetterström, D.; Grant, P.J. *Collins Bird Guide: The Most Complete Guide to the Birds of Britain and Europe*; Harper Collins: New York, NY, USA, 2009.
17. Burg, J.L.; Grover, C.M.; Pouletty, P.; Boothroyd, J.C. Direct and sensitive detection of a pathogenic protozoan, *Toxoplasma gondii*, by polymerase chain reaction. *J. Clin. Microbiol.* **1989**, *27*, 1787–1792.
18. Gazzonis, A.L.; Marangi, M.; Villa, L.; Ragona, M.E.; Olivieri, E.; Zanzani, S.A.; Giangaspero, A.; Manfredi, M.T. *Toxoplasma gondii* infection and biosecurity levels in fattening pigs and sows: Serological and molecular epidemiology in the intensive pig industry (Lombardy, Northern Italy). *Parasitol. Res.* **2018**, *117*, 539–546.
19. Collantes-Fernandez, E.; Zaballos, A.; Alvarez-Garcia, G.; Ortega-Mora, L.M. Quantitative Detection of *Neospora caninum* in Bovine Aborted Fetuses and Experimentally Infected Mice by Real-Time PCR. *J. Clin. Microbiol.* **2002**, *40*, 1194–1198.
20. Zanzani, S.A.; Di Cerbo, A.; Gazzonis, A.L.; Epis, S.; Invernizzi, A.; Tagliabue, S.; Manfredi, M.T. Parasitic and Bacterial Infections of *Myocastor coypus* in a Metropolitan Area of Northwestern Italy. *J. Wildl. Dis.* **2016**, *52*, 126–130.
21. Villa, L.; Maksimov, P.; Luttermann, C.; Tuschy, M.; Gazzonis, A.L.; Zanzani, S.A.; Mortarino, M.; Conraths, F.J.; Manfredi, M.T.; Schares, G. Spatial distance between sites of sampling associated with genetic variation among *Neospora caninum* in aborted bovine fetuses from northern Italy. *Parasites Vectors* **2021**, *14*, 1–14.
22. Su, C.; Shwab, E.K.; Zhou, P.; Zhu, X.Q.; Dubey, J.P. Moving towards an integrated approach to molecular detection and identification of *Toxoplasma Gondii*. *Parasitol.* **2009**, *137*, 1–11.
23. Tamura, K.; Stecher, G.; Peterson, D.; Filipski, A.; Kumar, S. MEGA6: Molecular evolutionary genetics analysis version 6.0. *Mol. Biol. Evol.* **2013**, *30*, 2725–2729.
24. Bush, A.O.; Lafferty, K.D.; Lotz, J.M.; Shostak, A.W. Parasitology Meets Ecology on Its Own Terms: Margolis et al. Revisited. *J. Parasitol.* **1997**, *83*, 575–583.
25. Lopes, A.P.; Sargo, R.; Rodrigues, M.; Cardoso, L. High seroprevalence of antibodies to *Toxoplasma gondii* in wild animals from Portugal. *Parasitol. Res.* **2010**, *108*, 1163–1169.
26. Iemmi, T.; Vismarra, A.; Mangia, C.; Zanin, R.; Genchi, M.; Lanfranchi, P.; Kramer, L.H.; Formenti, N.; Ferrari, N. *Toxoplasma gondii* in the Eurasian kestrel (*Falco tinnunculus*) in northern Italy. *Parasites Vectors* **2020**, *13*, 1–7.
27. Gazzonis, A.L.; Villa, L.; Riehn, K.; Hamedy, A.; Minazzi, S.; Olivieri, E.; Zanzani, S.A.; Manfredi, M.T. Occurrence of selected zoonotic food-borne parasites and first molecular identification of *Alaria alata* in wild boars (*Sus scrofa*) in Italy. *Parasitol. Res.* **2018**, *117*, 2207–2215.
28. Karakavuk, M.; Aldemir, D.; Mercier, A.; Atalay S, ahar, E.; Can, H.; Murat, J.B.; Döndüren, Ö.; Can, S, .; Özdemir, H.G.; Deg` ırmenci Döş,kaya, A.; et al. Prevalence of toxoplasmosis and genetic characterization of *Toxoplasma gondii* strains isolated in wild birds of prey and their relation with previously isolated strains from Turkey. *PLoS ONE* **2018**, *13*, e0196159.
29. Fernández-Escobar, M.; Calero-Bernal, R.; Benavides, J.; Regidor-Cerrillo, J.; Guerrero-Molina, M.C.; Gutiérrez-Expósito, D.; Collantes-Fernández, E.; Ortega-Mora, L.M. Isolation and genetic characterization of *Toxoplasma gondii* in Spanish sheep flocks. *Parasit. Vectors* **2020**, *13*, 396.
30. Villa, L.; Gazzonis, A.L.; Álvarez-García, G.; Diezma-Díaz, C.; Zanzani, S.A.; Manfredi, M.T. First detection of anti- *Besnoitia* spp. specific antibodies in horses and donkeys in Italy. *Parasitol. Int.* **2018**, *67*, 640–643.
31. Gazzonis, A.L.; Zanzani, S.A.; Villa, L.; Manfredi, M.T. *Toxoplasma gondii* infection in meat-producing small ruminants: Meat juice serology and genotyping. *Parasitol. Int.* **2020**, *76*, 102060.
32. Gazzonis, A.L.; Marino, A.M.F.; Garippa, G.; Rossi, L.; Mignone, W.; Dini, V.; Giunta, R.P.; Luini, M.; Villa, L.; Zanzani, S.A.; et al. *Toxoplasma gondii* seroprevalence in beef cattle raised in Italy: A multicenter study. *Parasitol. Res.* **2020**, *119*, 3893–3898.

33. Afonso, E.; Lemoine, M.; Poulle, M.L.; Ravat, M.C.; Romand, S.; Thulliez, P.; Villena, I.; Aubert, D.; Rabilloud, M.; Riche, B.; et al. Spatial distribution of soil contamination by *Toxoplasma gondii* in relation to cat defecation behaviour in an ur-ban area. *Int. J. Parasitol.* **2008**, *38*, 1017–1023.
34. Aubert, D.; Ajzenberg, D.; Richomme, C.; Gilot-Fromont, E.; Terrier, M.; de Gevigney, C.; Game, Y.; Maillard, D.; Gibert, P.; Dardé, M.; et al. Molecular and biological characteristics of *Toxoplasma gondii* isolates from wildlife in France. *Veter Parasitol.* **2010**, *171*, 346–349.
35. Calero-Bernal, R.; Saugar, J.M.; Frontera, E.; Pérez-Martín, J.E.; Habela, M.A.; Serrano, F.J.; Reina, D.; Fuentes, I. Prevalence and genotype identification of *Toxoplasma gondii* in wild animals from southwestern Spain. *J. Wildl. Dis.* **2015**, *51*, 233–238.
36. Bartels, C.; Wouda, W.; Schukken, Y. Risk factors for *Neospora caninum*-associated abortion storms in dairy herds in The Netherlands (1995 to 1997). *Theriogenology* **1999**, *52*, 247–257.
37. Otranto, D.; Llazari, A.; Testini, G.; Traversa, D.; Di Regalbono, A.F.; Badan, M.; Capelli, G. Seroprevalence and associated risk factors of neosporosis in beef and dairy cattle in Italy. *Vet. Parasitol.* **2003**, *118*, 7–18.
38. Baker, D.G.; Morishita, T.Y.; Brooks, D.L.; Shen, S.K.; Lindsay, D.S.; Dubey, J.P. Experimental Oral Inoculations in Birds to Evaluate Potential Definitive Hosts of *Neospora caninum*. *J. Parasitol.* **1995**, *81*, 783.
39. Ferroglio, E.; Pasino, M.; Romano, A.; Grande, D.; Pregel, P.; Trisciuglio, A. Evidence of *Neospora caninum* DNA in wild rodents. *Veter Parasitol.* **2007**, *148*, 346–349.
40. Machac'ová, T.; Ajzenberg, D.; Žáková, A.; Sedlák, K.; Bártová, E. *Toxoplasma gondii* and *Neospora caninum* in wild small mammals: Seroprevalence, DNA detection and genotyping. *Vet. Parasitol.* **2016**, *223*, 88–90.
41. Gazzonis, A.; Villa, L.; Manfredi, M.; Zanzani, S. Spatial Analysis of Infections by *Toxoplasma gondii* and *Neospora caninum* (Protozoa: Apicomplexa) in Small Ruminants in Northern Italy. *Animals* **2019**, *9*, 916.
42. Regidor-Cerrillo, J.; Horcajo, P.; Ceglie, L.; Schiavon, E.; Ortega-Mora, L.M.; Natale, A. Genetic characterization of *Neospora caninum* from Northern Italian cattle reveals high diversity in European *N. caninum* populations. *Parasitol. Res.* **2020**, *119*, 1353–1362.